

Morphometrical, Histopathological, and Cytogenetical ameliorating Effects of Green tea Extract on Nicotine Toxicity of the Testis of Rats

^{1*}Azza M. Gawish, ²Aliaa M. Issa, ³Aziza M. A., and Sherin Ramadan

¹Department of Zoology, Faculty of Science, Cairo University, Cairo, Egypt

²Cell biology Department, National Research Centre, Dokki, Cairo, Egypt

³National Organization for Drug control and Research Dokki – Giza, Cairo, Egypt

*azzagawish@gmail.com

Abstract: Nicotine is a major toxic component of cigarette smoke and it is a major risk factor in the development of functional disorder of several organ systems. The natural diet contains a variety of compounds that exhibit protective effects towards different toxicities of nicotine as green tea. Four groups of male Swiss albino mice were divided: untreated control group; Nicotine-treated group (2.5 mg/kg/day); Green tea-treated group (40 mg/kg./day); and Nicotine and green tea treated group interperitoneal administration for successive 28 days. Results showed that disorganization of the seminiferous tubules associated with reduction of spermatogenic cells, leading to widening of lumen of tubules upon nicotine toxicity. Many of seminiferous tubules exhibited degenerative phases of spermatocytes and spermatides as well as missing of sperms and hypo-spermatogenesis. The recorded data in nicotine intoxicated group showed significant and gradual decrease of number of leydig cells throughout all intervals of experiment. In the last, cytogenetically examination demonstrated significant increased in the number of nucleated polychromatic erythrocytes (MnPCE) and decreased in number of polychromatic erythrocytes (PCE) in bone marrow of nicotine-treated animals using micronucleus assay. Green tea treatment reduced number of nucleated polychromatic erythrocytes (MnPCE) and restored number of polychromatic erythrocytes (PCE) to nearly normal. In conclusions, intake of green tea might suppress the toxicity and mutagenic activity of nicotine.

[Azza M. Gawish, Aliaa M. Issa, Aziza M. A., and Sherin Ramadan. Morphometrical, Histopathological, and Cytogenetical ameliorating Effects of Green tea Extract on Nicotine Toxicity of the Testis of Rats. *Journal of American Science* 2010;6(11):401-411]. (ISSN: 1545-1003).

Keywords: Smoking - Nicotine – Fertility – Antioxidants – Green tea

1. Introduction:

Smoking has enormous negative health consequences worldwide. Nicotine is a naturally occurring alkaloid found in tobacco plant (*Nicotiana tabacum*) and it is the major constituent of tobacco responsible for the compulsive use of tobacco (Wu *et al.*, 2002). Nicotine and its metabolites are also being investigated and researched for the treatment of a number of disorders as Alzheimer's diseases (Hecht, 2003). Okamoto *et al.*, (1994) recorded the LD₅₀ of nicotine as (50 mg/kg) for rats and (3 mg/kg) for mice.

Nicotine administration induces changes in gonadal functions and deficiency in sperm maturation and spermatogenesis and has a detrimental effect on the sperm-fertilizing potential of male rats (Reddy *et al.*, 1998 and Yamamoto *et al.*, 1998). Also nicotine was reported to have toxic effects on gonadal functions in males in addition to its role in the lowering testosterone and estradiol levels in the serum (Kavitharaj *et al.*, 1999). Nicotine has been associated with decrease in number of germ cells, germinal cells and increased

chromosomal abnormalities in sperm and with increased the risks of birth defects and neonatal death and genetic mutations in sperm, reduced sperm fertilizing capacity and decreased embryonic implantation rates (Polyzos *et al.*, 2009). Nicotine has a deleterious effect of nicotine on sperm membrane intactness and DNA and apoptosis in mouse leydig cells treated with nicotine were recorded by (Arabi, 2004 and Kim *et al.*, 2005). From human studies; nicotine smoke contains harmful mutagens and carcinogens metabolites; that may induce defective semen quality, nuclear DNA damage of spermatozoa (Arif *et al.*, 2000, De Flora *et al.*, 2003 and Elshal *et al.*, 2009).

Nicotine had been shown to increase the frequency of micronuclei in human gingival fibroblasts and induce DNA strand breaks in human spermatozoa (Arabi *et al.*, 2004). Information on the *in vivo* genotoxicity of nicotine have shown that nicotine induces aneuploidy and polyploidy (Bishun *et al.*, 1972), sister chromatid exchange and chromosome aberrations in bone-marrow cells of mice (Sen *et al.*, 1991). High doses of nicotine

increase the frequencies of premature centromere separation and premature anaphase and reduce the number of oocytes ovulated; however, the results of this study suggested that nicotine does not elevate aneuploidy levels in mouse oocytes (Mailhes *et al.*, 2000). The increased generation of ROS can produce a condition of oxidative stress that can result in the oxidation of lipids, induction of DNA single-strand breakage, inactivation of certain proteins, and disruption of biological membranes (Durak *et al.*, 2002). Increased oxidative stress has been suggested to play a major role in the pathogenesis of several smoking-related diseases such as cancer, cardiovascular and oral diseases (Reibel, 2003 and Sudheer *et al.*, 2007)

Natural antioxidants as polyphenols of green tea extracts have received much attention for treatments of oxidative-stress-related pathological conditions (Park *et al.*, 1998 and Yokozawa *et al.*, 2004). Green tea can suppress the DNA adduction, and hence act as inhibitors of cancer and it is a rich source of polyphenols, which are antioxidants in natural and their ameliorating effect on genital organs were recorded (Ogura *et al.*, 2008). Study on acute effect of green tea extract and its polyphenols constituents, *in vitro* showed stimulated testosterone production by rat Leydig cells and reduced the testicular tissue content of total cholesterol (TC), triglycerides (TG), phospholipids (Fabiano *et al.*, 2009).

Tea polyphenol could inhibit the mutagenicity of chemical mutagens and chromosome aberrations (Shim *et al.*, 1995). The frequencies of sister-chromatid exchange (SCE) in peripheral lymphocytes were study were significantly higher among smokers who were non tea drinkers, than those of non-smokers and smokers who consumed green tea at least two to three cups per day during the past 6 months (Lee *et al.*, 1997). It is possible that consuming high levels of green tea over a long period may reduce the DNA damage caused by tobacco smoking (Liang *et al.*, 2007). Our aim of work is the evaluation of the role of green tea in the protection from the effects of cigarette smoking.

2. Materials and methods

1-Experimental animals:

The experimental animals used in this study were male Swiss albino mice. Eighty Male Swiss albino mice aged 9 – 12 weeks and weighing 25 -30 gm were used throughout the study. Animals were fed a commercially prepared diet and had free access to tap water. All mice were kept under the same experimental condition, feeding standard diet, and water was available *Adlibitum*.

After one-week acclimatization period, the selected animals of nearly a similar weight were divided into 4 experimental groups so as to keep more or less the same mean body weight within the individual groups. The selected animal groups treated as follows:

1-Nicotine – Treated group: Each mouse in this group was given intraperitoneally (i.p.) dose of 3 nicotine 2.5mg/ kg / day for successive 28 days.

2-Green Tea – Treated group: For successive 28 days each mouse in this group was injected i.p. with freshly prepared green tea extract (40 mg / kg body weight / day).

3-Nicotine-Green Tea -Treated group: Each animal in this group was given i.p. of nicotine (2.5mg/kg/day) at the same dose as group1 concomitantly with green tea extract (40 mg / kg body weight) at the dose as second group for successive 28 days.

4-Control -Treated group: Each animal in this group was injected i.p. with distilled water (1ml/ day) for successive 28 days and handling on the same conditions exactly similar to that of the previously mentioned groups.

II-Chemicals:

The treated elements in the experiment were nicotine ((*S*)-3-(1-Methyl-2-pyrroli- danyl) pyridine) and green tea extract. Nicotine was supplied as colorless liquid, obtained from faculty of pharmacy, Cairo University, Egypt. The mean LD₅₀ for intraperitoneal administration of nicotine to 8-week-old mice was reported as 12.5 mg (Favaro *et al.*, 2003). Green tea extract was supplied in form of tablets obtained from Technomad Groups Company, Egypt, they were soluble in water.

III- Experimental design:

Five mice from each group were sacrificed by cervical dislocation at end of 1, 2, 3, and 4 weeks (7th, 14th, 21th, 28th days) of the experimental period and decapitation, two femurs are removed and stripped clean of muscle for cytogenetically examination. Also, lung, liver and testes were also sampled and kept in aqueous Bouin for histological, histochemical and morphometric examinations.

Experimental analysis:

1--Histopathological examination:

For histopathology and morphometric evaluation, testes of all groups were collected deception and fast dissection. They were fixed in aqueous Bouin solution, dehydrated through alcohols, cleared in xylene and then embedded in paraffin wax. According to the method described by

Bancroft and Stevens, (2002). 5 μ thickness paraffin sections were prepared and mount on clean slides. For histopathological study sections were stained with Ehrlich's haemotoxylin and counterstained with eosin. A number of photomicrographs were taken at known magnification.

2-Image analysis:

The data were obtained using Leica Qwin 500 image analyzer computer system (England). The image analyzer consisted of a colored video camera, colored monitor, hard disc of IBM personal computer connected to the microscope, and controlled by Leica Qwin 500 software. The image analyzer was first calibrated automatically to convert the measurement units (pixels) produced by the image analyzer program into actual micrometer units. These measurements were done using an objective lens of magnification 40, i.e. of total magnification 400. Ten readings were obtained in each specimen. Regarding the no of Leydig cells using an objective lens of magnification 40, i. e of total magnification 400, they were counted using interactive measurement in 10 fields in each specimen. The data obtained were subjected to statistical analysis using Duncan's Test and ONE WAY ANOVA.

3- Micronucleus assay

The most attractive features of the micronucleus assay are rapidly and easily with which in vivo genetic activity can be demonstrated. The first test to be developed and the most commonly used is carried out in mouse bone marrow by scoring micronuclei polychromatic erythrocytes (Heddle, 1973). In this study the micronucleus polychromatic erythrocyte were prepared according to an improved method adopted by (Salamone *et al.*, 1980).

a. Harvesting Marrow.

Animals are killed by cervical dislocation, and two femurs are removed and stripped clean of muscle. The marrow is removed by making a small opening at the iliac end of the femur and introducing the pointed shaft of a 2.5-cm safety pin into the femur at the epiphysial end. As the pin is slowly pushed and twisted into the marrow canal, the marrow exudes out the hole at the iliac end. The marrow is placed directly on a slide, and then a drop of fetal calf serum is added. With the aid of the edge of a clean slide, the marrow is mixed with the serum until homogeneous and then is spread as a smear; additional slides from a given animal can be prepared by simply transferring some of the mixed preparation onto other slides. Prepared slides are air-dried, fixed for 5 min in absolute methanol.

b- Slide Staining:

After air-drying, the smear were stained for 20 min in May-Grunwald stain in conjunction with the Gimsa stain (May-Grunwald/Gimsa (Schmid, 1975)) , this combination consisted of: 3 ml Gimsa (stock), 12 ml May-Grunwald (0.25gm MayGrunwald/100ml methanol), 2 ml 0.1M Na₂Hpo₄, -4.5 ml 0.1M KH₂po₄, and 51 ml D. Stain was freshly prepared and mixing well before used After the staining, the slides were washed thoroughly in distal water and left to dry overnight. All glass slides were coded before observation. Examination under oil lence.

c- Scoring

1000 polychromatic erythrocytes (PCEs) were scored per animal and the numbers of micronucleated PCEs were recorded. The results were expressed as the average number of micronucleated PCEs / 1000 PCEs. For each sampling time, bone marrow smears from five animals per four / group were used for evaluation. From each animal, 1000 polychromatic erythrocytes (PCE) were scored under the microscope (1000-1250x; Optech, Germany) for the incidence of micronucleated polychromatic erythrocytes (MnPCEs). In addition, the number of PCEs among 1000 total erythrocytes (PCE + NCE) per animal was recorded to evaluate bone marrow cytotoxicity. The ratio of polychromatic to normochromatic erythrocytes (PCE / NCE) was calculated, based on 1000 erythrocytes (PCE / NCE) scored per slide. These ratios were used as a measure of toxicity of test materials.

IV- Statistical analysis:

Statistical analyses were carried out using analysis of variance, Duncan's Test and One Way ANOVA (Senedecor and Cochran, 1980). To evaluate the effect in between groups and give a change for multiple comparison in between.

3. Results:

1-Histopathological results:

The control untreated male mice testes tissues showed an outer capsule of fibroblastic connective tissue bound normal seminiferous tubules microscopy (Fig 1).

Testis of Swiss albino mice due to interperitoneal and daily injected nicotine treatment at the dose level 2.5mg/kg showed more or less normal testis architecture with complete spermatogenesis and focal decreased in population of leydig cells at the first week of nicotine treatment (Fig2). Along three weeks of nicotine treatment, some seminiferous tubules shows disorganization and atrophy of

seminiferous tubules with widening of its lumen and reduction in sperm count. Other seminiferous tubules had arrest in spermatogenesis. Some spermatogenic cells showed apoptosis especially in 1ry and 2ry spermatocytes. Also, few vacuoles were appeared in some somniferous tubules. Leydig cells were more reduction compared with previous stages and control stage (Fig. 3). Compared with normal group, the animal treated with nicotine for four weeks revealed most of seminiferous tubules had reduction in more than one stage of spermatogenesis such as reduced in

number of spermatocytes and spermatid (marked arrest in spermatogenesis) and marked degeneration of the leydig cells and decrease in this cell population (Fig. 4). Histological examination of testis sections of mice treated with green tea at different interval of experimental showed normal architecture (Fig. 7), complete spermatogenesis and maturation of germinal epithelium. Also, animals treated with green tea exhibited normal appearance, regarding size and arrangement of the tubules (Fig8).

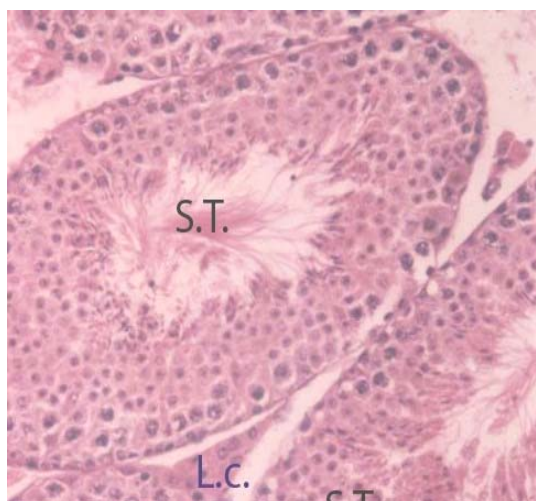


Fig (1): Micrograph of testis section of mice in control group showing normal architecture of seminiferous tubules (S.T.) .Atypical appearance of mice seminiferous tubules with different cellular association .The tubules had normal progression cells and Leydig cells have normal disruption (L.C.) (H&E., 200X)

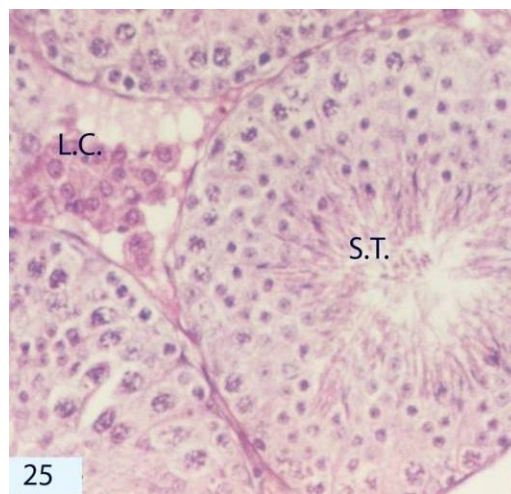


Fig (2): Micrograph of testis section treated with nicotine for a week showing complete spermatogenesis (S.T.) and nearly normal testis structure with lower decreased in population of Leydig cells (L.C.). (H&E., 400X)

2-Morphometric results:

Number of leydig cells in testis:

Table (1) and Figure (9) represent the variation in the number of leydig cells of testis due to nicotine intoxication and / or green tea protection. In normal group, all Swiss albino mice had normal distribution in nucleus area of liver and no significant changed presented along all interval of experimental.(23.40 ± 1.784 ; 23.70 ± 1.726 ; 23.90 ± 1.940 ; 24.60 ± 2.242). The recorded data in nicotine intoxicated group showed significant ($P < 0.05$) and gradual decrease of number of leydig cells throughout all intervals of treatment of experimental (18.10 ± 2.282), (15.30 ± 1.783), (12.40 ± 1.979) and (9.50 ± 1.462). As compared to control level, nicotine intoxicated group obtained insignificant ($P < 0.05$) decrease of number of leydig cells after first week of treatment (18.10 ± 2.282 vs., 23.40 ± 1.784) but the

value recorded being highly significant decreased till reached to minimal value at last week of experimental (15.30 ± 1.783 vs., 23.70 ± 1.726); (12.40 ± 1.979 vs., 23.90 ± 1.940); (9.50 ± 1.462 vs., 24.60 ± 2.242). Treatment with green tea prevented the decrease in number of leydig cells in nicotine treated mice with different degree and showed general increase in these cells. As compared to nicotine intoxicated group, the recorded data showed insignificant increased in number of leydig cells after first and second weeks of treatment With continues injection of green tea, till four weeks of experimental showed showed significant increased in number of leydig cells and highly significant ($P < 0.05$) increased at three and last week of experimental (19.50 ± 2.591 vs. 12.40 ± 1.979 and 21.60 ± 2.390 vs., 9.50 ± 1.462) were observed compared to control values.

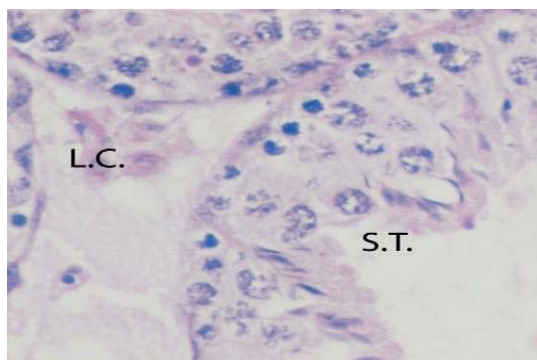


Fig (3): Micrograph of testis section treated with nicotine for three weeks showing apyknosis among spermatogenic cells especially necrosis in 1st & 2nd spermatocytes (thin arrow). (H&E., 400X)

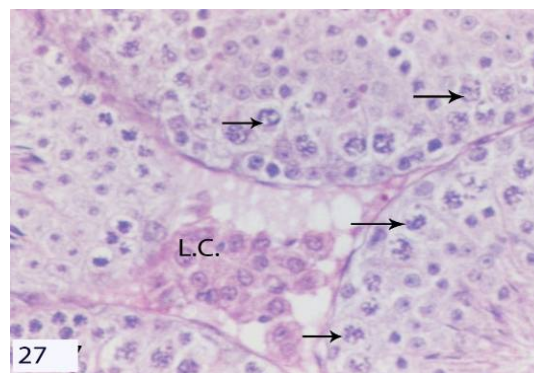


Fig (4): Micrograph of testis section treated with nicotine for four weeks showing different degree of damage of seminiferous tubules such as a disorder of systemic arrangement of the stages of spermatogenesis (S.T.) and few number of Leydig cells are appeared (L.C.). (H&E., 400X)

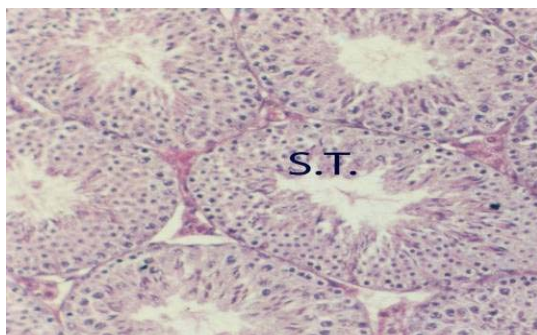


Fig (5): Micrograph of testis section treated with green tea concomitantly with nicotine for a week showing almost normal appearance of seminiferous tubules (S.T.) with normal spermatogenic cells and arrangement Leydig cells are more increased, (H&E., 200X)

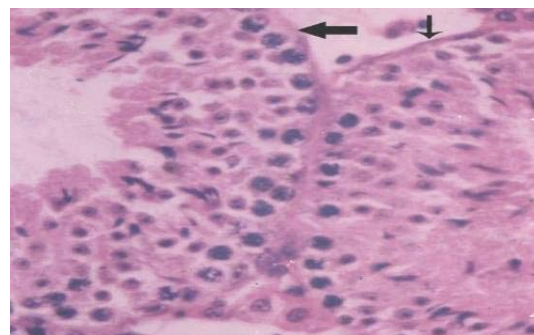


Fig (6): Micrograph of testis section treated with green tea concomitantly with nicotine for three weeks showing most of somniferous tubules

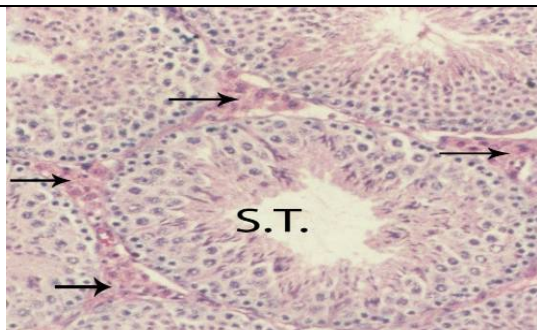


Fig (7): Micrograph of testis section treated with green tea concomitantly with nicotine for four weeks showing a little change in architecture of somniferous tubules with normal and order spermatogenesis (S.T.). (H&E, 400X)

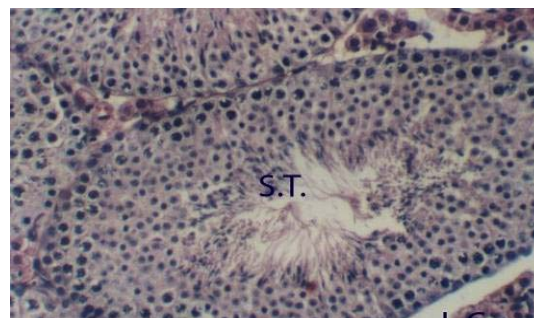


Fig (8): Micrograph of testis section treated with green tea showing a normal testis structure, complete spermatogenesis (S.T.) and normal appearance of Leydig cells (arrow). (H & E , 400 X).

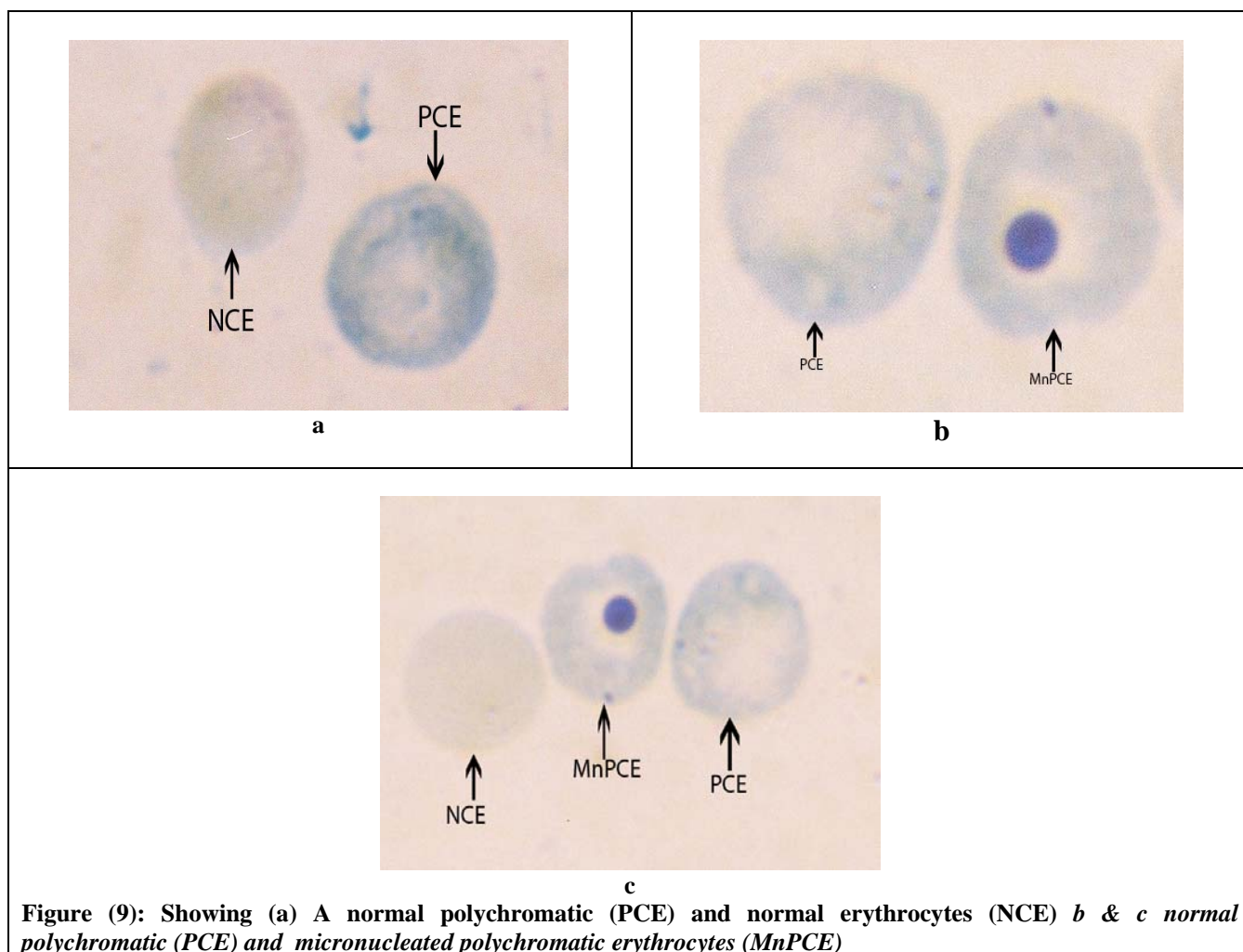


Figure (9): Showing (a) A normal polychromatic (PCE) and normal erythrocytes (NCE) b & c normal polychromatic (PCE) and micronucleated polychromatic erythrocytes (MnPCE)

Improvement and protective effect of green tea increased significant and gradually with increased time of administration on nicotine intoxicated group. Individual green tea injection to albino mice showed no significant difference in the number of Leydig cells throughout all the tested experimental period or over all intervals of experimental were attained compared to control level. In conclusion, green tea had obviously improved on nicotine toxicity and Leydig cells back to normal number in male albino mice. As well as, it is showed an amelioration and obviously improvement to the nicotine toxicity effect on area of nucleus in liver, elastic fiber and leydig cells of testis of male albino mice.

3-Cytogenetical Results:

The cytogenetic damage induced by intraperitoneal injection of nicotine at ($1/5$ LD₅₀ = 0.6 mg /kg to mice) as well as the antimutagenic effects of green tea at (40 mg /kg) treated

intraperitoneal for one, two, three and four weeks with or without nicotine were investigated in bone marrow of male mice utilizing micronucleus assay. Micronucleus test were performed with nicotine and green tea. The % MnPCE in each treatment group as well as the PCE / NCE ratio are shown in tables 1 and 2. Normal polychromatic erythrocytes (PCE), normal normochromatic erythrocytes (NCE) and micronucleated polychromatic erythrocytes (MnPCE) showing in photos (1) a, b, and c.

In the present study, The ameliorative effect of green tea is gradual, increased with increased the time of admistration of green tea with nicotine when study polychromatic ertherocytes (PCE), PCE/ NCE ratio and Mn-PCEs as shown in Tables 1&2. Treatment of green tea with nicotine was effective in reduction the frequencies of MnPCE in response to the time treatment. When green tea treated with nicotine for one, two or three weeks, the reduction in MnPCE come down to the same range of control

group and the percent of the reduction in group 1, 2, 3 and 4 was 62.5%, 57.1 %, 77.35 % and 81.8 % respectively. Whereas treatment of green tea with nicotine, significantly ($p < 0.05$) improved the number

of PCEs and the ratio of PCEs to NCEs were significant ($p < 0.05$) enhanced in compared to the control group.

Table (1): Effect of nicotine and / or green tea on the number of Leydig cells of testis section of Swiss albino mice.

Groups of experiment Time Of Treatment	Control groups	Nicotine groups	Green Tea groups	Nicotine -Green Tea groups
	(Mean ± S.E.)	(Mean ± S.E.)	(Mean ± S.E.)	(Mean ± S.E.)
Week 1	23.40±1.784 ^{BAa}	18.10±2.282 ^{Ba}	24.80±1.836 ^{Aa}	21.30±1.880 ^{BAa}
Week 2	23.70±.726 ^{BAa}	15.30±1.783 ^{Ca}	25.40±1.507 ^{Aa}	19.70±2.290 ^{BCa}
Week 3	23.90 ± 1.940 ^{Aa}	12.40±1.979 ^{Bba}	25.50±1.607 ^{Aa}	19.50±2.591 ^{Aa}
Week 4	24.60± 2.242 ^{Aa}	9.50±1.462 ^{Bb}	25.80±1.576 ^{Aa}	21.60±2.390 ^{Aa}

($P < 0.05$) is significant; ($P < 0.01$) is highly significant
 Numbers of experimental animals were 5 in all groups

Compared between control treated group, nicotine treated group, nicotine-green tea treated group and green tea treated group tacked capitals latter but compared within group of each group tacked small latter.

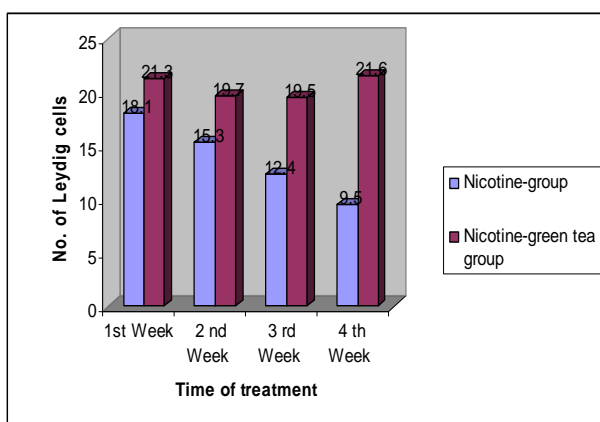


Fig (10): Effect of green tea administration on number of leydig cells in testis of nicotine intoxicated male albino mice.

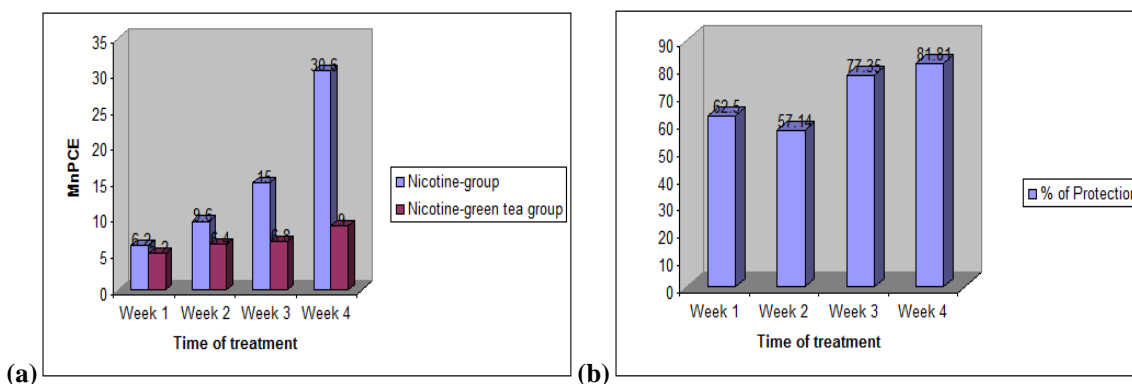


Figure (11): Histogram showing: (a) frequency of MnPCEs in nicotine and nicotine-green tea groups (b) Percentage of the reduction in MnPCEs in different treatments

Table (2): Represent the effect of Nicotine and Green Tea Treatment on Frequencies of MnPCE.

TOTAL NO. OF MnPCE / 5000 PCE				
Groups of Experimental	Control Groups	Nicotine groups	Green Tea Groups	Nicotine -Green Tea Groups
	(Mean ± S.E.)	(Mean ± S.E.)	(Mean ± S.E.)	(Mean ± S.E.)
Week 1	23 4.60 ± 0.748 ^{Aa}	31 6.20 ± 0.860 ^{Ac}	20 4.00 ± 0.707 ^{Aa}	26 5.20 ± 0.663 ^{Ab}
Week 2	4.00 ± 0.837 ^{Ba}	9.60 ± 1.166 ^{Acb}	3.80 ± 0.860 ^{Ba}	6.40 ± 1.208 ^{Bba}
Week 3	4.40 ± 0.678 ^{CBa}	15.00 ± 1.224 ^{Ab}	3.60 ± 0.509 ^{Ca}	6.80 ± 0.663 ^{Bba}
Week 4	4.20 ± 0.583 ^{Ba}	30.60 ± 4.523 ^{Aa}	3.20 ± 0.583 ^{Ba}	9.00 ± 1.140 ^{Ba}

Statistical analysis of results were done according to Duncan's multiple rang test. Means with different letters within each column (small letters) or each row (capital letters) are significant at 5 % level. = Micronucleated polychromatic erythrocytes PCE Mn. Five animals /group; 1000 cells /animal.

Table (3): Represent the effect of Nicotine and Green Tea Treatment on the ratio of normochromatic erythrocytes (NCEs) to polychromatic erythrocytes (PCEs)

Parameter	Groups of Experimental Time Of	Control groups	Nicotine groups	Green Tea groups	Nicotine -Green Tea groups
		(Mean ± S.E.)	(Mean ± S.E.)	(Mean ± S.E.)	(Mean ± S.E.)
%PCE	Week 1	45.40 ± 0.953 ^{Aa}	42.50 ± 1.580 ^{Aa}	46.30 ± 1.028 ^{Aa}	42.96 ± 2.26 ^{Aa}
	Week 2	46.34 ± 0.668 ^{Aa}	37.94 ± 0.624 ^{Ba}	46.90 ± 1.492 ^{Aa}	38.18 ± 0.85 ^{Bb}
	Week 3	47.28 ± 0.435 ^{Aa}	29.38 ± 3.919 ^{Cb}	47.60 ± 0.646 ^{Aa}	37.84 ± 0.79 ^{Bb}
	Week 4	47.70 ± 0.750 ^{Aa}	20.60 ± 2.454 ^{Cc}	48.26 ± 0.483 ^{Aa}	34.32 ± 1.17 ^{Bb}
%NCE	Week 1	54.60 ± 0.953 ^{Aa}	57.50 ± 1.580 ^{Ac}	53.70 ± 1.028 ^{Aa}	57.04 ± 2.26 ^{Ab}
	Week 2	53.66 ± 0.668 ^{Ba}	62.06 ± 0.624 ^{Ac}	53.10 ± 1.492 ^{Ba}	61.82 ± 0.85 ^{Aa}
	Week 3	52.72 ± 0.435 ^{Ca}	70.62 ± 3.919 ^{Ab}	52.40 ± 0.646 ^{Ca}	62.16 ± 0.79 ^{Ba}
	Week 4	52.30 ± 0.750 ^{Ca}	79.40 ± 2.454 ^{Aa}	51.74 ± 0.483 ^{Ca}	65.68 ± 1.17 ^{Ba}

4. Discussion:

Our result showed that disorganization of the seminiferous tubules associated with reduction of spermatogenic cells, leading to widening of lumen of seminiferous tubules upon nicotine toxicity. Many of seminiferous tubules exhibited degenerative phases of spermatocytes and spermatides as well as missing of sperms and hypo-spermatogenesis.

Fávaro *et al.* (2006); Ahmadnia *et al.* (2007) and Yamamoto *et al.* (2007) reported many alterations attributed to the direct cytotoxic effects of nicotine leading to the inhibition of prostaglandin's synthesis and decrease of testosterone which play a functional role in reproduction system of the male mice. Other investigation displayed that nicotine was a CNS depressor that can inhibit the neural stimulus essential for the release of pituitary gonadotrophine (Reddy *et al.*, 1998), which lead to a lack of pituitary gonadotrophins essential for initiating and completing spermatogenesis and steroidogenesis in the testis (Aydos *et al.*, 2001). Destruction of Leydig cells may cause testicular atrophy; gonadal dysfunction, erectile dysfunction, and male factor

infertility were showed by Kim *et al.*, (2005). Other studies explained that metabolites of nicotine as cotinine produced dose response inhibition of luteinizing hormone and 3 α -hydroxysteroid dehydrogenase, enzyme stimulated testosterone production (50-70%) (Fávaro *et al.*, 2006).

Aydos *et al.*, (2001) and Ahmadnia *et al.*, (2007) explained that nicotine toxicity may be due to change in the proportion of collagen fibers and contractile myofibroblastic cells, which may prevent the appropriate release of spermatozoa from the germinal epithelium into the lumen.

The oxidative stress of nicotine may cause a peroxidant/antioxidant imbalance in blood cells, blood plasma, and tissues resulting in a decrease in the activity of endogenous antioxidant enzymes (Suleyman *et al.*, 2002). Other researchers reported disruption of spermatogenesis in nicotine treated animals' testes tissues may be modulated by free radical toxicity (El-Sweedy *et al.*, 2007). Also nicotine metabolite cotinine generates free radicals / ROS in tissues in the liver and testes (Kalpane and Menon, 2004), and induces oxidative tissue injury

(Husain *et al.*, 2001 and Argentine & Cicchetti, 2004).

Direct genotoxic effects have been shown in human gingival fibroblasts (Sassen *et al.*, 2005 and Kleinsasser *et al.* (2006) and DNA strand breaks in human spermatozoa in nicotine aneuploidy and polyploidy, sister chromatid exchanges and chromosome aberrations in bone marrow cells of mice (Sen and Sharma, 1991 and Yauk *et al.*, 2007). High doses of nicotine increase the frequencies of premature centromere separation and premature anaphase and reduce the number of oocytes ovulated (Attia, 2007 and Sudheer *et al.*, 2007)

Results concerning the mutagenicity of nicotine in several test systems are contradictory. In the present study, nicotine intoxicated group obtained highly significant and gradual increased of MnPCEs throughout all the tested experimental periods. The statistical analysis of data is also provided. Nicotine treated mice, for one, two, three and four weeks resulted in highly significant alterations of all monitored parameters, but with different intensity and distinctive time trends. Nicotine intoxicated group obtained highly significant and gradual decreased of PCEs and PCEs /NCEs but gradual increased in NCEs throughout all the tested experimental periods.

The differences between the results can be attributed to different drug concentrations and the different genotoxic endpoints considered in the test systems. Different repair capacities of the various cell types used may also explain the discrepancies. The micronucleus technique has been proposed as a useful tool for measurement of genotoxicity (Madhumita *et al.*, 2003) induced by nicotine as it is able to assess both the clastogenic and aneugenic properties of a test compound. The genotoxic effects of nicotine have been shown in human gingival fibroblasts and spermatozoa and damage to DNA may result in mutations and altered cell functions (Kleinsasser *et al.*, 2005 and Ogura *et al.*, 2008).

In the present investigation a significant increase in the levels of NCE, and increased micronuclei frequency in nicotine-treated groups, as indicative of DNA damage, when compared with control group. The results were in a gradient with those reported by Villard *et al.* (1998) who mentioned that nicotine causes *in vivo* DNA single-strand breaks (SSB) in lung and liver of mice and those reported by Sassen *et al.* (2005) who reported that nicotine increases the DNA fragmentation in mini organ cultures. Hassan and Ahmed 2004, proved that green tea were inhibit the induction of Mn-PCEs in bone marrow of mice by 66% and 90%

when treated for one and two weeks respectively. Ayako (2004) suggests that tea catechins are not genotoxic but rather have a preventive effect against reactive oxygen species ROS -induced chromosomal damage at their physiological condition. These useful effects of tea catechins against ROS-induced chromosomal damage may support the cancer-preventing effects of tea constituents (Fujiki *et al.*, 2002).

Corresponding author:

Azza M. Gawish

Department of Zoology, Faculty of Science, Cairo University, Cairo, Egypt

azzagawish@ymail.com

5. References:

- 1- Ayako, S. (2004): Nicotine induces apoptosis in TM3 mouse Leydig Cells. *Fertility and Sterility*_ Vol. 83,pp. 1093-1099
- 2- Ahmadnia H., Ghanbari M., Moradi M. R., Khaje-Dalouee M. (2007): Effect of Cigarette Smoke on Spermatogenesis in Rats. *Urology*; 4: 3-11.
- 3- Arabi. M. (2004): Nicotinic infertility: Assessing DNA and plasma membrane integrity of human spermatozoa, *Andrologia*; 36: 305–310.
- 4- Argentin, G., Cicchetti. R. (2004): Genotoxic and antiapoptotic effect of nicotine on human gingival fibroblasts, *Toxicol. Sci.* 79; 75–81.
- 5- Arif, J.M., Gairola, C.G., Kelloff, G.J., Lubet, R.A., and Gupta, R.C. (2000): Inhibition of cigarette smoke-related adducts in rat tissues by indole-3-carbinol. *Mutat. Res.* 452, 11–18
- 6- Attia S. M. (2007): Chromosomal composition of micronuclei in mouse bone marrow treated with rifampicin and nicotine, analyzed by multicolor fluorescence *in situ* hybridization with pancentromeric DNA probe. *Toxicology* 235, 112–118.
- 7- Aydose, K., Gue Ven, M. C., Can B., and Ergue N. (2001): Nicotine toxicity to the ultra-structure of the testis in rats. *BJU International* 88, 622±626.
- 8- Bancroft J. D. and Stevens A. (2002): *Theory and Practice of Histological Techniques*. Fourth Edition, Queen's Medical Center, Nottingham, University Hospital NHS Trust.
- 9- Bishun, N.P., Lloyd, N., Raven, R.W., Williams, D.C. (1972): The *in vitro* and *in vivo* cytogenetic effects of nicotine. *Acta Biol. Acad. Hung.* 23, 175–180.
- 10- Cao, M.F., X.Q. Yang and Z.S. Jia (1992): Studies on antimutagenic effect of green tea polyphenol, *Acta Agric. Zhejiangensis*, 18: 85-90.

- 11-De Flora, S., Balansky, R.M., D'Agostini, F., Izzotti, A., Camoirano, A., Bennicelli, C., Zhang, Z., Wang, Y., Lubet, R.A., You, M. (2003): Molecular alterations and lung tumors in p53 mutant mice exposed to cigarette smoke. *Cancer Res.* 63, 793– 800.
- 12-Elshal M., El-Sayed I. H., , Elsaied M. A., El-Masry S. A., Uumosani T. A. (2009): Sperm head defects and disturbances in spermatozoal chromatin and DNA integrities in idiopathic infertile subjects: Association with cigarette smoking. *Clinical Biochemistry* 42, 589–594.
- 13-Favaro, W.J., Cagnon. V.H. (2006): Morphometric and morphological features of the ventral prostate in rats submitted to chronic nicotine and alcohol treatment. *Tis. and Cell* 38, 311–23.
- 14-Hecht, S.S. (2003): Tobacco carcinogens, their biomarkers and tobacco-induced cancer. *Nat Rev Cancer* 3: 733-744.
- 15-Heddle, J. A. (1973). A rapid in vivo test for chromosomal damage. *Mutat. Res.* 18(2):187-90.
- 16-Husain, K., Benjamin R. Scott, Sathya K. Reddy, Satu M. Somani. (2001): Chronic ethanol and nicotine interaction on rat tissue antioxidant defense system . *Alcohol* 25, 89–97.
- 17-Kavitharaj NK, Vijayammal PL. (1999): Nicotine administration induced changes in the gonadal functions in male rats. *Pharmacology*; 58: 2±7
- 18-Kleinsasser, N.H., Sassen, A.W., Semmler, M.P., Harreus, U.A., Licht, A.K., Richter, E. (2005): The tobacco alkaloid nicotine demonstrates genotoxicity in human tonsillar tissue and lymphocytes. *Toxicological Sciences* 86, 309–317.
- 19-Liu, X., Lu, J., Liu, S. (1999): Synergistic induction of hydroxyl radical-induced DNA single- strand breaks by chromium (VI) compound and cigarette smoke solution. *Mutation Research* 440, 109–117.
- 20-Madhumita Roy, Sutapa Chakrabarty, Dona Sinha, Rathin Kumar Bhattacharya, Maqsood Siddiqi. (2003): Anticlastogenic, antigenotoxic and apoptotic activity of epigallocatechin gallate: a green tea polyphenol . *Mutation Research* 523–524, 33–41
- 21-Ogura R. A., Ikeda N., Yuki K., Morita O., Saigo K., Blackstock, C., Nishiyama N., Kasamatsu T. (2008): Genotoxicity studies on green tea catechin Food and Chemical Toxicology; 46, 2190–2200.
- 22-Okamoto, M., Kita, T., Okuda, H., Tanaka, T., Nakashima, T. (1994). "Effects of aging acute toxicity of nicotine in rats". *Pharmacol Toxicol.* 75 (1): 1-6.
- 23-Park, E. M., Park, Y. M., & Gwak, Y. S. (1998): Oxidative damage in tissues of rats exposed to cigarette smoke. *Free Radic Biol Med*; 25, 79–86.
- 24-Polyzos A., Schmid T. E., Piña-Guzmán B., Quintanilla-Vega B., Marchetti F. (2009): Differential sensitivity of male germ cells to mainstream and sidestream tobacco smoke in the mouse. *Toxic. and App.and Pharma.*
- 25-Reddy, S., Londonkar, R., Patil, S.B. (1998): Testicular changes due to graded doses of nicotine in albino mice. *Ind. J. Physiol. Pharma.* 42, 276–280. .
- 26-Reibel, J. (2003): Tobacco and oral diseases. Update on the evidence, with recommendations. *Medicinal Principles and Practice* 11, 22–32.
- 27-Salamone, M.; Heddle, J.; Stuart, E. and Katz, M. (1980): Towards an improved micronucleus test. *Mutation Res.*, 74, 347-356.
- 28-Sassen, A.W., Richter, E., Semmler, M.P., Harreus, U.A., Gamarra, F., Norbert, H., Kleinsasse, N.H. (2005): Genotoxicity of nicotine in mini-organ cultures of human upper aerodigestive tract epithelia. *Toxicol. Sci.* 88 (1), 134–141.
- 29-San RHC, Rosin MP, See RH, Dunn BP & Stich HF (1989): Use of urine for monitoring human exposure to genotoxic agents. A. C. S. Symposium Series. Biological Monitoring for Pesticide Exposure, Measurement, Estimation and Risk Reduction. Washington, DC. pp.382: 98-116.
- 30-Schmid W. (1975): the micronucleus test, *Mutat. Res.* 31, 9-15 .
- 31-Sen, S. and Sharma, A., 1991. Inhibition of clastogenic effects of nicotine by chlorophyllin in mice bone marrow cells in vivo. *Phytotherap. Res.* 6, 130–133.
- 32-Shim J. S., Kang M. H., Kim Y. H., Roh J. K., Roberts C., and Lee' I. P. (1995): Chemopreventive Effect of Green Tea (*Came/ha sinensis*) among Cigarette Smokers. *Cancer Epidemiology, Biomarkers & Prevention* Vol. 4. 387-391.
- 33-Sudheer, A.R., Muthukumar, S., Devipriya, N., Menon, V.P. (2007a): Ellagic acid, a natural polyphenol protects rat peripheral blood lymphocytes against nicotine-induced cellular

- and DNA damage in vitro: with the comparison of *N*-acetylcysteine. *Toxicology* 230, 11–21.
- 34-Suleyman, H., Gumustekin, K., Taysi, S., Keles S. (2002): Beneficial effects of *Hippophae rhamnoides* L. on nicotine induced oxidative stress in rat blood compared with vitamin E, *Biol Pharm Bull.* 25, 1133–6.
- 1-Sweedy, M., Abdel-Hamid, N., El-Moselhy, M. (2007): The role of a mixture of green tea, turmeric and chitosan in the treatment of obesity-related testicular disorders. *Journal of applied biomedicine.* 5: 131–138
- 35-Therriault, M.J., Proulx, L.I., Castonguay, A., Bissonnette, E.Y. (2003): Immunomodulatory effects of the tobacco-specific carcinogen, NNK, on alveolar macrophages. *Clin. Exp. Immunol.* 132, 232–238.
- 36-Wu, Y.P., Kita, K., Suzuki, N., (2002): Involvement of human heat shock protein 90 α in nicotine – induced apoptosis. *Int. J. Cancer* 100, 37 – 42.
- 37-Yamamoto Y, Isoyama E, Sofikitis N, Miyagawa I. (1998): Effects of smoking on testicular function and fertilizing potential in rats. *Urol Res*; 26:45– 8.
- 38-Yardimci, S., Atan, A., Delibasi, T., Sunguroglus K., Guven. M. C. (1997): Long- term effects of cigarette-smoke exposure on plasma testosterone, luteinizing hormone and follicle-stimulating hormone levels in male rats. *British Journal of Urology*; 79, 66-69.
- 39-Yauk, C.L., Berndt, M.L., Williams, A., Rowan-Carroll, A., Douglas, G.R., Stampfli, M.R., (2007): Mainstream tobacco smoke causes paternal germ-line DNA mutation. *Cancer Res.* 67, 5103–5106.
- 40-Yildiz, D., Liu, Y.S., Ercal, N., Armstrong, D.W. (1999): Comparison of pure nicotine-and smokeless tobacco extract-induced toxicities an oxidative stress. *Arch. Environ. Contam. Toxicol.* 37, 434– 439.
- 41-Yokozawa, T.;Rhyu,D.Y. and Cho, E.J.(2004): (-)-Epigallocatechin-3-O-gallate ameliorates the damages related to peroxynitrite production by mechanism distinct from those of other free radical inhibitors .*J. Pharma Pharmacol.*, 56: 231-9.

9/19/2010