

Ginger Administration has a Protective Effect on the Liver of Albino Rats Treated with 6-Mercaptopurine Drug

¹Olfat A. Abd-El Aty and ²Enas N. Morgan

¹Department of Anatomy, Faculty of Medicine, Al-Azhar –University (girls)

²Department of Physiology, Faculty of Medicine, Zagazig - University

*Olfat_fair@yahoo.com

Abstract: The leukemia is considered to be one of the most frequent tumors in childhood. The first line of its treatment is 6-mercaptopurine (6-MP). There are many recorded cytotoxic effects for 6-mercaptopurine on tissues such as liver, pancreas and bone marrow. Nowadays the needs for administration of cytotoxic drugs are increased as the incidence of malignancies increases. So we have to search for a safe method that can minimize the side effects of these cytotoxic drugs. The ginger has many benefits as anti-inflammatory and anti-oxidant substance. Some indicated as a protective effect for ginger on the radiotherapy treated rats and also a protection from the hepatotoxic and gonado-toxic drugs were recorded. This work aimed to investigate the protective effects of ginger on liver of rats treated by cytotoxic drug (6-mercaptopurine), a drug of choice in maintenance therapy for leukemia in adult and children. Our hope is to minimize the side effects of the cytotoxic drugs with simple and available procedure. **Material** The current study had been carried on 40 white albino rats that divided into four equal groups. Group I: was served as control group. Group II: was given ginger extract only. Group III: was given 6-MP. Group IV: was given 6-MP + ginger extract. The following parameters were examined in all groups: 1- The serum Alanine aminotransferase (ALT), and aspartate aminotransferase (AST). 2- The cell morphology and histo-pathological changes in the liver. **The results** of the present study showed that treatment with 6-MP alone caused marked signs of cellular degeneration and necrosis of the hepatic tissues, significant increase in the serum levels of ALT (P<0.001) and AST (P<0.001) enzymes when compared with control group. However, the treatment by ginger along with 6-MP showed marked regeneration and improvement in the hepatic tissues and significant decrease in the serum levels of liver enzymes; ALT (P<0.001) and AST (P<0.001) when compared with 6-MP treated group. **Conclusion:** These findings indicated that ginger has protective effect against 6-MP induced hepatic toxicity.

[Olfat A. Abd-El Aty and Enas N. Morgan. Ginger Administration Has a Protective Effect on The Liver Of Albino Rats Treated with 6-Mercaptopurine Drug. Journal of American Science 2011;7 (5):737-745]. (ISSN: 1545-1003). <http://www.americanscience.org>.

Keywords: Ginger, 6-MP, hepatic toxicity.

1. Introduction:

The leukemia is considered to be one of the most frequent tumors in children ¹. The first line of its treatment is 6-mercaptopurine ². There are many recorded cytotoxic effect for 6-mercaptopurine on tissues such as liver, pancreas, and bone marrow, and kidney ^{3,4,5}

6-Mercaptopurine (6-MP) is a purine anti-metabolite widely used in the treatment of acute lymphoblastic leukemia (ALL) ². MP is an inactive pro-drug that requires intracellular activation catalyzed by multiple enzymes to exert cytotoxicity. ^{6,7} Cytotoxic effects of MP are achieved primarily through the incorporation of TGN (thioguanine nucleotides) into RNA and DNA. ^{8,9} The incorporation of TGN, as deoxy-TGN triphosphate, inhibits the function of several enzymes involved in DNA replication and repair and induces DNA damage. ^{10,11}

The usual toxic effects of 6-MP are those of bone marrow depression, nausea, vomiting and diarrhea. ¹² Animal studies indicated degenerative changes in the

intestinal epithelium and liver which were characterized by impaired function, parenchymal necrosis, cirrhosis, jaundice and frequently severe diarrhea. ^{3,4}

Samuel and John ¹² demonstrated that by the histological examination of the liver after 6-MP treatment, there was a pronounced stasis of bile as indicated by numerous bile thrombi. A prominent disruption of the normal hepatic architecture in the form of a complete loss of the hepatic cords is seen. Many individual hepatic cells are swollen by a metachromatic granular cytoplasm. Many of these cells are multinucleated. There is considerable variation in the size and chromatin pattern of the nuclei. Bile pigment is prominent in the Kupffer cell.

Moreover, Cuffari et al. ⁵ indicated that hepatitis, pancreatitis, and marrow suppression were generally associated with increased 6-MP levels. In addition Dubinsky et al. ¹³ have demonstrated drug-induced hepatotoxicity in 10–15% of pediatric patients which has been associated with the 6-MP metabolite and 6-

methylmercaptapurine ribonucleotide. Other study demonstrated that the levels of 6-MP and its methylated metabolites are correlated with the degree of hepatotoxicity during 6-MP maintenance therapy.¹⁴

Ginger has a long tradition of being very effective in alleviating symptoms of gastrointestinal distress and reducing intestinal gas. Reviews such as Borelli et al.¹⁵ of six double-blind, randomized controlled trials with a total of 675 participants, have demonstrated that Ginger can be as effective as over the counter drugs for the control of nausea in pregnant women.

Modern researches have revealed that ginger possesses numerous therapeutic properties including immune boosting, antioxidant effects,^{16,17} an ability to inhibit the formation of inflammatory compounds, and direct anti-inflammatory effects.¹⁸

Moreover, a number of studies demonstrated ginger root's is effective as a painkiller / anti inflammatory and has a benefits for improving osteoarthritis.^{19,20}

Gingerols, which is the main active components in ginger and the responsible for its distinctive flavor, may also inhibit the growth of human colorectal cancer cells²¹ although human studies are yet to confirm that.

Moreover, Rhode et al.²² results indicated that ginger is a nutraceutical that may have significant therapeutic benefit for ovarian cancer patients as ginger induced cell death in all ovarian cancer cell lines tested.

Jagetia et al.²³ indicated that the pretreatment of mice with ginger, reduced the severity of radiation sickness and the mortality at all doses. The ginger treatment protected mice from GI syndrome as well as bone marrow syndrome. As the pretreatment with ginger reduced the irradiation dose-dependent elevation in the lipid peroxidation and depletion of glutathione. Moreover, Jagetia et al.²⁴ reports that ginger has a protective effect in the radiotherapy treated rats as it decreased both the severity of radiation sickness and mortality at all the exposure doses through scavenging OH, O₂ and ABTS radicals in a dose-dependent manner in vitro.

There are also a recorded protective effects for ginger extract on the hepatotoxic effects of both carbon tetrachloride and acetaminophen as it improved the elevated serum liver enzymes and the protective effect of the extract was confirmed also by histo-pathological examination of the liver.²⁵

The aim of the present study was to determine the extent to which ginger, can be used as protective therapies from chemo-toxic effects of 6-MP on the liver cells and its functions.

2. Material and Methods:

Experimental animal:

40 white adult male albino rats (weight 185-200gm) were housed at 21°C–22°C in a 12 hr/12 hr

light/dark cycle, fed standard rat chow, and given free access of water. Rats accommodated to the laboratory conditions for 2 weeks before starting the experiment.

Experimental methodology:

The rats were divided into four groups of 10 rats/each. *Group I:* animals were served as control. *Group II:* animal received oral ginger extract at a daily dose of 200 mg/kg body weight by gavage. *Group III:* rats received 6-MP (manufactured by Wellcome Drugs under brand name Puri-nethol) in a dose of 3.5mg/kg/day for 4 weeks. The maintenance therapeutic dose is 2.5 mg/Kg, during the course; dosage may be increased up to 5 mg/Kg¹². In the present study we used the average dose (3.5mg/kg) orally. *Groups IV:* the ginger with the same dose at group II was gavaged to rats two hours before 6-MP treatment at a same dose with group III.²⁶

At the end of the experimental period (6 weeks), blood samples will be collected from each rat through the retro-ocular puncture. For biochemical analysis, sera were obtained by centrifugation of the blood sample and then they were stored at -20°C until assayed for Alanine aminotransferase (ALT), and aspartate aminotransferase (AST) on the basis of *Gella et al.*²⁷ Then all studied animals were sacrificed, the livers are excised and will be prepared to histopathological study.

The histopathological preparation:

The liver tissues will be fixed in Bouin's solution for 48 h. Later, they were dehydrated in graded levels of ethanol, cleared in xylene, and embedded in paraffin wax for sectioning. The 5- μ m thick sections were cut, mounted on glass slides, and stained with hematoxylin and eosin stain and Masson's trichrome stain for light microscopic analysis⁴⁵.

Methods getting aqueous ginger extract:

According to the method of Sakr,²⁸ the Rhizomes of *Z. officinal* were shade, dried at room temperature and were crushed to powder. 125 g of the powder were macerated in 1000 ml of distilled water for 12 h. at room temperature and were then filtered to obtain the final aqueous extract. The concentration of the extract is 24 mg/ml.

Statistical analysis:

All analyses were performed using an SPSS program (version 17.0, SPSS, Inc., Chicago, IL). Differences were analyzed via an ANOVA followed by Tukey's post hoc test. Data are presented as means (\pm S.D) with significance set at $P < 0.05$

3. Results:

Biochemical analysis:

In the current study it was found that ALT serum level (IU/ml) in control group was 19.9 ± 1.42 (Mean \pm SD).

There were insignificant differences in ALT serum level between the control and ginger treated groups 19.81 ± 1.78 ($P > 0.05$). While, administration of 6-MP significantly increase the ALT serum level 39.27 ± 2.88 when compared with control ($P < 0.001$) and ginger treated group ($P < 0.001$). While administration of ginger along with the 6-MP significantly decrease the levels of ALT 21.47 ± 1.29 , when compared with the 6-MP treated group ($P < 0.001$). There were insignificant differences between the ginger+6-MP treated group and both control and ginger treated group ($P > 0.05$) *Table (1); Figure (1)*.

The AST serum level (IU/ml) in control group was 41.93 ± 1.73 (Mean \pm SD). There were insignificant differences in AST serum levels between the control and ginger treated groups 43.55 ± 1.96 ($P > 0.05$). While, administration of 6-MP significantly increase the AST serum level 93.43 ± 6.49 when compared with control ($P < 0.001$) and ginger treated group ($P < 0.001$). While administration of ginger along with the 6-MP significantly decrease the levels of AST 47.27 ± 3.66 , when compared with the 6-MP treated group ($P < 0.001$). However; There were significant differences in the AST level in ginger+6-MP treated group when compared with both control ($p < 0.01$) and ginger treated group ($P < 0.05$) *Table (2); Figure (2)*.

The histopathological examination:

The results of the histopathological study of the livers are going hand in hand with the biochemical results. Light microscopic examination of the transverse sections of livers of the control and ginger treated rats revealed that the livers exhibited normal appearance as it consisted of many hepatic lobules each of which had a central vein and hepatic cords. These hepatic cords were formed by hepatocytes which were

irregularly radiating from the central vein towards the periphery and separated from each other by blood sinusoid. The later were lined with Von Kupffer cells which had large fusiform dark nuclei. The hepatocytes are polyhedral in shape with eosinophilic granular cytoplasm and vesicular basophilic nuclei (Fig 3, A & B). Also, the portal tracts in the control and ginger treated rats were similar, both contained normal sizes of portal vein, a branch of hepatic artery and a branch of bile duct (Fig. 4, E & F). A normal fibrous tissue distribution could be seen in the portal tracts in the control and ginger treated rats (Fig.5, I & J).

In contrast, the histopathological finding in 6-MP treated rats showed marked signs of cellular degeneration and necrosis in the centrilobular and mid zonal regions. There were loss of organized hepatic cords; most of the hepatocytes appeared edematous, swollen with irregular cytoplasm and karyolytic or pyknotic nucleoli. Also, some hepatocytes showed cytoplasmic vacuolations. These features with the presence of wide spaces in the sinusoid and in-between the hepatocytes indicated the presence of hydropic degeneration (Fig.3, C).

Moreover, numerous Von kupffer cells were represented with presence of focal necrotic lesion and inflammatory cells infiltration (Fig.3, C1). In addition, there were huge enlargement of a portal vein (Fig. 4, G) with marked deposition of collagen fibers around it. Also the collagen fibers were markedly deposited in the portal tract and within the sinusoids (Fig.5, K) indicating preportal fibrosis.

These features were improved in 6-MP +ginger treated group where most of the hepatocytes appeared similar to the control group except the presence of few cells contained pyknotic nuclei. No wide spaces in between the sinusoids. (Fig.3, D). The portal vein appeared slightly dilated (Fig. 4, H), with few collagen fibers deposition around the portal vein and in the portal tract (Fig. 5, L).

Table (1): Serum levels of ALT (IU/ml) in control, ginger treated, 6-MP treated and ginger + 6-MP treated groups

	control	Ginger treated	6-MP treated	Ginger + 6-MP treated
Mean \pm SD	19.9 \pm 1.42	19.81 \pm 1.78	39.27 \pm 2.88	21.47 \pm 1.29
F	237.4			
P	<0.001			
LSD		.093 ($p > 0.05$)	-19.37 ($P < 0.001$)	-1.57 ($p > 0.05$)
			-19.46 ($p \square 0.001$)	-1.66 ($P > 0.05$)
				17.81 ($p \square 0.001$)

Figure (1): serum levels of ALT (IU/ml) in control, ginger treated, 6-MP treated and ginger + 6-MP treated groups

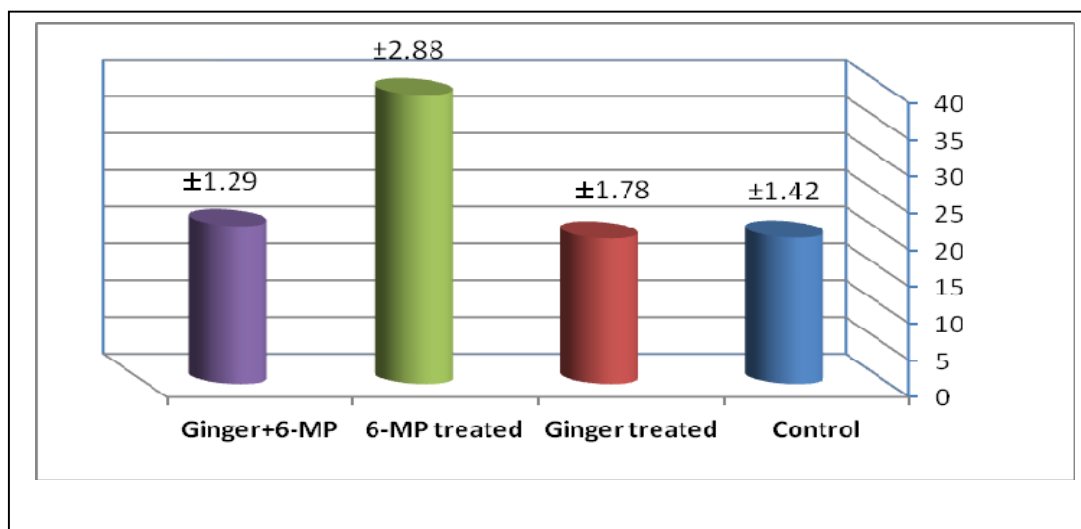
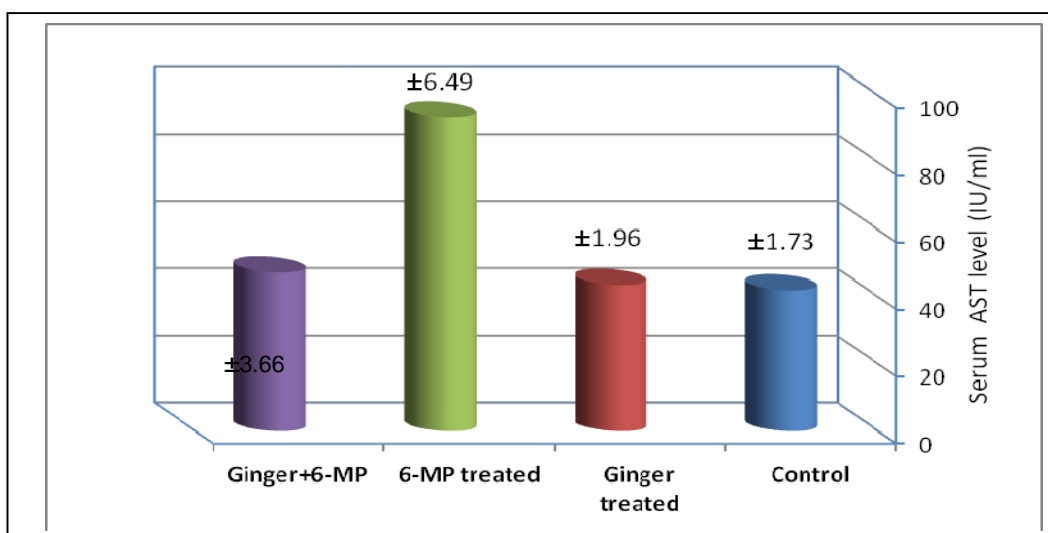


Table (2): Serum levels of AST (IU/ml) in control, ginger treated, 6-MP treated and ginger + 6-MP treated groups

	control	Ginger treated	DOX treated	Ginger + DOX treated
Mean ±SD	41.93± 1.73	43.55±1.96	93.43±6.49	47.27±3.66
F	391.3			
P	<0.001			
LSD		1.62 (p> 0.05)	51.50 (P<0.001)	5.33 (p 0.01)
			49.88 (p 0.001)	3.72 (P<0.001)
				46.16 (p<0.05)

Figure (2): Serum levels of AST (IU/ml) in control, ginger treated, 6-MP treated and ginger + 6-MP treated groups



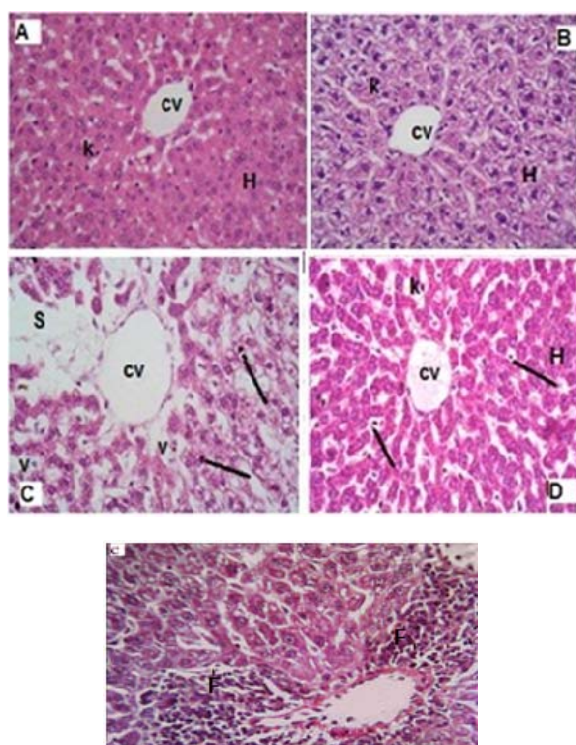


Fig.3. Photomicrograph of transverse sections of livers showing:

(A)Control and (B) ginger treated group show normal appearance of hepatic architecture, normal central vein (cv), hepatocytes (H) and Von kupffer cells (K). (Hx.& E.; X400)

(C)&(C1) 6MP treated group notice loss of hepatic architecture with presence of wide spaces(S) in-between the hepatic cords, many cells had pyknotic nuclei(/) and others had vacuolated cytoplasm (v) Notice also the presence of cellular inflammatory infiltrations (F). (Hx.& E.;X400)

(D) 6MP+ginger treated group the hepatocytes (H) appeared normal except the presence of few cells had pyknotic nuclei (/) .Notice the presence of normal Von kupffer cells (K) (Hx. &E.; X400)

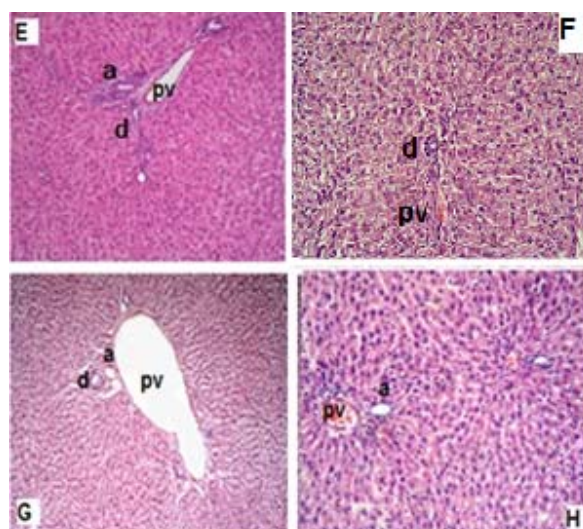


Fig.4. Photomicrograph of transverse sections of livers demonstrating the portal tracts in:

(E) Control and (F) ginger treated group show normal sizes of portal vein (pv),a branch of hepatic artery (a) and a branch of bile duct (d). (Hx. & E.; X200)

(G) 6-MP treated group notice the presence of irregularly dilated portal vein (pv) a branch of hepatic artery (a) and a branch of bile duct (d). (Hx. & E.; X200)

(H) 6-MP+ginger treated group the portal (pv) appeared similar to the control and ginger treated group (Hx. & E.; X200).

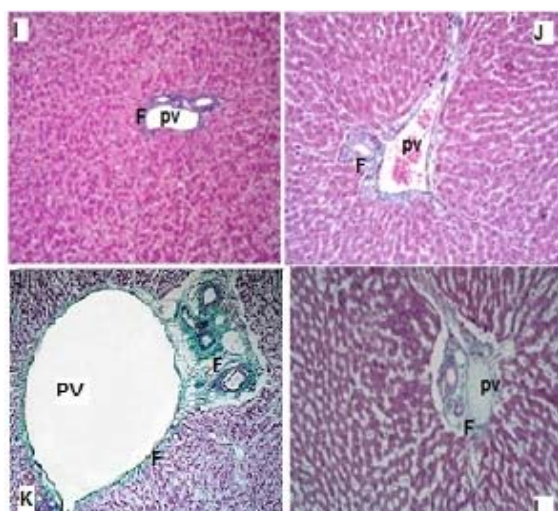


Fig.5. Photomicrograph of transverse sections of livers showing:

(I) Control and (J) ginger treated group have normal fibrous tissue (F) distribution around the portal vein (pv) and in the portal tracts

(Masson's trichrome X200).

(K) 6-MP treated group notice the presence of hugely dilated portal vein (pv) and marked deposition of collagen fibers (F) around it. Notice also marked deposition of the fibrous tissue in the portal tract and in-between the hepatic cords (F) (Masson's trichrome X100).

(L) 6-MP+ginger treated group show few collagen fibers deposition around the portal vein (pv) and in the portal tract (F)

(Masson's trichrome X200).

4. Discussion:

The present study indicated the toxic effect of 6-MP on hepatic tissue and its enzymatic activities. 6-MP was found to cause elevation in serum transaminases (AST, ALT).

That effect was detected by the research of Shorey et al.²⁹ who concluded that mercaptopurine is generally accepted as potentially hepatotoxic.

The histopathological examination of the liver tissue in the 6-MP treated group revealed marked cytoplasmic vacuolations, deposition of the collagen fibres in the portal tract and within the sinusoids and marked inflammatory cellular infiltration. Bogolipov³⁰; Halliwell and Chirico³¹ attributed the cytoplasmic vacuolation to the permeability disorders of the cell membranes caused by excess ROS mediated formation

of lipid peroxides. ROS can be generated from the xanthine oxidase (XOD) enzyme which is one of the enzymes that are competing for the initial metabolism of 6-MP.³²

Moreover, Kumar et al.³³ mentioned that deposition of collagen has lasting consequences on hepatic patterns of blood flow and perfusion of hepatocytes. In the initial stages; fibrosis may develop within or around portal tracts or central vein or may be deposited directly within the sinusoids. Poli and parolia³⁴ showed the frequent association of the pathogenesis of tissue fibrosis with enhanced lipid peroxidation and deranged antioxidant defence system.

Moreover, the results of the present study confirmed the protective effect of ginger against 6-MP induced liver toxicity, where there was a significant decrease in serum levels of ALT and AST after ginger administration along with 6-MP. In addition, the histopathological features were improved. As ginger administration along with 6-MP improved the dilation of the portal vein, decreased the cellular infiltration and decreased collagen fibres deposition around it and in the portal tract indicating the efficacy of the protective effect of ginger even in the difficult irreversible lesions. These finding goes in line with Kumar et al.³³ who provided a growing evidence for cessation of hepatic injury in some setting can lead to reversal of fibrosis. The best document was regression of fibrosis in treated schistosomal hepatic infection and hereditary hemochromatosis.

Moreover, Sakr et al.³⁵ found that treating rats with adriamycin and ginger improved the histopathological and biochemical changes induced in the liver by adriamycin. This indicated the effectiveness of ginger in prevention of adriamycin hepato-toxicity.

In addition, Ginger extract was found to have a protective effect on CCl₄ and acetaminophen-induced damage as confirmed by histopathological examination of the liver¹⁶. Siddaraju and Dharmesh¹⁷ reported that ginger-free phenolic and ginger hydrolysed phenolic fractions exhibited free radical scavenging, inhibition of lipid peroxidation, DNA protection and reducing power abilities indicating strong antioxidant properties.

The protective effects of ginger against hepatotoxicity are mainly due to its antioxidant and anti-inflammatory effects. Both water and alcoholic extracts of ginger have been shown to possess potent antioxidant activity on fats and oils and prevent lipid peroxidation, microsomal lipid peroxidation at concentrations greater than 150 mM. In addition zingerone functions as an effective scavenger of superoxide anions as measured by nitro-blue-tetrazolium reduction in a xanthine-xanthine oxidase system³⁶. Besides these findings, ginger has antioxidant activity due to its polyphenolic components

which have the capacity to be donors of hydrogen atoms or electrons and to capture the free radicals so act as radical scavengers³⁷. This is due to the presence of zingiberene and oleoresin³⁸. The antioxidant effect of ginger were identified in our pervious study on the protective effect of ginger in the gonadal toxicity caused by Doxorubicin (DOX) as administration of ginger along with the DOX caused significant increase in oxidative stress markers; superoxide desmutase (SOD) and catalase (CAT) serum levels and reduction in the lipid peroxidation marker; malondialdehyde enzyme (MDA)³⁹

Also since the mechanism of hepatic injury may be to due inflammatory process, so the hepato-protective activity of ginger may be due to its content of volatile oils, which showed anti-inflammatory, analgesic and immunomodulatory effects. Volatile oil of ginger is capable of inhibiting T lymphocyte dependent immune reactions⁴⁰. Moreover the anti-inflammatory activity of ginger is due to its ingredients as the gingerols and gingerol analogs (shogaols and paradols). Previous reports have documented the ability of these compounds to directly inhibit prostaglandin and leukotriene synthesis⁴¹. 6 Gingerol, besides having various pharmacological and physiological effects including anti-inflammatory, analgesic, antipyretic and gastroprotective activities, is also reported to have cardiotoxic and anti-hepatotoxic activities⁴². The anti-inflammatory effect of ginger identified in the current study as ginger administration along with the 6-MP significantly decreased the cellular infiltration in hepatic tissues.

Another benefit for ginger administration with chemotherapy may be its chemotherapeutic effect that recently demonstrated by the result of Bode²¹ and Zeinab^{43,44}. So, further investigation will be needed to study the chemotherapeutic effect of the ginger.

5. Conclusion

The results of the present work indicated an ameliorative effect of ginger extract against liver damage induced by 6-MP. This effect may be due to its potent antioxidant and anti-inflammatory activities.

Corresponding author

Olfat A. Abd-El Aty
Department of Anatomy, Faculty of Medicine, Al-Azhar –University (girls), Cairo, Egypt
Olfat_fair@yahoo.com

References:

- Margolin JF and Poplack DG. Acute lymphoblastic leukemia. In P. A. Pizzo & D. G. Poplack (Eds.), principles and practice of pediatric oncology, 3rd ed. 1997; 409-462.
- Pui CH and Evans WE. Acute lymphoblastic leukemia. N. Engl. J. Med., 1998; 339: 605-615.
- Phillips FS, Sternberg SS, Clarke DS and Hitchings CH. Effects of 6-mercaptopurine in mammals. Proc. Am. A. Cancer Res., 1953; 1:42.
- Clarke DA, Phillips FS, Sternberg SS, Stock CC, Elion GB and Hitchings CH. 6-Mercaptopurine: effects in mouse sarcoma 180 and in normal animals. Cancer Res., 1953; 13:593.
- Cuffari C, Théorêt Y, Latour S and Seidman G. 6-Mercaptopurine metabolism in Crohn's disease: correlation with efficacy and toxicity. Gut, 1996; 39: 401-406.
- Elion GB. The purine path to chemotherapy. Science, 1989; 244: 41-47.
- Lennard L, Lilleyman JS, Van Loon J and Weinshilboum RM. Genetic variation in response to 6-mercaptopurine for childhood acute lymphoblastic leukemia. Lancet, 1990; 336: 225-229.
- LePage GA. Basic biochemical effects and mechanism of action of 6-thioguanine. Cancer Res., 1963; 23: 1202-1206.
- Warren DJ, Andersen A and Slordal L. Quantitation of 6-thioguanine residues in peripheral blood leukocyte DNA obtained from patients receiving 6-mercaptopurine-based maintenance therapy. Cancer Res., 1995; 55:1670-1674.
- Krynetskaia₁ NF, Krynetski EY and Evans WE. Human RNase H-mediated RNA cleavage from DNA– RNA duplexes is inhibited by 6-deoxythioguanosine incorporation into DNA. Mol Pharmacol., 1999; 56: 841-848.
- Krynetskaia₂ NF, Cai X, Nitiss JL, Krynetski EY and Relling MV. Thioguanine substitution alters DNA cleavage mediated by topoisomerase II. FASEB J., 2000; 14:2339-2344.
- Samuel KM and John DM. Hepatitis in Association with Prolonged 6-Mercaptopurine Therapy. Blood, 1959; 14: 80-90.
- Dubinsky MC, Lamothe S, Yang HY, Targan SR, Sinnott D, Théorêt Y, and Seidman EG. Pharmacogenomics and metabolite measurement for 6-mercaptopurine therapy in inflammatory bowel disease. Gastroenterology, 2000; 118: 705–713.
- Nygaard U, Toft N. and Schmiegelow K. Methylated metabolites of 6-mercaptopurine are associated with hepatotoxicity. Clin. Pharmacol. Ther., 2004; 75: 274–281.
- Borrelli F, Capasso R, Aviello G, Pittler MH. and Izzo AA. Effectiveness and safety of ginger in the treatment of pregnancy-induced nausea and vomiting. Obstet. Gynecol., 2005; 105(4):849-56.

16. Yemitan OK and Izebu MC. Protective effects of *Zingiber officinale* (Zingiberaceae) against carbon tetrachloride and acetaminophen-induced hepatotoxicity in rats. *Phytother Res.*, 2006; 20 (11): 997-1002.
17. Ajith TA, Nivitha V. and Usha S. *Zingiber officinale* Roscoe alone and in combination with alpha-tocopherol protect the kidney against cisplatin-induced acute renal failure. *Food Chem. Toxicol.*, 2007; 45(6):921-7.
18. Ojewole JA. Analgesic, anti-inflammatory and hypoglycaemic effects of ethanol extract of *Zingiber officinale* (Roscoe) rhizomes (Zingiberaceae) in mice and rats. *Phytother Res.*, 2006; 20 (9): 764-72.
19. Bliddal H, Rosetzky A, Schlichting P, Weidner MS, Andersen LA, Ibfelt HH, et al. A randomized, placebo-controlled, cross-over study of ginger extracts and ibuprofen in osteoarthritis. *Osteoarthritis Cartilage* 2000; 8:9-12.
20. Shen CL, Hong KJ. And Kim SW. Comparative effects of ginger root (*Zingiber officinale* Rosc.) on the production of inflammatory mediators in normal and osteoarthrotic sow chondrocytes. *J. Med. Food.*, 2005; 8 (2): 149-53.
21. Bode A. Ginger is an effective inhibitor of HCT116 human colorectal carcinoma in vivo. paper presented at the Frontiers in Cancer Prevention Research Conference, Phoenix, AZ., 2003; 26 (3).
22. Rhode JM, Huang J, Fogoros S, Tan L, Zick S. and Liu JR. Ginger induces apoptosis and autophagocytosis in ovarian cancer cells. Abstract #4510, presented April 4, 2006 at the 97th AACR Annual Meeting, April 1-5, 2006; Washington, DC.
23. Jagetia G, Baliga M, Venkatesh P. and Ulloor JN. Influence of Ginger Rhizome (*Zingiber officinale* Rosc) on Survival, Glutathione and Lipid Peroxidation in Mice after Whole-Body Exposure to Gamma Radiation. *Radiat. Res.*, 2003; 160, 584–592.
24. Jagetia G, Baliga M and Venkatesh P. Ginger (*Zingiber officinale* Rosc.), a dietary supplement, protects mice against radiation-induced lethality: mechanism of action. *Cancer Biother. Radiopharm.*, 2004; 19 (4): 422-35.
25. Yemitan OK and Izebu MC. Protective effects of *Zingiber officinale* (Zingiberaceae) against carbon tetrachloride and acetaminophen-induced hepatotoxicity in rats. *Phytother. Res.*, 2006; 20 (11): 997-1002.
26. Laila ME and Sahar SA. Alpha-tocopherol and ginger are protective on Cyclophosphamide-induced gonadal toxicity in adult male albino rats. *Basic and Applied Pathology*, 2009; 2: 21–29.
27. Gella, FJT, Olivella M, Crus-pastor J, Arenas R, Moreno R, Durban JA. and Gomez A. simple procedure for routine determination of aspartate amino-transferase and alanine amino-transferase with pyridoxal phosphate. *Clin. Chem. Acta.*, 1985; 153: 241-24.
28. Sakr SA. Ameliorative Effect of Ginger (*Zingiber officinale*) on Mancozeb Fungicide Induced Liver Injury in Albino Rats. *Australian Journal of Basic and Applied Sciences*, 2007, 1(4): 650-656.
29. Shorey J, Schenker S, Suki WN. and Combes B. Hepatotoxicity of Mercaptopurine. *Arch Intern Med.*, 1968; 122 (1): 54-58.
30. Bogolipov NN. Ultrastructure Of the brain in hypoxia: translated from Russian by Muchael burov. Mir publishers. Moscow, 1983; 11: 68-80.
31. Halliwell B and Chirico S. Lipid peroxidation. Its mechanism measurement and significance. *J. Chin. Nutr.*, 1993; 25: 7152-8252.
32. Petit E, Langouet S, Akhdar H, Nicolas-Nicolaz C, Guillouzo A. and Morel F. Differential toxic effects of azathioprine, 6-mercaptopurine and 6-thioguanine on human hepatoc cytes. *Toxicology in Vitro*, 2009; 22 (3): 632- 643.
33. Kumar V, Cotran RS. and Robbins SL. *Basic Pathology* 7th ed. The Curtis Center . Independence Square West. Philadelphia, PA., 2003; 19106: 593
34. Poli G and parolia MO. Oxidative damage and fibrogenesis. *J. FreeRadic. Biol. Med.*, 1997; 22: 87-305.
35. Sakr SA, Hoda AM, and Hawazen AL. Protective effect of ginger (*Zingiber officinale*) on adriamycin - induced hepatotoxicity in albino rats. *Journal of Medicinal Plants Research*, 2011; 5 (1): 133-140.
36. Krishnakanta TP and Lokesh BR. Scavenging of superoxide anions by spice principles. *Indian Journal of Biochemistry and Biophysics*, 1993; 30: 133–134.
37. Brand-Williams W, Cuvelier M E. and Berset C. Use of a free radical method to evaluate antioxidant activity. *Lebensmittel-Wissenschaft und –Technologie.*, 1995; 28: 25–30.
38. Stoilova I, Krastanov A, Stoyanova A, Denev P. and Gargova S. Antioxidant activity of a ginger extract (*Zingiber officinale*). *Food Chemistry*, 2007; 102: 764–770.
39. Enas NM and Olfat AA. The protective effect of ginger extract on the adult male gonad of the albino rats treated with doxorubicin chemotherapy, 2009; *Sc.J.Az.Med.Fac.(Girls)*. 30 (3): 815-831

40. Zhou H, Deng Y. and Xie Q. The modulatory effects of the volatile oil of ginger on the cellular immune response in vitro and in vivo in mice. *J. of Ethnopharmacology*, 2006; 105: 301–305.
41. Nurtjahja-Tjendraputra E, Ammit AJ, Roufogalis BD, Tran VH. and Duke CC. Effective antiplatelet and COX-1 enzyme inhibitors from pungent constituents of ginger. *Thrombosis Res.*, 2003; 111: 259–265.
42. Jolad SD, Lantz RC, Solyom AM, Chen GJ, Bates RB. and Timmermann BN. Fresh organically grown ginger (*Zingiber officinale*): composition and effects on LPS-induced PGE2 production. *Phytochemistry*, 2004; 65 (13): 1937-1954.
43. Zeinab E. Hanafy. Cytogenetics Changes on Cancer Cells as Affected by Ginger Extracts. *Journal of American Science*, 2010; 6 (8).
44. Zeinab E. Hanafy. Ginger antimutagens as cancer chemopreventive agent against Ehrlich Ascites Carcinoma. *Academic J. of Cancer Research*, 2009; 2 (2): 61-67.
45. Bancroft JD and Steven SA. *Theory and practice of histological techniques.*(1996) .4thed.,Churchill Livingston,Edinburgh,London,p.184-193

4/26/2011