

The Ethmoidal Ganglion and its Anatomical Relations in Lacertilia (Squamata: Reptilia)

Ahmed Imam Dakrory* and Alaa El-Din Shamakh

Department of Zoology, Faculty of Science, Cairo University
*dakrory2001@yahoo.com

Abstract: The ethmoidal ganglion of three lizards belonging to three different families is described. Such ganglion is represented by one part in both *Uromastix aegyptus* (Family: Agamidae) and *Varanus griseus griseus* (Family: Varanidae) and by two parts in *Sphenops sepsoides* (Family: Lacertidae). In *Uromastix* and *Varanus* the ganglion lies on the ramus palatinus of the nervus facialis. In *Sphenops*, a small (ventral) part of the ganglion is located on the ramus palatinus while its main (dorsal) part is found on the anastomosing branch between the rami palatinus facialis and nasalis of the nervus trigeminus. In the present study, the ganglion is found at an anastomosing branch between the ramus palatinus of the nervus facialis and the ramus nasalis of the nervus trigeminus in *Sphenops*. In *Varanus* it is found where the ramus palatinus becomes very close to the ramus nasalis, whereas, in *Uromastix* the ganglion is located posterior to the origin of the anastomosing branch. [Ahmed Imam Dakrory and Alaa El-Din Shamakh, The Ethmoidal Ganglion and its Anatomical Relations in Lacertilia (Squamata: Reptilia)] Journal of American Science 2011; 7(8): 526-532. (ISSN: 1545-1003). <http://www.americanscience.org>.

Keywords: Ethmoidal ganglion – *Uromastix*, *Varanus* and *Sphenops*.

Introduction

The ethmoidal ganglion which have received various names (orbitonasalis, sphenothmoidal, sphenopalatine) from different authors is not found in all reptiles. It is regularly found in lizards and snakes and it is lacking in Chelonia and Crocodilia (Shiino, 1912 & 1914, Ogushi, 1913 a & b and Soliman, 1964).

In Reptilia, the ethmoidal ganglion is located at the place of anastomosis of the ramus nasalis of the nervus trigeminus and the ramus palatinus of the nervus facialis (Gaupp, 1888; Bellairs, 1949). Willard (1915) and Oelrich (1956) gave detailed study of the ganglion of *Anolis carolinensis* and *Ctenosaura* respectively. Soliman (1968) and Hegazy and Mostafa (1990) studied this ganglion in some lizards. Mostafa (1991) presented a study for the ganglion in three colubrid snakes.

It is obvious from the literature cited that, there is a little information about the structure, nature, position and the relations of the ethmoidal ganglion. In addition there are a few descriptive studies for the ethmoidal ganglion in relation to the great size of class Reptilia. So, the study of this subject is necessary both morphologically and phylogenetically.

2. Materials and Methods

Three lacertilian species belonging to three different families were chosen for this study; *Uromastix aegyptius* (Family: Agamidae), *Sphenops sepsoides* (Family: Lacertidae) and *Varanus griseus griseus* (Family: Varanidae).

Uromastix aegyptius is also known as spiny-tailed lizard or dabb lizard. This species inhabits

hard sand and gravel desert, preferring flat areas with light vegetation. It is primarily herbivorous, but occasionally eats young insects. It digs deep burrows in the hard soil usually with single entrance. It is a diurnal species spending most of its walking hours basking in the sun near burrow entrance especially at morning time. This species is adapted to the arid habitat. It is found throughout the North Africa, Middle east across south-central Asia and into India. Female dabb lizards can lay from 5 to 40 eggs. The eggs are laid (at July – August) approximately 30 days after copulation with an incubation time of 70-80 days.

The embryos of *Uromastix* of this study were collected from Gabal Al-Maghara about 80-90 km south of El-Arish city, Northern Sinai, as fertilized eggs during the last days of the incubation period (at August). After careful removing of the embryos from the shells, they were fixed very soon in an aqueous Bouin's fluid for 24 hours.

Sphenops sepsoides is a sand dwelling fossorial species with extremely reduced limbs for sand locomotion. It is found in a wide variety of habitats; ranging from depressions of Western desert to the sand spots in the rock wadies of the eastern desert and Sinai. It appears to be nocturnal and feeds entirely on fossorial insects (i.e., insectivore), this species is ovoviviparous.

The embryos of *Sphenops sepsoides* are collected from two pregnant females in the lab. The fully formed embryos were soon fixed in aqueous Bouin's fluid for 24 hours.

Varanus griseus griseus is a large diurnal lizard. It feeds on lizards, snakes, and rodents. This species lives in sandy areas throughout the Western and

Eastern deserts and Northern of Sinai. It is found in North Africa and Western Asia. The desert monitor lizard move in groups on searching for food.

Ten youngs (newly hatched) *Varanus* were collected from Romana territories at El-Arish city, Northern of Sinai. These young, after anaesthetizing, were fixed in aqueous Bouin's fluid for 36 hours.

After fixation, the specimens of both *Uromastix* and *Varanus* were passed into decalcificating EDTA solution for about 30 to 50 days. Then washed in distilled water and transferred to 70% ethyl alcohol for 48 hours. The embryos were embedded in paraffin wax then serially transversely sectioned at 10 μ m thickness in *Uromastix* and 15 μ m in both *Sphenops* and *Varanus*. The serial sections were then stained in Mallory's triple stain (Pantin, 1946) for *Uromastix* and *Varanus* and in haematoxylin and then counter stained with eosin for *Sphenops*.

The serial sections were drawn by the projector. From the projection the graphic reconstructions of the ciliary ganglion were made. Photomicrographs for parts of the transverse sections were provided to elucidate the position and relations of the ganglion to the other structures of the head.

3. Results

The microscopic investigation of the serial sections of the three lizards studied, *Uromastix aegyptius*, *Sphenops sepsoides* and *Varanus griseus griseus*, revealed the presence of the ethmoidal ganglion as a collection of ganglionic cells in the most anterior orbital (orbitonasal) region of the head. In both *Uromastix aegyptius* (Figs. 1 & 7, G.ET.) and *Varanus griseus griseus* (Figs. 2 & 4, G.ET.), the ganglion is represented by one part. However, in *Sphenops sepsoides*, it is formed of two parts (Figs. 3, 8 & 9, G.ET.DP. & G.ET.VP.).

In *Uromastix aegyptius*, the ethmoidal ganglion is elliptical in shape as it appears in the transverse serial sections (Figs. 1 & 7, G.ET.). It measures about 60 μ m in its length. In *Varanus griseus griseus*, it appears as an irregular mass of ganglionic cells, which measures about 252 μ m in its length (Figs. 4 & 5, G.ET.). In *Sphenops sepsoides*, however, the ethmoidal ganglion appears as two parts; one small and ventral (Figs. 3 & 9, G.ET.VP.) and the other large and dorsal (Figs. 3 & 8, G.ET.DP.). The ventral part measures about 60 μ m in its length. The dorsal part is large.

In both *Uromastix aegyptius* (Figs. 1 & 7) and *Varanus griseus griseus* (Figs. 2, 4 & 5), the ganglion lies totally along the course of the ramus palatinus of the nervus facialis. In *Uromastix aegyptius*, it lies shortly posterior to the origin of the anastomosing branch between ramus palatinus and the ramus nasalis of the nervus trigeminus (Figs. 1 & 6, R.CM.NA. + PAM.VII). The microscopic examination of the serial sections fails to find any

ganglionic cells either in the communicating branch or on the ramus nasalis. In *Varanus griseus griseus*, the ethmoidal ganglion (Figs. 2, 4 & 5) is found along the course of the palatine ramus, where it becomes closely applied to the ramus nasalis in the orbitonasal region of the head.

In *Sphenops sepsoides*, the lower or ventral part of the ganglion (Figs. 1 & 9, G.ET.VP.) lies along the ramus palatinus of the nervus facialis, whereas its dorsal part (Figs. 3 & 8, G.ET.DP.) lies along the communicating branch arising from the dorsal surface of the ventral part of the ganglion to anastomose with ramus nasalis (Figs. 3 & 8, R.CM.NA. + PA.VII).

Regarding the position of the ganglion in the three lizards studied, it has been found that, the ethmoidal ganglion is located in the most anterior orbital (orbitonasal) region of the head. In *Uromastix aegyptius* (Fig. 7) the ganglion lies dorsal to the vomer bone (V) and ventrolateral to the inferior oblique muscle of the eye (M.OIF.). In *Varanus griseus griseus* (Fig. 4). The ganglion is located dorsal to the planum anteorbitale (PAOR.), ventral and ventromedial to both the ramus nasalis (R.NA.V) and the fenestra olfactoria evehens (F.OL.EV.) and medial to the orbital sinus (OR.SI.). In *Sphenops sepsoides* (Figs. 8 & 9), it is located ventral to the taenia marginalis anterior (TMA.), ventromedial to the ramus nasalis (R.NA.V), dorsomedial to the planum anteorbitale (PAOR.) and lateral to the interorbital septum (IOR.S.).

4. Discussion

In the three species studied, a well developed ethmoidal ganglion is found at an anastomosis between the ramus palatinus of the nervus facialis and ramus nasalis of the nervus trigeminus in the orbitonasal region in both *Varanus griseus griseus* and *Sphenops sepsoides*. In *Uromastix aegyptius*, it is located shortly posterior to the origin of the anastomosing branch. The ganglion gives off a dorsal anastomosing branch which connects with the ramus nasalis of the nervus trigeminus in *Sphenops sepsoides*, whereas in *Varanus griseus griseus* the ramus palatinus extends closely applied to the ramus nasalis at the position of the ganglion along the former ramus. It is composed of a single part which is closely applied to the ramus palatinus of the nervus facialis in both *Uromastix aegyptius* and *Varanus griseus griseus*, while in *Sphenops sepsoides*, it is composed of two parts one ventral applied to the ramus palatinus and a dorsal one found on the anastomosing branch. The result observed in both *Uromastix* and *Varanus* is similar to what was described by Soliman (1968) in *Mabuya quinquetaeniata*, Hegazy and Mostafa (1990) in *Agama sinaita* and by Dakrory (1994) in the amphibaenian *Diplometopon zarudnyi*. The same

condition was also observed in the snakes *Cerastes vipera* (Hegazy, 1976), *Spaleosophis diadema* (Mostafa, 1990 and 1991) and in *Natrix tessellate* (Dakrory and Mahgoub, 2004).

The location of the ethmoidal ganglion in *Varanus griseus* is typical to that observed by Watkinson (1906) in *Varanus bivittatus*. In this respect, the location of the ethmoidal ganglion, wherever, shows a wide variation in Lacertilia. In this study, the ganglion in question, is closely applied to the ramus palatinus in *Uromastyx aegyptius* and *Varanus griseus griseus*. The ganglion is closely related to the ramus nasalis, and it is in connection with the medial palatine ramus in *Anolis carolinensis* (Willard, 1915), *Lacerta viridis*, *Ptyodactylus hasselquistii* and *Acanthodactylus boskiana* (Soliman, 1968), *Chalcides ocellatus* (Soliman and Hegazy, 1969), *Stenodactylus slevini* (Hegazy and Mostafa, 1990) and *Acanthodactylus ophiodurus* (Mostafa, 1990). On the other hand, the ganglion is found in the middle of the anastomosing branch which connects the rami nasalis and medial palatine in *Ctenosaura pectinata* (Oelrich, 1956), *Agama mutabilis* (Soliman, 1968) and *Eumeces schneiderii* (Hegazy and Mostafa, 1990). In the Ophidia, the ganglion is composed of one part that is closely applied to the ramus palatinus in *Natrix tessellate* (Dakrory and Mahgoub, 2004).

The condition found in *Sphenops sepsoides* studied was observed in many lizards and snakes but with slight disagreement, as they have been studied. Between the two parts of the ganglion is found a communicating branch. In *Tarentola mauritanica* (Soliman and Mostafa, 1984) and *Ptyodactylus hasselquistii* (Abdel-Kader, 1990), one part of the ganglion is closely applied to the ramus nasalis, whereas the other part is close to the medial palatine ramus. In *Agama pallida* (Abdel-Kader, 1990); one part of the ganglion is close to the medial palatine ramus and the other lies at the middle of the anastomosing branch.

Concerning the matter in snakes, the two parts of the ganglion are closely applied to the medial palatine ramus in *Psammophis sibilans* (Hegazy, 1976) and in *Coluber elegantissimus* (Mostafa, 1991). In *Eryx jaculus* (Hegazy, 1976), one part is applied to the ramus nasalis and the other to the medial palatine ramus. In *Psammophis schokari* (Mostafa, 1991) one part is entirely located in the medial palatine ramus and the other on the communicating branch.

Apart from Squamata, the ganglion ethmoidale, on the other hand, has not been found in Chelonia (Shiino, 1912; Ogushi, 1913 a & b; Soliman, 1964). Similarly, in Crocodylia; Shiino (1914) neglects any sort of connection between the rami palatinus and nasalis anteriorly in the orbital region and hence mentioned nothing about the ganglion.

In Amphibia, early works of Coghill (1902) and Norris (1908) show the presence of the ethmoidal ganglion in *Amblystoma tigrinum* and *Amphiuma means*, respectively. Again, the anastomosis between the ramus ophthalmicus profundus of the nervus trigeminus and the ramus palatinus of the nervus facialis was found in *Salamandra maculosa* (Gaupp, 1888); *Amblystoma punctatum* (Herrick, 1894), *Siren lacertian* (Norris, 1913) and in *Xanopus laevis* (Paterson, 1939).

In birds, an anastomosis between the ramus ophthalmicus profundus of the nervus trigeminus and the ramus palatinus of the nervus facialis was described by Cords (1904) and Haler von Hallerstein (1934). Stresemann (1927) described the ethmoidal ganglion in birds, he recorded its lacking in *Struthio*. Soliman *et al.* (1986) described the so called sphenopalatine ganglion from *Passer domesticus*, *Upupa epops* major and *Streptopelia senegalensis aegyptiaca*.

In Pisces; Freihofer (1978), Dakrory (2000) and Ali and Dakrory (2008) neglected completely the presence of this ganglion.

Regarding the function of the ethmoidal ganglion, Stresemann (1927) mentioned that there is an exchange of fibres between the ramus palatinus of the nervus facialis and both the nervus glossopharyngeus and the parasympathetic nerves, and that the ganglion ethmoidale is formed in the region of exchange of fibres. Norris (1908) stated that there seems to be a ganglion on the ramus palatinus shortly before the anastomosis. Beyond the anastomosis, he found mixed cutaneous and viscerosensory rami. Such observation agrees with that of Willard (1915) which shows that the ganglion ethmoidale is more closely related to the ramus palatinus of the nervus facialis.

As to the nature of the ethmoidal ganglion, Carpenter (1906) gave evidence about its sympathetic character. Again Willard (1915) on his dissection of this ganglion and its connections in *Anolis carolinensis* showed that it has to do largely with non-medullated fibres, and that the nature of its cells shows its sympathetic character.

From the above mentioned discussion, the authors can conclude that, in many features, the ethmoidal ganglion on Lacertilia is parallel to Ophidia. This suggests that theory of considering the Squamata (Lacertilia and Ophidia) as modern advanced reptiles, whereas representatives of the Chelonia occupy an early side branch of the stem Reptilia. Moreover, the phylogenetic variation of the ganglion ethmoidale in vertebrates suggests that the lizards (Squamata) stand half-way between the fishes and Amphibia from one side and the Aves from the other side, as to its evolution.

Corresponding author

Ahmed Imam Dakrory
Department of Zoology, Faculty of Science, Cairo University
dakrory2001@yahoo.com

References

- Abdel-Kader, I.Y. (1990): Anatomical studies on the cranial nerves of the lizards *Agama pallida* and *Ptyodactylus hasselquistii*. Ph.D. Thesis, Fac. Sci., Cairo Univ., Egypt.)
- Ali, R.S. and Dakrory, A.I. (2008): Anatomical studies on the cranial nerves of *Alticus kirkii magnosi*. 1- The eye muscle nerves and ciliary ganglion. *Egypt. J. Zool.*, 51: 113-132.
- Bellairs, A.D'A. (1949): Observation on the snout of *Varanus* and a comparison with that of other lizards and snakes. *J. Anat. Lond.*, 83(2): 116-146.
- Carpenter, F. W. (1906): The development of the oculomotor nerve, the ciliary ganglion, and the abducens nerve in the chick. *Bull. Mus. Comp. Zool.*, 48: 139-230.
- Coghill, G. E.(1902): The cranial nerves of *Amblystoma tigrinum*. *J. Comp. Neurol.*, 12: 205-289.
- Cords, E. (1904): Beiträge zur Lehre vom Kopfnerven-System der Vögel. *Anat. Hefte.*, 26: 49-100.
- Dakrory, A. I. (1994): Anatomical studies on the cranial nerves of the Amphisbaenian (*Diplometopon zarudnyi*). M.Sc. Thesis, Fac. Sci. Cairo Univ. Egypt.
- Dakrory, A. I. (2000): Comparative anatomical studies on the cranial nerves of *Rhinobatus halavi* (Class: Chondrichthyes) and *Ctenopharyngodon idellus* (Class: Osteichthyes). Ph.D. Thesis, Fac. Sci., Cairo Univ., Egypt.
- Dakrory, A.I. and El-Mahgoub, A. F. (2004): The cranial nerves of *Natrix tessallata* (Ophidia: Colubridae). The nervus facialis. *J. Union Arab. Biol. Cairo*, 22(A): 273-289.
- Freihofer, W. C. (1978): Cranial nerves of a percoid fish, *Polycentrus schomburgkii* (Family: Nandidae), a contribution to the morphology and classification of the order Perciformes. *Occ. Pap. Calif. Acad. Sci.*, 128: 1-75.
- Gaupp, E. (1888): Anatomische Untersuchungen über die Nervenversorgung der Mund-und Nasenhöhlendrüsen der Wirbeltiere. *J. Morph.*, 14: 436-489.
- Haller Von Hallerstein V (1934): Anatomie der Wirbeltiere 2/1, herausgegeben von Bolk, Göppert, Kallius, Lubosch. Berlin und Wien
- Hegazy, M. A. (1976): Comparative Anatomical studies on the cranial nerves of Ophidia. Ph.D. Thesis, Fac. Sci., Cairo Univ. Egypt.
- Hegazy, M. A. and Mostafa, R. H. (1990): Study of the ganglion ethmoidale in three species of lizards. *Proc. Egypt. Acad. Sci.*, 40: 147-152.
- Herrick, C. J. (1894): The cranial nerves of *Amblystoma punctatum*. *J. Comp. Neurol.*, 4: 193-207.
- Mostafa, R. H. (1990): The cranial nerves of serpent, *Spalerosophis diadema*. III. The nervus facialis. *Egypt J. Anat.*, 13 (2): 107-119.
- Mostafa, R. H. (1991): The ethmoidal ganglion and its relations in Ophidia (Squamata: Reptilia). *Proc. Egypt. Acad. Sci.*, 41: 107-117.
- Norris, H. W. (1908): The cranial nerves of *Amphiuma means*. *J. Comp. Neurol.*, 18: 527-568.
- Norris, H. W. (1913): Cranial nerves of *Siren lacertina*. *J. Morph.*, 24(2): 245-338.
- Oelrich, T. H. (1956): The anatomy of the head of *Ctenosaura pectinata* (Iguanidae). *Misc. Publ. Mus. Zool. Michigan*, 94: 9-122.
- Ogushi, K. C. (1913a): Zur Anatomie der Hirnnerven und des Kopfsympathicus von *Trionyx japonicus* nebst einigen kritischen Bemerkungen. *J. Morph.*, 45: 441-481.
- Ogushi, K. C.(1913b): Anatomische Studien an der japanischen dreikralligen Lippenschildkröte (*Trionyx japonicus*). *J. Morph.*, 46: 299-562.
- Pantin, C. F. A. (1946): Notes on microscopical technique for Zoologists. Cambridge, England: Cambridge, University Press.
- Paterson NF (1939): The head of *Xenopus laevis*. *Q. J. Micr. Sci.*, 81(II): 161-234.
- Shiino, K. (1912): Beiträge zur Kenntnis der Gehirnnerven der Schildkröten. *Anat. Hefte*, 47: 1-37.
- Shiino, K. (1914): Studien zur Kenntnis der Wirbeltierkopfes. I. Das Chondrocranium von *Crocodylus* mit Berücksichtigung der Gehirnnerven und der Kopfgefäße. *Anat. Hefte.*, 50: 253-382.
- Soliman, M. A. (1964): Die Kopfnerven der Schildkröten. *Z. F. W. Zool.*, 169: 215-312.
- Soliman MA (1968): On the ganglion ethmoidale (Orbitonasale) of lizards. *Bull. Fac. Sci., Cairo Univ.*, 42: 131-139.
- Soliman MA and Hegazy MA (1969): The cranial nerves of *Chalcides ocellatus*. II. The nervus trigeminus. *Bull. Fac. Sci. Cairo Univ.*, 43: 63-90.
- Soliman, M.A. and Mostafa, R. H. (1984): A detailed study on the cranial nerves of the gecko *Tarentola mauritanica*. III. Nervus facialis. *Proc. Zool. Soc., A.R.E., VII*: 311-331.
- Soliman, M.A. ; Mostafa, R.H. and Abdel-Kader, I. Y. (1986): The cranial nerves of Birds. II. The nervus Facialis. *Proc. Zool. Soc. A.R.E.*, 11: 407-426.
- Stresemann, E. (1927): Aves. In Kükenthal's Handbuch der Zoologie–Berlin-Leipzig.
- Watkinson, G. B. (1906): The cranial nerves of *Varanus bivittatus*. *J. Morph.*, 35: 450-472.
- Willard, W. A. (1915): The cranial nerves of *Anolis carolinensis*. *Bull. Mus. Comp. Zool.*, 59: 17-116.

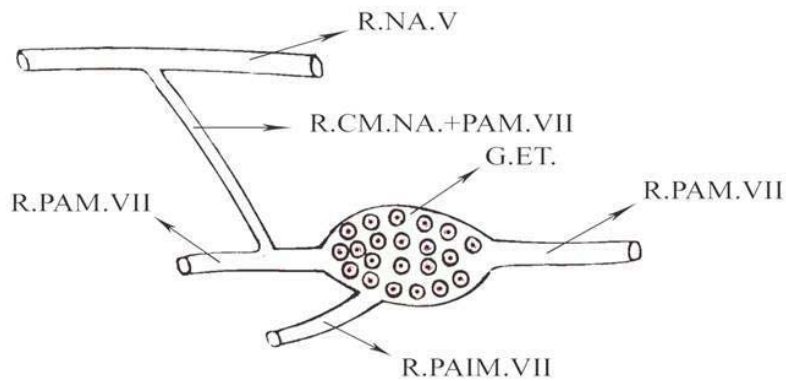


Fig. 1: Graphic reconstruction of the ethmoidal ganglion of *Uromastix aegyptius* in a lateral view. G.E.T., Ethmoidal ganglion, R.CM.NA.+ PA.VII, Ramus communicans between the ramus nasalis of the nervus trigeminus and the ramus palatines, R.NA.V, Ramus nasalis of the nervus trigeminus, R.PAIM.VII, Ramus palatinus intermedialis of the nervus facialis, R.PAM.VII, Ramus palatinus medialis of the nervus facialis.

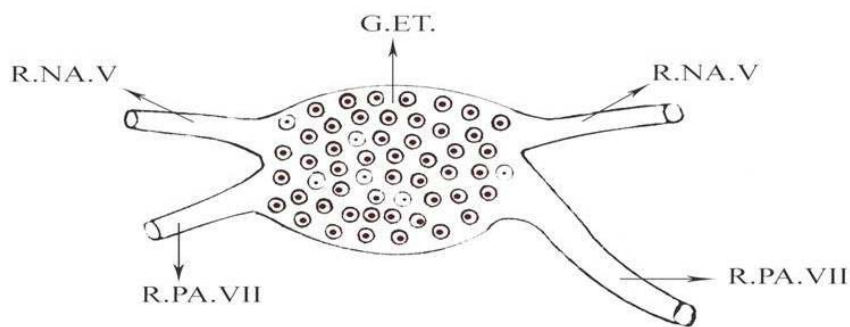


Fig. 2: Graphic reconstruction of the ethmoidal ganglion of *Varanus griseus* in a lateral view. G.E.T., Ethmoidal ganglion, R.NA.V, Ramus nasalis of the nervus trigeminus, R.PA.VII, Ramus palatinus of the nervus facialis.

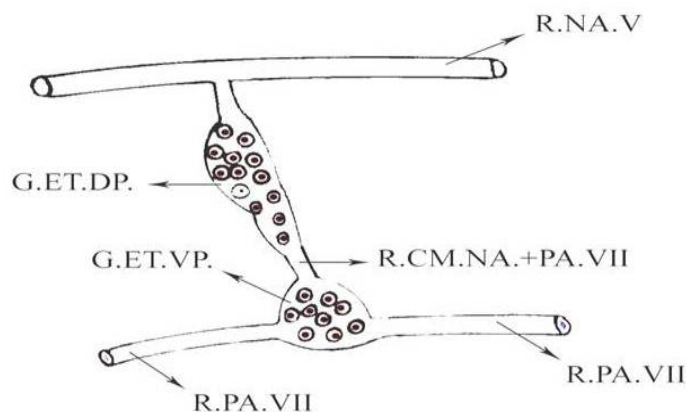


Fig. 3: Graphic reconstruction of the ethmoidal ganglion of *Sphenopus sepsoides* in a lateral view. G.ET.DP., Dorsal part of the ethmoidal ganglion, G.ET.VP., Ventral part of the ethmoidal ganglion, X40. R.CM.NA.+ PA.VII, Ramus communicans between the ramus nasalis of the nervus trigeminus and the ramus palatinus R.NA.V, Ramus nasalis of the nervus trigeminus, R.PA.VII, Ramus palatinus of the nervus facialis

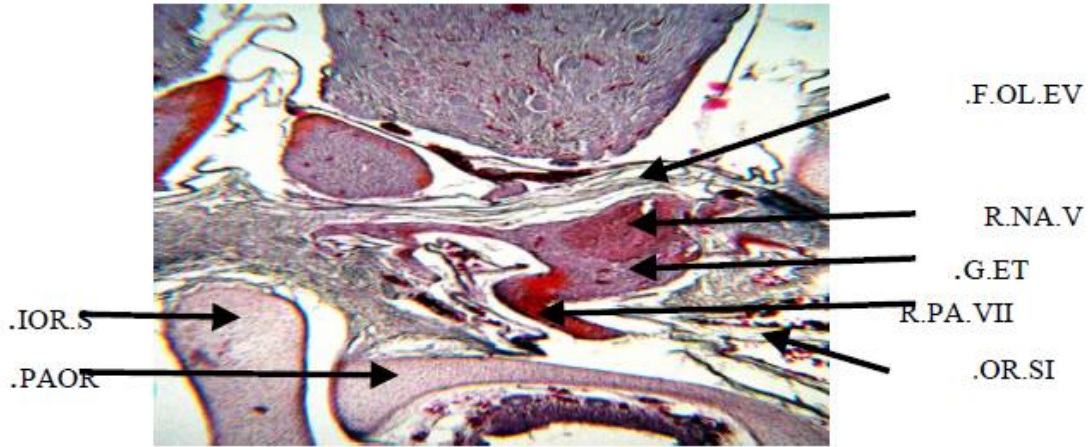


Fig. 4: A photomicrograph of a part of transverse section of *Varanus griseus gresius* showing the position of the ethmoidal ganglion. X40. F.OL.EV., Foramen olfactorium evehens, G.ET., Ethmoidal ganglion, IOR.S., Interorbital septum, OR.SI., Orbital sinus, PAOR., Planum anteorbitale, R.NA.V, Ramus nasalis of the nervus trigeminus, R.PA.VII, Ramus palatinus of the nervus facialis.

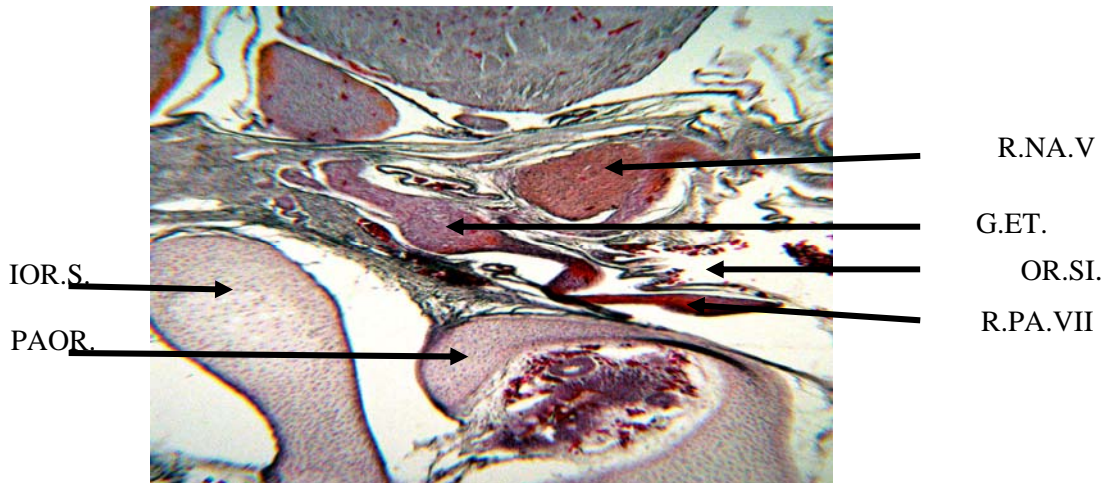


Fig. 5: A photomicrograph of a part of transverse section of *Varanus griseus gresius* showing the relation of the ethmoidal ganglion to both the rami palatinus facialis and nasalis of the nervus trigeminus. X40. G.ET., Ethmoidal ganglion, IOR.S., Interorbital septum, OR.SI., Orbital sinus, PAOR., Planum anteorbitale, R.NA.V, Ramus nasalis of the nervus trigeminus, R.PA.VII, Ramus palatinus of the nervus facialis.

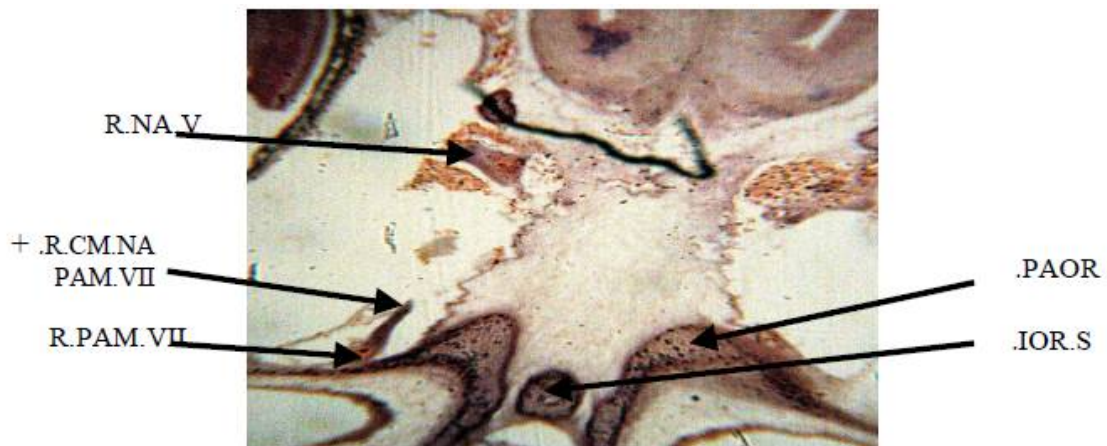


Fig. 6: A photomicrograph of a part of transverse section of *Uromastix aegyptius* demonstrating the origin of the ramus communicans between the ramus palatinus medialis of the nervus facialis and the ramus nasalis of the nervus trigeminus. X40. IOR.S., Interorbital septum, OR.SI., PAOR., Planum anteorbitale, R.CM.NA.+ PAM.VII, Ramus communicans between the ramus nasalis the nervus trigeminus and the ramus palatinus medialis, R.NA.V, Ramus nasalis of the nervus trigeminus, R.PAM.VII, Ramus palatinus medialis of the nervus facialis.

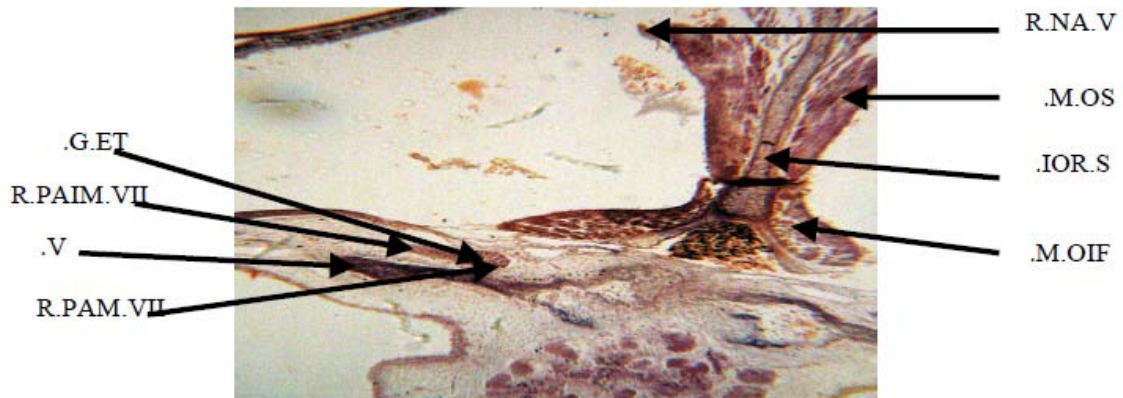


Fig. 7: A photomicrograph of a part of transverse section of *Uromastix aegyptius* illustrating the position of the ethmoidal ganglion and the origin of the ramus palatinus intermedius of the nervus facialis. X40. G.ET., Ethmoidal ganglion, I.O.R.S., Interorbital septum, M.O.I.F., Inferior oblique muscle, M.O.S., Superior oblique muscle, R.NA.V, Ramus nasalis of the nervus trigeminus, R.PAIM.VII, Ramus palatinus intermedius of the nervus facialis, R.PAM.VII, Ramus palatinus medialis of the nervus facialis. V., Prevomer.

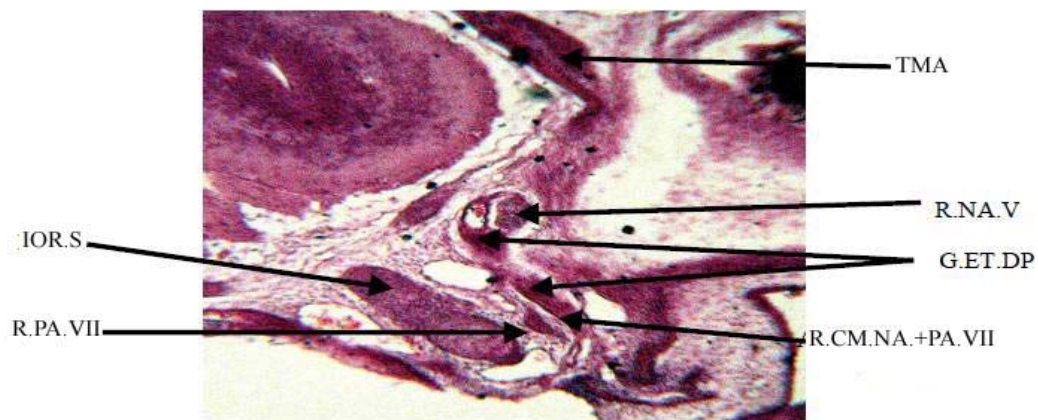


Fig. 8: A photomicrograph of a part of transverse section of *Sphenops sepsoids* showing the position of the dorsal part of the ethmoidal ganglion and the ramus nasalis of the versus trigeminus. X40. G.ET.DP., Dorsal part of the ethmoidal ganglion, I.O.R.S., Interorbital septum, R.CM.NA.+ PA.VII, Ramus communicans between the ramus nasalis of the nervus trigeminus and the ramus palatines, R.NA.V, Ramus nasalis of the nervus trigeminus, R.PA.VII, Ramus palatinus of the nervus facialis, TMA., Taenia marginalis anterior.

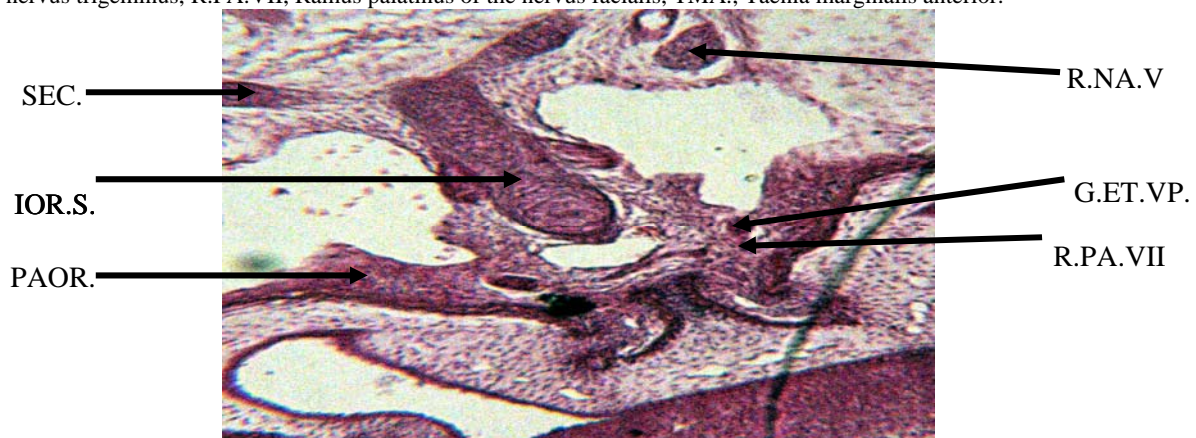


Fig. 9: A photomicrograph of a part of transverse section of *Sphenops sepsoids* demonstrating the position of the ventral part of the ethmoidal ganglion and the ramus palatinus of the nervus facialis. X100. G.ET.VP., Ventral part of the ethmoidal ganglion, I.O.R.S., Interorbital septum, PAOR., Planum anteorbitale, R.NA.V, Ramus nasalis of the nervus trigeminus, R.PA.VII, Ramus palatinus of the nervus facialis, SEC., Sphenothmoidal commissure.