

MORBIDITY AFTER CHIN GRAFT HARVESTING USING PIEZOSURGERY VERSUS CONVENTIONAL OSTEOTOMY TECHNIQUES

Gamal M. Moutamed

Department of Oral and Maxillofacial Surgery, Faculty of Oral and Dental Medicine, Cairo University, Egypt
Corresponding author: gamalmoutamed@yahoo.com

ABSTRACT: Augmentation of the resorbed site using chin bone graft is a common method. However, it involves donor site morbidity. Chin graft morbidity involves impaired sensibility in the mandibular anterior teeth, the gingival and chin-lower lip area postoperatively. The aim of this study was to investigate the morbidity at the donor site following harvest of chin bone using piezosurgery versus conventional bone cutting tools. In addition, distances between the bone harvest defect and anatomical structures such as apices of lower anterior, premolars and mental foramina were analyzed. A group of 20 patients (16 men and 4 women) who had undergone chin bone harvesting for alveolar ridge augmentation or sinus floor elevation procedures were selected. Patients were equally divided into two groups according to the cutting tools used for chin graft harvesting. Group I (*piezosurgery group*); piezosurgery was used for chin graft harvesting. Group II (*conventional group*); conventional cutting tools used for chin graft harvesting. The true distances between the donor defect and the apices of the adjacent mandibular teeth were measured on a digital panoramic radiograph. The distance from the lateral margins of the donor defect to the right and left mental foramina (RMF and LMF) was recorded. Sensibility of the lip, teeth, and gingiva was registered one week, one, three, six and 12 months post-operatively. A total of six (30%) patients experienced anaesthesia of the gingivae immediately postoperatively and had full recovery when reviewed at 3 month follow up. Three (15%) of these patients experienced paraesthesia of the chin and lower lip, however full recovery had occurred at the 6-month follow-up. None of the patients reported altered contour or change in profile of the chin area as well as dehiscence of the incision. Three patients experienced pain at the graft site for up to three months postoperatively. Nine patients showed a negative pulp sensitivity reaction in their lower teeth to ethyl chloride at one week postoperatively; this further improved to 5 patients at the 6-month follow-up and to 2 patients at the 12-month follow-up. Parameters comparisons between both piezosurgery and conventional groups showed no statistically significant difference. However, parameters comparisons across each group showed statistically significant difference between different parameters in teeth with and without negative response to thermal pulp testing regarding mean volume of the chin bone defect (P-value < 0.001), mean distance of the defect to mental foramen of both sides (P-value < 0.05). In conclusion, this study indicated that chin graft donor site showed some post-operative morbidity. The most frequent disturbance was impaired teeth sensibility. The lower lip and chin region showed fewer disturbances. However, by correctly placing mucoperiosteal incisions and bone cuts, the risk of sensitivity changes can be minimized. Surgical control for the piezosurgery was easier than conventional methods for mobilizing a chin bone block graft. The force necessary to produce a cut was much less compared to rotational burs. Increased temperature during bone cutting with piezosurgery was avoided which reduces the risk of bone damage as a result of overheating.

[Gamal M. Moutamed. **MORBIDITY AFTER CHIN GRAFT HARVESTING USING PIEZOSURGERY VERSUS CONVENTIONAL OSTEOTOMY TECHNIQUES.** Journal of American Science 2011;7(8):641-652]. (ISSN: 1545-1003). <http://www.americanscience.org>.

KEY WORDS: autogenous bone, chin bone graft, morbidity, piezosurgery, bone augmentations, sinus floor elevation

1. INTRODUCTION

In some patients implant treatment would not be possible without bone augmentation because of insufficient bone volume at the planned implant site. A well-documented surgical procedure for ridge augmentation comprises the application of a block graft, either with membrane coverage (guided bone regeneration), Buser et al., (1996); Antoun et al., (2001); Raghoobar et al., (2007) or without membrane therapy, Raghoobar et al., (1996); Widmark et al., (1997); Sethi, and Kaus (2001);

McCarthy et al., (2003a). In sinus floor elevation procedures, autogenous bone particles with or without bone substitutes are used to optimize the bone volume prior to or in conjunction with implant placement, Lorenzetti et al., (1998); Yildirim et al., (2001); McCarthy et al., (2003b); Merckx et al., (2003).

Autogenous bone grafts are available from extra and intra-oral donor sites, Tolman (1995); Misch (1997). Extra-oral donor sites include iliac crest, calvarium, tibia, ribs and intra-oral sites include

maxilla, mandible and zygoma. The choice of donor site is dependent upon the quantity and quality of bone required, access to the donor site and time required for bone harvesting procedures, Misch et al., (1992); Raghoobar et al., (1996); Misch (1997). The mandibular symphysis is a favourable donor site because it is generally assumed that it has an excellent risk-benefit ratio, Triplett and Sihow (1998). Convenient surgical access, proximity of donor and recipient sites, low morbidity, and availability of larger quantities of bone over other donor sites, benefit of using intra-membranous bone versus endochondral bone, embryonic origin means early vascularisation and minimal resorption, minimal patient concern for altered facial contour and minimal discomfort are some advantages of this procedure over other intraoral sites, Gapski et al.,(2001);Joshi(2004).

Following harvesting of symphysis bone grafts, some neurosensory disturbances as altered sensation and sensitivity of lower anterior teeth and intra oral scarring have been described, Nkenke et al., (2001); Raghoobar et al., (2001); Joshi (2004); Von Arx et al.,(2005). In a prospective study evaluating intraoral donor sites for bone grafting, it was reported that 29% of symphysis graft patients had altered sensitivity of their mandibular incisor teeth. All findings were resolved within six months, Misch (1997).

Common techniques to evaluate post harvesting sequelae include pulp sensitivity test using carbon dioxide (CO₂) snow, Nkenke et al.,(2001);Von Arx et al.,(2005) and ethyl chloride sprayed onto a small cotton wool pledget, Joshi (2004) and skin sensitivity examinations such as pointed-blunt discrimination, two-point discrimination, Nkenke et al.,(2001);Von Arx et al.,(2005) and fine touch using graded suture material, Blackburn (1990); Joshi(2004) and assessment of pain using the pin-prick sensation, Mason (1988).

When using conventional bone cutting instruments such as reciprocating micro-saws, surgical burs, or trephines, there is a risk of postoperative necrosis. Comparative histological studies have shown necrosis on cut bone caused by surgical burs, trephines and micro-saws, Aro et al., (1981). Over the past eight years, piezosurgery (PS) or piezoelectric surgery (PES) has been introduced as a new technique for osteotomy and osteoplasty using ultrasonic micro-vibration. The piezosurgery blades allow for maximum intra-operative precision, minimal tissue damage, and the selective frequency of the scalpel minimizes the risk to adjacent soft tissues, Eggers et al. (2004). Ideally to cut soft tissue a frequency of 50 KHz is needed whereas

Piezosurgery® device uses a frequency of 25-30 KHz at which only bone is cut. The device when used as recommended would not cut nerves, periosteum or the Schneiderian membrane, Stübinger et al., (2005); Schlee et al., (2006).

Moreover, a study conducted on a series of 100 consecutive cases to evaluate and monitor Schneiderian membrane perforation rate during sinus elevation using PS. The result of such study showed that the sinus membrane perforation rate using PS was decreased from 30% with rotary instrumentation to 7%, Wallace et al., (2007). The low pressure applied to the instrument enables a precise cut, and the selective cut characteristically protects the sinus membrane in sinus floor elevations, Barone et al., (2008). In the lower jaw, PS has been successfully used to mobilize the inferior alveolar nerve, Sakkas et al., (2008). Histological studies conducted with Sohn et al., (2004), Chiriac et al., (2005) and Happe (2007), showed minimal cellular damage to the resected bone margins, bony matrix and underlying marrow spaces. Another study conducted with Vercellotti et al., (2005) reported that PS provided more favourable osseous repair and remodelling than with conventional surgical burs with surgical osteotomy and osteoplasty procedures.

Therefore, the aim of this study was to investigate the morbidity at the donor site following chin bone harvesting using piezosurgery versus conventional bone cutting techniques. In addition, distances between the bone harvest defect and anatomical structures; apices of lower anterior and premolar teeth and mental foramina of both sides were analyzed.

2. MATERIALS AND METHODS

2.1. Materials:

2.1.1. Subjects:

Twenty patients scheduled for chin bone harvesting for alveolar ridge augmentation or sinus floor elevation procedures were selected for the current study. Indications for bone harvesting included lateral ridge augmentation in 9 patients and sinus floor elevation in 11 patients. The patients were selected from the Outpatient Clinic, Department of Oral and Maxillofacial Surgery, Faculty of Oral and Dental Medicine, Cairo University, Cairo, Egypt. Sixteen patients were males and 4 were females. The average age was 41 years (range 30 -55 years). Patients signed informed consent documents after they had been fully notified about the surgical procedures. All surgeries were performed under general anesthesia.

Basic evaluation included medical history, smoking habit, extra-oral and intra-oral examination, and radiographic investigation. As a first step, the recipient site was analyzed to determine the amount of autogenous bone to be harvested from the symphysis. The mandibular symphysis area was preoperatively estimated on a panoramic radiograph to be sufficient in height for bone harvesting. Pulp sensitivity of mandibular incisors/canines/first premolars teeth were preoperatively assessed by recording the response of these teeth on cold sensation using a spherical dental cotton on which an ethyl chloride vapour was sprayed, Raghoobar et al.,(1990).

The selected patients were equally divided into two groups according to the bone cutting tools used for chin graft harvesting. *Group I (piezosurgery group)*; piezosurgery was used for chin graft harvesting. *Group II (conventional group)*; conventional bone cutting surgical fissure burs used for chin graft harvesting.

2.2. Methods:

2.2.1. Surgical procedure

With the lip drawn anteriorly, the soft tissues were placed under tension and the incision was made in two layers, firstly through mucosa and then through the muscle and periosteal layers. A full thickness mucosal flap was raised following a vestibular incision in the inter-canine region 5 mm below the muco-gingival junction. Periosteal elevation is performed to the inferior border of the mandible to expose the symphysis. Caution was exercised to avoid the branches of the mental nerve. The mental foramina were not exposed. The location of the apices of lower incisors and canines were estimated from the panoramic radiograph. The length of the tooth was transferred to the clinical situation using a periodontal probe. After the apices of the lower incisors and canines were identified, the initial horizontal cut into the bone was made 5mm apical to the apices of the incisors, Von Arx et al.,(2005). The surface outline of the bone block was completed with a small round bur. The aim was to harvest a cortico-cancellous bone block. The lower margin of the mandible was always preserved to avoid changes in the chin contour, Nkenke et al., (2001).

In group I (*piezosurgery group*), the osseous cuts were made with the piezosurgery inserts (*VarioSurg, NSK, Japan*). Copious isotonic saline irrigant was used to counter heat generation produced by the blade inserts. Osteotomies started using the VarioSurg Multiple impacts SG4 or SG1 insert and then performing the vestibular corticotomies using VarioSurg Multiple impacts SG1 and SG8 inserts.

Osteotomy to the deep surface of the cortico-cancellous chin bone block using the double elbow-shaped VarioSurg Multiple impacts SG 14R and SG 14L inserts (Figure 1).

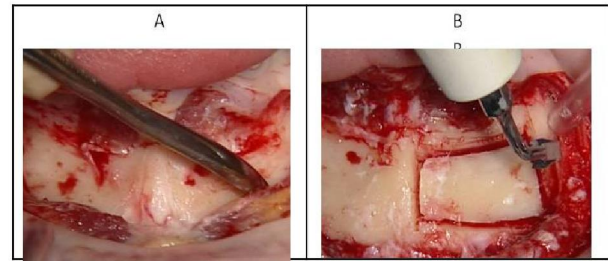


Figure (1): Photographs showing chin bone harvesting in group I (*piezosurgery group*). A) A full thickness flap was raised following a vestibular incision in the inter-canine region 5 mm below the muco-gingival junction and B) The osseous cuts were made and completed with the piezosurgery inserts.

A check was made to ensure that the cut was through the cortical bone and into the cancellous bone. The cortico-cancellous block was then carefully mobilized using a curved bone chisel. Further cancellous bone chips were harvested from the chin with curettes or curved chisels, but the lingual cortex of the symphysis was never perforated.

In group II (*conventional group*), the osseous cuts were made with a surgical fissure burs under copious irrigation with saline. A cortico-cancellous bone block was harvested with the aid of a 3 mm osteotome (*Frios Kit for bone grafting, Frident, USA*) which was tapped into the outlined area with a mallet (Figures 2 and 3). The surgical assistant provided support to the chin during the tapping phase. Further cancellous bone was harvested with curettes or curved chisels, but the lingual cortex of the symphysis was never perforated.

Then, the harvested bone was preserved in cold saline solution (4°C), prepared for ridge augmentation or further chipped using a bone mill for sinus floor elevation procedures (Figure 4).

The donor site was packed with saline soaked gauze. The bone defect of the donor site was registered with three-dimensional measurements, using a caliper (width W= mesio/ distal dimension, height H= apico/coronal dimension, depth D= oro/facial dimension). Prior to soft tissue closure of the mandibular donor site, the area was copiously irrigated with saline. A gelatin sponge was applied into the donor area as a haemostatic dressing.

The chin wound was then sutured in two layers. First the mentalis was sutured with internal interrupted sutures and then the overlying mucosa was closed with a 5/0 resorbable suture. A pressure dressing (elastic tape) was applied to the chin and maintained for 5 days to minimize postoperative

swelling and formation of a hematoma. Postoperative medication included antibiotics; Augmentin, 1gm/12 hours for 6 days (875mg amoxicillin and 125 mg clavulanate potassium, GlaxoSmithKline S.A.E, El Salam city, Cairo, Egypt), analgesics; Declofenac Potassium 50 mg/ 8 hours (Cataflam, produced by novartis pharma, Cairo, Egypt), and 0.2% chlorahexidine gluconate mouth rinse, 3 times/day (Hexitol mouth wash, Arab drug Co. Cairo, Egypt) for the next 10 postoperative days.

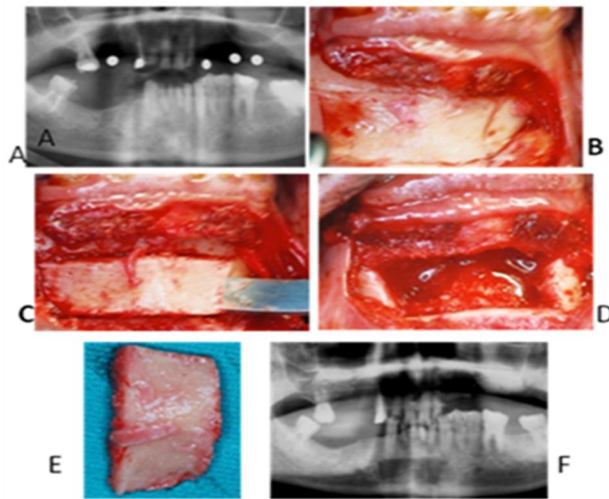


Figure (2): Photographs showing one case of chin bone harvesting in group II (conventional group). A) Preoperative panoramic radiograph, B) the bone block was outlined with a small round bur, C) the osseous cuts were completed with osteotome, D) Bone defect after chin bone harvesting, E) the harvested cortico-cancellous bone block and F) Size of bone defect after chin bone harvesting were seen in postoperative panoramic radiograph.

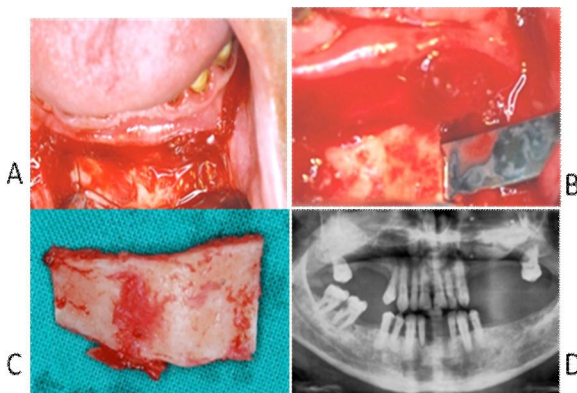


Figure (3): Photographs showing another case of chin bone harvesting in group II (conventional group). A) A full thickness flap was raised following a vestibular incision in the inter-canine region and the bone block was outlined and the osseous cuts were completed with osteotome, C) the harvested cortico-cancellous bone block and D) the resulting bone defect after chin bone harvesting were seen in postoperative panoramic radiograph.

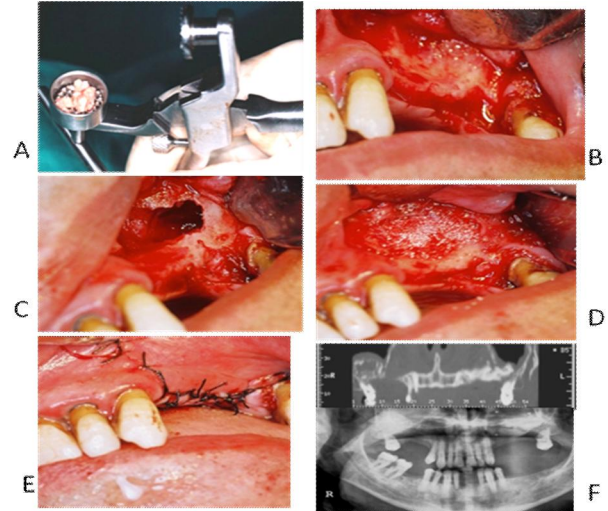


Figure (4): Photographs showing a case of sinus floor elevation, A) the harvested cortico-cancellous chin bone block was chipped using a bone mill, B) A full thickness flap was raised, C) Prepared lateral window for sinus floor elevation, D) elevated sinus floor packed with the chipped bone, E) closure of the flap, and F) grafted maxillary sinus were seen in postoperative CT scan (Dentascan) and panoramic radiograph.

2.2.2. Post-operative evaluation

All the patients were examined pre-operatively and one week, one, three, six and 12 months post-operatively. One week postoperative, the donor site was examined for the contour of the chin and lower lip. Pulp sensitivity testing was done by recording the response of the mandibular incisors, canine and first premolars on cold sensation using a spherical dental cotton on which an ethyl chloride vapour was sprayed, Raghoobar et al., (2001). Tactile sensibility or skin sensitivity of the chin-lip area was tested, Raghoobar et al., (2007) by lightly brushing the skin with a wisp of cotton (the subject should be able to count the number of contacts with the eyes closed). Superficial pain was tested, Mason (1988); Joshi (2004); Raghoobar et al., (2007) with a needle (the subject should be able to tell whether contact with the skin was made with a sharp or dull instrument with the eyes closed). Moreover, patients were asked whether they experienced an altered sensation of their gingiva, in the mucosa and skin region innervated by the mental nerve Raghoobar et al., (2007). The outcome was classified according to Raghoobar et al.,(2001) and Joshi (2004) into the following definitions; when a patient reported diminished sensation without the presence of pain then this was defined as paraesthesia. Anaesthesia was related to complete absence of sensation and dysaesthesia was characterized by an altered sensation with discomfort and pain.

The true distances between the donor defect and the apices of the adjacent mandibular teeth were

measured, Von Arx et al., (2005) on a digital panoramic radiograph (1/1 with no magnification). The distance from the lateral margins of the donor defect to the right and left mental foramina (*RMF and LMF*) was also measured. Patients were recalled again one, three, six and 12 months after the initial surgery. Pulp sensitivity testing was repeated. Neurosensory disturbances of the chin, lower lip, and alveolar mucosa and other sensory disturbances of the teeth were also assessed.

2.2.3. Statistical analysis

Data were presented as frequencies, percentages, mean and standard deviation (SD) values. Mann-Whitney U test was used for comparisons between two groups. The significance level was set at $P \leq 0.05$. Statistical analysis was performed with PASW Statistics 18.0 (Predictive Analytics Soft Ware – SPSS; IBM Company, Chicago, IL, USA.) for Windows.

3. RESULTS

Post-operative morbidity was recorded in the patients of the current study. A total of six (30%) patients (2 patients from group I "piezosurgery group" and 4 patients from group II "conventional group") experienced anesthesia of the gingivae immediately postoperatively and had full recovery when reviewed at 3-month follow up. Three (15%) of these patients (one patient from piezosurgery group and two patients from conventional group) experienced paraesthesia of the chin and lower lip, however full recovery had occurred at the 6-month follow-up. None of the patients reported altered contour or change in profile of the chin area as well as dehiscence of the incision. Three patients (one patient from piezosurgery group and 2 patients from conventional group) experienced pain at the graft site for up to three months postoperatively. Nine patients (4 patients from piezosurgery group and 5 patients from conventional group) showed a negative pulp sensitivity reaction in their lower teeth to ethyl chloride at one week postoperatively; this further improved to 5 patients (2 patients in piezosurgery group and 3 patients in conventional group) at the 6-month follow-up and to 2 patients (one patient in each group) at the 12-month follow-up.

The average size of the chin bone donor defects as measured intra operatively was 898mm^3 in piezosurgery group and 892mm^3 in conventional group. The bone defects had a mean width of 18.1mm in piezosurgery group and 18.0 mm in conventional group, a mean height of 8.5mm in piezosurgery group and 8.6 mm in conventional

group, and a mean depth of 5.4mm in piezosurgery group and 5.5 mm in conventional group (Table 1).

Mean distances measured on digital panoramic radiographs between the mental foramen and the chin bone defects measured 13mm in piezosurgery group and 12.3mm in conventional group on the right side and 11.9mm in piezosurgery group and 11.1mm in conventional group on the left side (Table 2).

Table (1): Intra-operative size of the chin bone defect

Patients' groups	Mean \pm SD	Maximum	Minimum
Group I (piezosurgery group, (n=10))			
W, width (mm)	18.1 \pm 5.7	26	10
H, height (mm)	8.5 \pm 1.1	8	6
D, depth (mm)	5.4 \pm 1.4	7	4
Volume (W \times H \times D) (mm ³)	894 \pm 420	1540.5	363.7
Group II (conventional group), (n=10)			
W, width (mm)	18.0 \pm 5.3	24	10
H, height (mm)	8.6 \pm 1.1	9	6
D, depth (mm)	5.5 \pm 1.4	7	5
Volume (W \times H \times D) (mm ³)	892 \pm 346	1463.7	423

Table (2): Recorded distances of bone defect to adjacent mental foramina*

Patient's groups	Mean \pm SD	Maximum	Minimum
Group I (piezosurgery group, (n=10))			
RMF , right mental foramen (mm)	13 \pm 5.0	20	5
LMF , left mental foramen (mm)	11.9 \pm 4.5	19	5
Group II (conventional group), (n=10)			
RMF , right mental foramen (mm)	12.3 \pm 3.8	16	6
LMF , left mental foramen (mm)	11.1 \pm 3.4	15	5

*True measurements were taken from digital panoramic radiographs in mm.

Mean distances between the apices of mandibular first premolars/canines/incisors and the donor chin bone defect ranged from 6.6 to 9.7mm in piezosurgery group and 6.1 to 10.1mm in conventional group (Table 3).

Pulp sensitivity changes of the mandibular first premolars/canines/incisors were examined with ethyl chloride and were broken down per tooth (Table 4 in piezosurgery group) and (Table 5 in conventional group) and per patient (Table 6 in both groups). Total number of teeth in both groups was less than

160, since 36 teeth (15 teeth in piezosurgery group and 21 teeth in conventional group) with root-canal treatment, negative thermal testing at initial examination, or missing teeth was excluded for analysis of sensitivity changes over time. 16.9% (in piezosurgery group) and 20.3% (in conventional group) of previously positive teeth had a negative reaction to ethyl chloride at one week postoperatively; this further improved to 6.1% (in piezosurgery group) and 8.4% (in conventional group) at the 6-month follow-up and to 1.5% (in piezosurgery group) and 1.6% (in conventional group) at the 12-month interval.

Figures per patient were 40%, 20%, and 10%, respectively in piezosurgery group and 50%, 30%,

and 10%, respectively in conventional group. Two patients (one patient in each group) at 12 months post-operatively, their lower lateral incisor tooth did not react to thermal testing.

The mean distance between lower teeth apices and chin bone donor defect for teeth with negative response to thermal pulp testing was 7.5mm (piezosurgery group) and 7.8mm (conventional group) compared with a mean distance of 8mm (piezosurgery group) and 8.3mm (conventional group) in teeth normal response to thermal pulp testing (Tables 7 and 8). Corresponding data of chin bone donor defect sizes and distances to right and left mental foramina for both groups were shown in (Tables 9 and 10).

Table (3): Recorded distances of bone defect to apices of adjacent lower teeth*

Patients' groups	Mean \pm SD	Maximum	Minimum
Group I (piezosurgery group, n=10)			
Right first premolar (mm)	9.7 \pm 2.2	14	9
Right canine (mm)	8.7 \pm 1.8	12	8
Right lateral incisor (mm)	6.8 \pm 3.5	11	4
Right central incisor (mm)	7.4 \pm 3.8	13	4
Left central incisor (mm)	6.6 \pm 2.9	14	5
Left lateral incisor (mm)	6.6 \pm 3.1	13	5
Left canine (mm)	8.8 \pm 3.1	14	6
Left first premolar (mm)	9.2 \pm 3	15	10
Group II (conventional group, n=10)			
Right first premolar (mm)	9.8 \pm 1.9	14	10
Right canine (mm)	8.7 \pm 2.3	13	6
Right lateral incisor (mm)	6.8 \pm 3.2	15	5
Right central incisor (mm)	6.9 \pm 3.5	11	4
Left central incisor (mm)	6.1 \pm 2.6	10	5
Left lateral incisor (mm)	6.2 \pm 2.8	11	4
Left canine (mm)	8.4 \pm 2.2	12	7
Left first premolar (mm)	10.1 \pm 2.6	16	9

*True measurements were taken from digital panoramic radiographs in mm.

Table (4): Changes in pulp sensitivity of mandibular anterior teeth and first premolars in group I (piezosurgery group) following chin bone harvesting per tooth (n = 80)

Mandibular tooth	One week	One month postoperative	3 months postoperative	6 months postoperative	12 months postoperative
Right first premolar (n = 8)	-	-	-	-	-
Right canine (n = 9)	2 (22.2%)	2 (22.2%)	2 (22.2%)	1 (11.1%)	-
Right lateral incisor (n = 9)	1 (11.1%)	1 (11.1%)	1 (11.1%)	1 (11.1%)	1 (11.1%)
Right central incisor (n = 8)	2 (25%)	2 (25%)	1 (12.5%)	-	-
Left central incisor (n = 7)	2 (28.5%)	2 (28.5%)	2 (28.5%)	1 (14.2%)	-
Left lateral incisor (n = 8)	1 (12.5%)	1 (12.5%)	1 (12.5%)	1 (12.5%)	-
Left canine (n = 9)	2 (22.2%)	2 (22.2%)	1 (11.1%)	-	-
Left first premolar (n = 7)	1 (14.2%)	1 (14.2%)	1 (14.2%)	-	-
Total number (n = 65)*	11 (16.9%)	11 (16.9%)	9 (13.8%)	4 (6.1%)	1 (1.5%)

Total number of teeth less than 80, since 15 teeth with root-canal treatment, negative thermal testing at initial examination, or missing teeth was excluded for analysis of sensitivity changes over time.

Table (5): Changes in pulp sensitivity of mandibular anterior and first premolars in group II (conventional group) following chin bone harvesting per tooth (n = 80)

Mandibular tooth	One week postoperative	One month postoperative	3 months postoperative	6 months postoperative	12 months postoperative
Right first premolar (n = 7)	-	-	-	-	-
Right canine (n = 8)	2 (25%)	2 (25%)	2 (25%)	1 (12.5.1%)	-
Right lateral incisor (n = 8)	2 (25%)	2 (25%)	2 (25%)	1 (12.5.1%)	-
Right central incisor (n = 7)	2 (28.5%)	2 (28.5%)	2 (28.5%)	1 (14.2%)	-
Left central incisor (n = 7)	2 (28.5%)	2 (28.5%)	2 (28.5%)	1 (14.2%)	-
Left lateral incisor (n = 6)	1 (16.6%)	1 (16.6%)	1 (16.6%)	1 (16.6%)	1 (16.6%)
Left canine (n = 9)	2 (22.2%)	2 (22.2%)	1 (11.1%)	-	-
Left first premolar (n = 7)	1 (14.2%)	1 (14.2%)	1 (14.2%)	-	-
Total number (n = 59)*	12 (20.3%)	12 (20.3%)	11(18.6%)	5 (8.4%)	1 (1.6%)

*Total number of teeth less than 80, since 21 teeth with root-canal treatment, negative thermal testing at initial examination, or missing teeth was excluded for analysis of sensitivity changes over time

Table (6): Changes in pulp sensitivity of mandibular anterior teeth and first premolars in group I (piezosurgery group) and group II (conventional group) following chin bone harvesting per patient

Patients' groups	One week postoperative	One month postoperative	3 months postoperative	6 months postoperative	12 months postoperative
Group I, (n=10)	4 (40%)	4 (40%)	3 (30%)	2 (20%)	1(10%)
Group II, (n=10)	5 (50%)	5 (50%)	3 (30%)	3 (30%)	1(10%)
Total (n = 20)	9 (45%)	9 (45%)	6 (30%)	5 (25%)	2 (10%)

Table (7): Mean and Standard Deviation (SD) of distance between chin bone defect and apices of lower anterior and first premolar teeth with and without negative response to thermal pulp testing in both piezosurgery and conventional groups (n = 124, originally 160)**

	Teeth with negative response to thermal pulp testing			Teeth without negative response to thermal pulp testing		
	Piezosurgery group n = 11	Conventional group n = 12	P-value*	Piezosurgery group n = 54	Conventional group n = 47	P-value*
Mean distance to the apex in mm ± SD	7.5±2.9	7.8±2.5	P=0.936	8±3.2	8.3±3.3	P=0.957

*Mann-Whitney U test was used for comparisons between two groups. The significance level was set at $P \leq 0.05$.

**Total number of teeth in both groups less than 160, since 36 teeth (15 in piezosurgery group and 21 in conventional group) with root-canal treatment, negative thermal testing at initial examination, or missing teeth was excluded for analysis of sensitivity changes over time.

Table (8): Mean and Standard Deviation (SD) of distance between chin bone defect and apices of lower anterior and first premolar teeth with and without negative response to thermal pulp testing in each group (n for each group originally 80)**

	Piezosurgery group			Conventional group		
	Teeth with negative response n = 11	Teeth without negative response n = 54	P-value*	Teeth with negative response n = 12	Teeth without negative response n = 47	P-value*
Mean distance to the apex in mm ± SD	7.5±2.9	8±3.2	P=0.886	7.8±2.5	8.3±3.3	P=0.890

*Mann-Whitney U test was used for comparisons between two groups. The significance level was set at $P \leq 0.05$.

** Total number of teeth in each group less than 80, since 15teeth in piezosurgery group and 21 teeth in conventional group with root-canal treatment, negative thermal testing at initial examination, or missing teeth was excluded for analysis of sensitivity changes over time.

Table (9): Mean and Standard Deviation (SD) of bone defect volume (size) and distances of defect to right and left mental foramen in patients with and without negative response to thermal pulp testing in both piezosurgery and conventional groups (n of patients in both groups = 20)

	Patients with negative response to thermal pulp testing			Patients without negative response to thermal pulp testing		
	Piezosurgery group n = 4	Conventional group n = 5	P-value*	Piezosurgery group n = 6	Conventional group n = 5	P-value*
Mean volume of the bone defect mm ³ ± SD	1243±198	1198±335	P=0.795	687±394	586±159	P=0.175
Mean distance of bone defect in mm to RMF ± SD	9±4.6	9.8±3.9	P= 0.887	15.5±3.5	14.8±1.1	P= 0.852
Mean distance of bone defect in mm to LMF ± SD	7.5±2.8	9.2±3.8	(P= 0.379)	13.5±2.7	13.4±1.1	P= 0.958

*Mann-Whitney U test was used for comparisons between two groups; the significance level was set at $P \leq 0.05$; RMF, right mental foramen; LMF, left mental foramen.

Table (10): Mean and Standard Deviation (SD) of bone defect volume (size) and distances of defect to right and left mental foramen in patients with and without negative response to thermal pulp testing in each group (n of patients in each group patients = 10)

	Piezosurgery group			Conventional group		
	Patients with negative response n = 4	Patients without negative Response n = 6	P-value*	Patients with negative response n = 5	Patients without negative Response n = 5	P-value*
Mean volume of the bone defect mm ³ ± SD	1243±198	687±394	P < 0.001*	1198±335	586±159	P < 0.001*
Mean distance of bone defect in mm to RMF ± SD	9±4.6	15.5±3.5	P = 0.001*	9.8±3.9	14.8±1.1	P = 0.005*
Mean distance of bone defect in mm to LMF ± SD	7.5±2.8	13.5±2.7	P= 0.033*	9.2±3.8	13.4±1.1	P= 0.020*

*Mann-Whitney U test was used for comparisons between two groups; the significance level was set at $P \leq 0.05$; RMF, right mental foramen; LMF, left mental foramen.

Statistical results

Parameters comparisons between both piezosurgery and conventional groups showed no statistically significant difference. However, parameters comparisons across each group showed statistically significant difference between different parameters in teeth with and without negative response to thermal pulp testing in each group.

Regarding mean distance between chin bone defect and apices of teeth with and without negative response to thermal pulp testing; there was no statistically significant difference between both groups in teeth with negative response (P -value = 0.936) as well as teeth without negative response (P -value = 0.957) to thermal pulp changes. Moreover, no statistically significant difference was found in teeth with and without negative response to thermal pulp changes in piezosurgery group (P -value = 0.886) or in conventional group (P -value = 0.890).

Regarding mean volume of the chin harvest bone defect in teeth with and without negative response to thermal pulp testing; there was no statistically

significant difference between both groups in teeth with negative response (P -value = 0.795) as well as teeth without negative response (P -value = 0.175) to thermal pulp changes. However, across piezosurgery group or conventional group, the mean volume of bone defect in teeth with negative response showed statistically significantly higher value than in teeth without negative response to thermal pulp testing (P -value < 0.001).

Regarding mean distance of the defect to the right mental foramen in teeth with and without negative response to thermal pulp testing; there was no statistically significant difference between both groups in teeth with negative response (P -value = 0.887) as well as teeth without negative response (P -value = 0.852) to thermal pulp changes. However, across each group, the mean distance of the defect to the right mental foramen in teeth without negative response showed statistically significantly higher value than in teeth with negative response to thermal pulp testing; in piezosurgery group (P -value = 0.001) and in conventional group (P -value = 0.005).

Regarding mean distance of the defect to the left mental foramen in teeth with and without negative response to thermal pulp testing; there was no statistically significant difference between both groups in teeth with negative response (P -value = 0.379) as well as teeth without negative response (P -value = 0.958) to thermal pulp changes. However, across each group, the mean distance of the defect to the left mental foramen in teeth without negative response showed statistically significantly higher value than in teeth with negative response to thermal pulp testing; in piezosurgery group (P -value = 0.033) and in conventional group (P -value = 0.020).

4. DISCUSSION

The mandibular symphysis is the most commonly used intra-oral donor site. The morbidity can still be a problem for patients and it is important to highlight such morbidities to patients before considering intra-oral augmentation, Misch et al.,(1992).In the current study, a total of six (30%) patients from both groups experienced anesthesia of the gingivae immediately postoperatively and had full recovery when reviewed at 3 month follow up. Three of these patients (15%) experienced paraesthesia of the chin and lower lip, however full recovery had occurred at the 6- month follow-up. The results in this study compared favourably with previous studies of Raghoobar et al. (2001);Nkenke et al.,(2001) ;Joshi (2004);Von Arx et al., (2005) who investigated the postoperative morbidity following chin graft harvesting.

Joshi (2004) concluded that two (7.4%) patients experienced paraesthesia of the chin, lower lip and gingiva immediately post-operatively and had full recovery when reviewed at 3 months. Furthermore, Von Arx et al., (2005) observed lower lip hypoesthesia in one patient out of 30 patients at suture removal postoperatively, with complete resolution at the 6-month follow-up. Nkenke et al., (2001) identified five (25%) patients with hypoesthesia of the chin at the first postoperative examination using the two-point and pointed blunt discrimination tests. At the 12- month follow-up, two (10%) patients still had impairment of sensitive nerve function in the chin area. The relatively frequent finding of temporary and persisting hypoesthesia of the chin and lip areas in Nkenke et al. (2001) study was related to the extended paramarginal incision from region 35 to 45 in contrast to the current study as the incision was not extending beyond distal aspects of the mandibular canines and this might have contributed to a relatively lower incidence of altered sensitivity of the mental nerve as confirmed with the study of Gapski et al, (2001). Raghoobar et al., (2001) found that 9 patients out of

21 patients experienced paraesthesia of the chin region and only 2 patients had full recovery when reviewed after 3 months post-operative.

The most likely reason for the lip and/or chin paraesthesia or hypoesthesia is due to neuropraxia of the incisive nerve or the terminal branches of the mental nerve, Misch et al., (1992); Bavitz et al.,(1993). The incidence of temporary mental nerve paraesthesia is thought to be approximately 10% (compared with 15% in the current study) and post-operative neuropraxia is not uncommon, Misch et al., (1992). When a chin graft is harvested, the mental nerve is often stretched during flap elevation and flap retraction as well as it is important not to underestimate the distance of the inferior alveolar nerve because of the S-shaped course of the nerve before leaving the mandible, Bavitz et al., (1993). It is therefore important to assess nerve function pre-operatively and patients should be warned of the possibility of altered sensation of the gingiva, lower lip and chin region post-operatively.

Altered sensation of the lower teeth is also a common temporary post-operative symptom, Misch (1995). In the current study, a total of nine (45%) patients from both groups experienced in their lower teeth changes in pulp sensitivity with a negative reaction to ethyl chloride at one week postoperatively; this further improved to 5 (25%) patients at the 6-month follow-up and to 2 (10%) patients at the 12-month follow-up. Commonly lower central incisor teeth were affected. The result of this study was in agreement with Joshi (2004) who reported that five (18.5%) of patients experienced numbness of the lower anterior teeth at the first post-operative visit. Lower anterior incisor teeth were commonly affected. At 12 months, two patients continued to have no sensitivity in their lower anterior incisor teeth. In contrast to the findings of the current study, Nkenke et al., (2001) showed that canines were affected preferentially.

There was no statistically significant difference in the current study between both groups or within each group regarding mean distance of bone defect and apices of teeth with as well as without negative response to thermal pulp changes; means \pm SD was 7.6 ± 2.7 and 8.1 ± 3.2 in teeth with and without negative response respectively. The data of the cited studies, Misch(1997); Hunt, and Jovanovic (1999); Cranin et al.,(2001), as well as, of the present study underline that a generally recommended safety distance of 5mm during graft harvest below the apices of lower anterior teeth does not appear to be the decisive factor whether pulp sensitivity changes are to occur or not. Animal experiments performed by Neukam et al., (1981) showed that the margin of

safety should be at least 8 mm to preserve blood supply of the front teeth.

The present study found a significant difference regarding the mean volume of the bone defect as well as mean distance of the defect to mental foramen of both sides in patients with sensitivity changes compared with patients without such changes. Therefore, the width of the donor defect as well as the distance to the mental foramina of both sides might be of influence whether pulp sensitivity changes are to occur or not. Extending the donor defect towards the mental foramen, the contents of the incisive canal (anterior extension of mandibular canal), which innervate the teeth, may be disturbed, Misch (1997). Therefore, the current study found that a panoramic radiograph was mandatory for preoperative location of the mental foramen.

Furthermore, negative pulp response of the adjacent teeth to ethyl chloride in the current study was found in 16.9% (*piezosurgery group*) and 20.3% (*conventional group*) at one week post-operative. At the 6-month follow up, 6.1% (*piezosurgery group*) and 8.4% (*conventional group*) of teeth showed negative pulp response. At 12-month follow up, 1.5% (*piezosurgery group*) and 1.6% (*conventional group*) of teeth showed negative pulp response. The findings of this study were in agreement with similar studies of Nkenke et al., (2001); Von Arx et al., (2005) reported that pulp sensitivity changes were found in 18.6% of adjacent teeth at the time of suture removal. At the 6-month follow-up, 8.1% of teeth, and at the 12-month re-examination, 0.6% of teeth presented with altered sensitivity. Nkenke et al., (2001) reported on 20 patients who underwent harvesting of chin grafts, and who were followed up for 12 months. At one-week postoperative evaluation, 22% of the examined teeth had lost their pulp sensitivity. Percentages of teeth with negative pulp sensitivity decreased to 13% at 6 months and to 11% at 12 months. In agreement with the current study, the majority of studies conducted by Chiapasco et al., (1999) and Nkenke et al., (2001) illustrated a continuous improvement of pulp sensitivity over time; however surveys of at least 12 months showed that a considerable number of teeth may present with a permanent change of pulp sensitivity.

None of the patients in the current study showed pulpal necrosis in agreement with Von Arx and Kurt (1998) who found that pulpal necrosis following chin graft harvesting was a very rare finding and might be explained by arterial anastomosis from Rami inter-incisivi of the sublingual artery to the Arteria alveolaris inferior anterior. Therefore, if the apices of the mandibular incisors and canines are not

damaged during bone drilling, pulp necrosis is unlikely to occur following symphyseal bone harvesting, Van der Zypen (1985). None of the patients in the current study reported altered contour or change in profile of the chin area. This was in agreement with Joshi (2004) who observed that out of 27 patients, none of those patients complained of altered chin morphology. Cotter et al.,(2002) reported that recently grafts harvested from the mandibular lower border showed no discernible change of significance in chin morphology.

A total of three (15%) patients from both groups in the current study experienced pain at the graft site for up to three months postoperatively. This finding was in agreement with Raghoobar et al.,(2001) who reported that 9 (42.8%) patients presented with pain at chin bone defect area at suture removal postoperatively; this further improved and only weather-related discomfort was presented in 4 (19%) patients at the 3-month follow-up.

Wound dehiscence is a short-term postoperative complication following chin bone harvesting. Misch (1997) observed dehiscence of the incision line in 9.6% of the patients with alveolar mucosa incision. No dehiscence occurred following a sulcular incision. The application of an extra oral pressure dressing is recommended to prevent separation of wound margins. Von Arx and Kurt (1998) observed wound dehiscence in 20% of cases using alveolar mucosa approach. Observing these surgical approaches, no wound dehiscence was found in the current study as a sulcular incision was selected.

In conclusion, a preoperative examination should include adequate radiographs and sensibility tests of the soft tissue and teeth, presenting valuable baseline information when discussing post-surgical chin graft harvesting morbidity. Safety margins to adjacent vital structures must not be compromised, and instead alternative donor sites should be discussed when larger grafts are required. The current study found that the surgical control for the piezosurgery was easier than conventional methods for mobilizing a chin bone block graft. The force necessary to produce a cut was much less compared to rotational burs. Increased temperature during bone cutting with piezosurgery was avoided which reduces the risk of bone damage as a result of overheating. The piezosurgery osteotomy makes a narrow cut with little bone wastage. Temporary paraesthesia of the mental nerve following chin graft harvesting was a very rare finding and showed complete resolution. Thermal pulp sensitivity changes of lower anterior teeth were observed less frequently with improvement over time. Despite the above morbidities, harvesting of chin bone was successful

and providing patients with fully informed of the possible risks of altered sensation of the gingiva, lower lip and chin area along with loss of sensitivity of lower anterior teeth, autogenous bone remains the best option.

5. REFERENCES

- Antoun, H., Sitbon, J.M., Martinez, H., Missika, P. A prospective randomized study comparing two techniques of bone augmentation: onlay grafts alone or associated with a membrane. *Clin Oral Implants Res* 12: 632–639, 2001
- Aro H, Kallionieme H, Aho AJ, Kellokumpu-Lehtinen P. Ultrasonic device in bone cutting. A histological and scanning electron microscopical study. *Acta Orthopaedica Scandinavica* 52: 5-10, 1981
- Buser, D., Dula, K., Hirt, H.P, Schenk, R.K. Lateral ridge augmentation using autografts and barrier membranes. A clinical study in 40 partially edentulous patients. *J Oral Maxillofac Surg* 54: 420–432, 1996
- Barone A, Santini S, Marconcini S, et al: Osteotomy and membrane elevation during the maxillary sinus augmentation procedure. A comparative study: Piezoelectric device vs. conventional instruments. *Clin Oral Implants Res* 19:511, 2008
- Bavitz J B, Harn S D, Hansen C A, Lang M. An anatomical study of mental neurovascular bundle — implant relationships. *Int J Oral Maxillofac Impl* 8: 563-567, 1993
- Blackburn C W. A method of assessment in cases of lingual nerve injury. *Br J Oral Maxillofac Surg* 28: 238-245, 1990
- Chiriac G, Herten M, Schwarz F, et al: Autogenous bone chips: Influence of a new piezoelectric device (piezosurgery) on chip morphology, cell viability and differentiation. *J Clin Periodontol* 32:994, 2005
- Cotter C J, Maher A, Gallagher C, Sleeman D. Mandibular lower border: donor site of choice for alveolar grafting. *Br J Oral Maxillofac Surg* 2002; 40: 429-432, 2002.
- Cranin, A.N., Katzap, M., Demirdjan, E. & Ley, J. Autogenous bone ridge augmentation using the mandibular symphysis as a donor. *J Oral Implantol* 27: 43–47, 2001
- Chiapasco, M., Abati, S., Romeo, E., Vogel, G. Clinical outcome of autogenous bone blocks or guided bone regeneration with ePTFE membranes for the reconstruction of narrow edentulous ridges. *Clin Oral Implants Res* 10: 278–288, 1999
- Eggers G. et al. Piezosurgery: an ultrasound device for cutting bone and its use and limitations in maxillofacial surgery. *Br J Oral Maxillofac Surg* 42: 451-453, 2004
- Gapski. R , Wang. H, Misch, C. Management of incision design in symphysis graft procedures: a review of the literature. *J Oral Implantol* 3; 163, 2001
- Happe A: Use of a piezoelectric surgical device to harvest bone grafts from the mandibular ramus: Report of 40 cases. *Int J Periodontics Restorative Dent* 27:241, 2007.
- Hunt, D.R. & Jovanovic, S.A. Autogenous bone harvesting: a chin graft technique for particulate and monocortical bone blocks. *Int J Periodontics Restorative Dent* 19: 165–173, 1999.
- Joshi, A. An investigation of post-operative morbidity following chin graft surgery. *Br Dent J*; 196 : 4 , 215-218, 2004.
- Lorenzetti, M., Mozzati, M., Campanino, P.P., Valente, G. Bone augmentation of the inferior floor of the maxillary sinus with autogenous bone or composite bone grafts: a histologic histomorphometric preliminary report. *Int J Oral Maxillofac Implants* 13: 69–76, 1998.
- Mason D A. Lingual nerve damage following lower third molar surgery. *Int J Oral Maxillofac Surg* 7: 290-294, 1988.
- McCarthy, C., Patel, R.R., Wragg, P.F., Brook, I.M. Dental implants and onlay bone grafts in the anterior maxilla: analysis of clinical outcome. *Int J Oral Maxillofac Implants* 18: 238–241, 3003a.
- McCarthy, C., Patel, R.R., Wragg, P.F., Brook, I.M. Sinus augmentation bone grafts for the provision of dental implants: reports of clinical outcome. *Int J Oral Maxillofac Implants* 18: 377–382, 2003b.
- Merkx, M.A.W., Maltha, J.C., Stoelinga, P.J.W. Assessment of the value of anorganic bone additives in sinus floor augmentation: a review of clinical reports. *Int J Oral Maxillofac Surg* 32: 1–6, 2003.
- Misch C M. Comparison of intra-oral donor sites for onlay grafting prior to implant placement. *Int J Oral Maxillofac Implants* 12: 767-776, 1997.
- Misch C M, Misch C E, Resnik R R, Ismail Y H. Reconstruction of maxillary alveolar defects with mandibular symphysis grafts for dental implants: a preliminary procedural report. *Int J Oral Maxillofac Implants* 7: 360-366, 1992.
- Misch C M, Misch C E. The repair of localised severe ridge defects for implant placement using

- mandibular bone grafts. *Implant Dent* 4: 261-267, 1995.
- Neukam F W, Hausamen J E, Kaufmann K. Animal experimental trials on the blood supply of the alveolar ridge and the teeth after alveolar osteotomy in relation to the distance of the perpendicular osteotomy line to the root apices. *Deutsche Zeitschrift für Mund-Kiefer-Gesichts-Chirurgie* 5: 369-372, 1981.
- Nkenke E, Schultze-N!osgau S, Radespiel-Troger M, Kloss ., Neukam FW. Morbidity of harvesting of chin grafts: a retrospective study. *Clin Oral Implants Res* 12: 495-502, 2001.
- Raghoobar, G.M., Batenburg, R.H.K., Vissink, A., Reintsema, H. Augmentation of localized defects of the anterior maxillary ridge with autogenous bone before insertion of implants. *J Oral Maxillofac Surg* 54: 1180-1185, 1996.
- Raghoobar, G, Meijndert, L, Kalk, W, Vissink, A. Morbidity of mandibular bone harvesting: A comparative study. *Int J Oral Maxillofac Implants* 22:359-365, 2007.
- Raghoobar GM, Louwse C, Kalk W , Vissink A . Morbidity of chin bone harvesting. *Clin Oral Implants Res* 12: 503-507, 2001.
- Sakkas N, Otten JE, Gutwald R, Schmelzeisen R: Transposition of the mental nerve by piezosurgery followed by postoperative neurosensory control: A case report. *Br J Oral Maxillofac Surg* 46:270, 2008.
- Sethi, A., Kaus, T. Ridge augmentation using mandibular block bone grafts: preliminary results of an ongoing prospective study. *Int J Oral Maxillofac Implants* 16: 378- 388, 2001.
- Stübinger S, Kuttenger J, Filippi A, Sader R, Zeilhofer HF. Intraoral Piezosurgery: Preliminary Results of a New Technique. *J Oral Maxillofac Surg* 63(9): 1283-7, 2005.
- Schlee M. et al. Piezosurgery: Basic and Possibilities. *Implant Dentistry* 15(4): 334-338, 2006.
- Sohn DS, Ahn MR, Lee WH, et al: Piezoelectric osteotomy for intraoral harvesting of bone blocks. *Int J Periodontics Restorative Dent* 27:127, 2007.
- Triplett R G, Sihow S R. Osseus regeneration with bone harvested from the anterior mandible. In: Nevirs M, Mellonig J T, eds. *Implant therapy. Clinical approaches and evidence of success.* Chicago: Quintessence Publishing Company. pp 209- 217, 1998.
- Tolman D E. Reconstructive procedures with endosseous implants in grafted bone: a review of the literature. *Int J Oral Maxillofac Implants* 10: 275-294, 1995.
- Van der Zypen, E. Anatomische Grundlagen zur Implantation (in German). *Schweizerische Monatsschrift für Zahnmedizin* 95: 827-837, 1985.
- Vercellotti T, Nevins ML, Kim OM, Nevins M, Wada K, Schenk RK, Fiorellini JP 2005. Osseous response following resective therapy with a piezosurgery. *Int J Periodontics Restorative Dent* 25: 543-549, 2005
- Von Arx, T. and Kurt, B. Die enorale Knochenentnahme zur Autotransplantation. Eine klinische Vergleichsstudie der Entnahmestellen im Kinnbereich und in der Retromolar-Region in German). *Schweizerische Monatsschrift für Zahnmedizin* 108: 447-453, 1998.
- Von Arx, T., Fliger, H., Chappuis, V. Neurosensory disturbances following bone harvesting in the symphysis: a prospective clinical study *Clin. Oral Impl. Res.* 16, 432-439, 2005
- Wallace SS, Mazor Z, Froum SJ, et al: Schneiderian membrane perforation rate during sinus elevation using piezosurgery: Clinical results of 100 consecutive cases. *Int J Periodontics Restorative Dent* 27:413, 2007.
- Widmark, G., Andersson, B., Ivanoff, C.-J. Mandibular bone graft in the anterior maxilla for single-tooth implants. Presentation of a surgical method. *Int J Oral Maxillofac Surg* 26: 106-109, 1997.
- Yildirim, M., Spiekermann, H., Handt, S. Edelhoff, D. Maxillary sinus augmentation with xenograft bio-oss and autogenous intraoral bone for qualitative improvement of the implant site: a histologic and histomorphometric clinical study in humans. *Int J Oral Maxillofac Implants* 16: 23-33, 2001.