

## The Ameliorative Role of Grape Seed Oil on Irradiated Rat Fungiform Papillae

Samah S Mehanni<sup>1</sup> Eman M El- Maghraby<sup>2\*</sup>, Alyaa R Hassan<sup>3</sup>, Dalia A H El-Baz<sup>1</sup>

<sup>1</sup>Oral Biology Department, Faculty of Oral and Dental Medicine, Cairo University, Cairo, Egypt.

<sup>2</sup>Health Radiation Research Department, National Center for Radiation Research and Technology (NCRRT), Cairo, Egypt.

<sup>3</sup>Supplementary science department, Faculty of Oral and Dental Medicine, Future University, Cairo, Egypt  
[emey\\_maghraby@hotmail.com](mailto:emey_maghraby@hotmail.com)

**Abstract:** This study was held to clarify changes in the epithelium of the fungiform papillae after irradiation at the microscopic level as well as the effect of grape seed oil (GSO) on these changes and the changes in the innervation of these papillae. Thirty five male Swiss Albino rats were included in this study. The animals were divided into, Grape seed irradiated group (GSI gp): GSO was administrated orally in accompanied with radiation. Irradiated group (IR gp): The same protocol was applied to this group except that the animals received distilled water instead. Control group(C gp): only distilled water was administrated orally. The right tongue halves were prepared for Ultrastructural studies. The left halves were used for detection of the innervations using S100. Degeneration of the cell nuclei and organelles in *stratum* basale and *spinousum* of the fungiform papillae in **IR gp** was obvious. In the **GSI gp** the nuclei had prominent nucleoli and granulated chromatin. The regeneration of the epithelium in the **IR gp** was delayed compared with **GSI gp**. Regeneration of the cytoskeleton was advanced in the **GSI gp**. Significant obvious decrease in the innervations was indicated in the **IR gp** at the third day post irradiation compared with both **GSI gp** and **C gp**. Toward the end of the experiment, increase in the innervations was more detectable in **GSI gp**. For these reasons, grape seed oil is recommended to be consumed as a dietary supplement and could be useful in synergizing the hazardous of radiation on the tongue papillae.

[Samah S Mehanni, Eman M El- Maghraby, Alyaa R Hassan, and Dalia A H El-Baz. **The Ameliorative Role of Grape Seed Oil on Irradiated Rat Fungiform Papillae**. *Journal of American Science*. 2012;8(6):608-614]. (ISSN: 1545-1003). <http://www.americanscience.org>. 75

**Keywords:** Grape Seed oil, radiation, tongue papillae, ultrastructure, innervation.

### 1. Introduction

Taste deficits as a consequence of head and neck radiation were recently referred to as post-irradiation gustatory dysfunction. It is a common problem among head and neck radiation therapy (RT) patients [1]. It is generally accepted that taste disorders caused by radiochemotherapy result from epithelial changes [2]. Direct damage of the mucosa occurs through inhibition of DNA replication and mucosal cell proliferation [3]. Radiation is known also to generate reactive oxygen species such as superoxide radicals, hydrogen peroxides and hydroxyl radicals. These products have been found to injure cells, leading to mucositis [4]. Mucositis is a significant and painful side effect that can affect the ability to eat, swallow, speech leading to secondary infection and weight loss as well can limit cancer treatment [5,6]. Mucositis is an acute injury to the mucosal lining and histologically characterized by ulceration and pseudomembranous formation caused by cancer therapies [7,8]. Radical scavenging by antioxidants and hence a reduction of radiation effects at their onset have been suggested to prevent the side effects of RT [9]. Little is known about the changes in the epithelium of the fungiform papillae after radiation at the microscopic level as well as the effect

of grape seed oil, as an antioxidant [10-12], on these changes. Thus this study was held to clarify these changes ultrastructurally and the changes that occurred in the innervation of these papillae.

### 2. Methods

#### Animals

Thirty five male Swiss Albino rats (100-120 gm) purchased from the Animal House of the Faculty of Medicine, Cairo University were included in the study. The experimental protocol used was approved by the department of Animal care, Cairo University that adhered to the European Communities Council guiding principles for the care and use of Laboratory Animals. The animals were housed in a controlled environment at 25°C with 12 hrs light /dark cycle and were acclimated for three-five days before use. All animals were allowed free access to food and tap water.

#### Grape seed oil administration:

Grape seed oil (GSO) was administrated orally at a dose of 100mg/kg body weight [13] obtained from Sigma, Chemical Co. (Nasr City, Cairo, Egypt).

#### Radiation exposure:

Irradiation of animals was performed at National Center for Radiation Research and Technology (NCRRT), Cairo, Egypt using 137 Cesium Gamma Cell 40 giving a dose rate of 0.795 Gray/ min at the time of experiment.

#### Experimental design:

The animals were divided into three groups, first two groups consisted of 15 animals while the third group consisted of five animals only: *Grape seed irradiated group*: GSO was administered for seven consecutive days by a curved gastric intubation using a plastic syringe with special stainless steel needle. This group received radiation as a single dose of (6.4Gy –Cesium 137) whole body irradiation, and GSO was maintained for 14 additional days. *Irradiated group*: The same protocol was applied to this group except that the animals received distilled water instead of GSO in a similar manner along with procedure. *Control group*: only distilled water was administered orally by gastric intubation. Following their exposure to radiation, the animals were placed individually in the cages. The rats of the *Grape seed group* and *Irradiated group* were decapitated under mild anesthesia (50 mg/kg, i.p. ketamine) three, seven and fourteen days post radiation. The rats of the control group were decapitated under mild anesthesia after one week of housing.

#### Transmission electron microscopic studies:

The right tongue halves were dissected and fixed in the modified Karnovsky solution, containing 2.5% glutaraldehyde, 2% paraformaldehyde in a 0.1 M (pH 7.3) sodium cacodylate buffer. Then, the tissues were fixed in the same solution for 12 hours at 4 °C. The specimens were postfixed in 2% osmium tetroxide solution, rinsed in distilled water, and immersed in 2% tannic acid solution for 1 hour at room temperature [14].

Then, the tissues were dehydrated in an increasing series of ethanol and propylene oxide and embedded in Spurr resin. The thick sections were made in Porter Blum ultramicrotome using glass knives and stained with toluidin blue solution for light microscopy analysis. For thin sections were used ultramicrotome Ultra-Cut Reichert with diamond knife. The ultrathin sections were mounted on 200 and 300 mesh grids, counterstained with uranyl acetate and lead citrate and examined in transmission electron microscopy Joel, JSM1010 at 100 kV.

#### Immuno-histochemical studies:

For detection of the nerves, the left tongue halves were fixed in 4% glutaraldehyde fixer. **S100**: anti-human clone (MAC 387) catalog number ZO-

311 Rabbit monoclonal, (DAKO Corporation) was used in dilution of 1:50.

Measurements of area % of S100 immunopositivity were done at ten different fields within the fungiform papillae by image analyzer computer system using the software Leica Qwin 500 and the mean area % was calculated for each specimen.

#### Statistical Analysis:

Data were expressed as mean  $\pm$  standard deviation ( $X \pm SD$ ). Comparison of S100 expression between the groups was made using the post-hoc test in one way analysis of variance (ANOVA). Representative charts were generated from the data.

### 3. Results

#### Electron microscopic results

At the third day post irradiation, the radiation hazards were clear and obvious in both the *Stratum basal* and *spinosum* of the fungiform papillae. The nuclei of the basal cells in the *irradiated* group were degenerated as well as most of the cell organelles. Sporadic multinucleated cells were detected (Fig.1). On the other hand, the *grape seed irradiated group* did not reveal these multinucleated cells but the cell organelles were still ill defined except of few survived free ribosomes. The nuclei had prominent nucleoli and granulated chromatin. The cytoplasm appeared vacuolated. Remnants of desmosomes and tonofibrils could be detected (Fig. 2).

Both groups displayed kerato-hyaline granules and few homogenous Odland's bodies that lack the normal lamellated appearance in the stratum granulosum (Fig.3).

The keratin layer showed irregular surface and appeared homogenous with ill defined cell borders, desmosomes and cell organelles especially in the *irradiated* group (Fig.4).

At the *seventh day post irradiation*, degeneration of the different cell layers was clear in the *irradiated* group as shown in Fig. 5. There were loss of cell boundaries and junctions. Vacuolization increased in great manner. Thinning of the epithelium and sloughing of the keratin layer were noticeable. The basal cells of the fungiform papillae of the *grape seed irradiated group*, in contrast, disclosed regenerated rough endoplasmic reticulum intermingled with cytoplasmic vacuoles. The cells retained their boundaries but lost their junctions (Fig. 6).

The regeneration of the epithelium in the *irradiated* group was delayed till the fourteenth day post irradiation. Regeneration of the cytoskeleton was advanced in the *grape seed irradiated group* (Fig. 7).

#### Statistical results:

Significant obvious decrease in the innervations was indicated in the *irradiated group* at the third day post radiation compared with both *grape seed irradiated* and *control* groups. A marked increase in these innervations was detected at the seventh and fourteenth days post radiation but still far away from

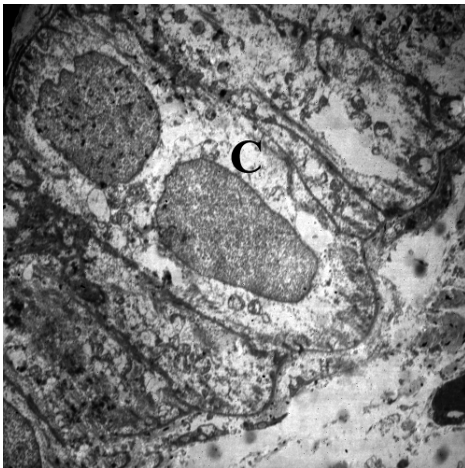that of the control group. On the other hand, when comparing *grape seed irradiated* to the *control* group, the increase in the innervations was more detectable such that seemed to be normal after the fourteenth day post irradiation (Figs. 8-10, Table 1).

**Table I:** Difference in the mean area percent between different groups:

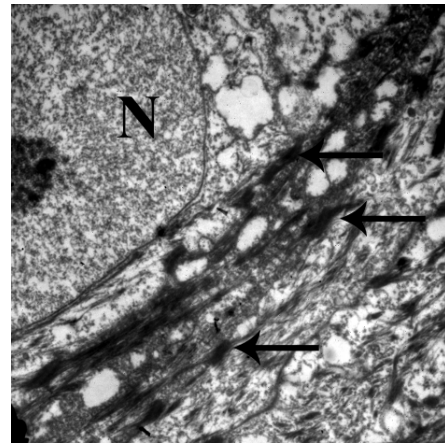
Group	Control (n=5) x ± SD	Irradiated (n=5) x ± SD	Grape seeds n=(5) x ± SD	F-ratio	P value
Area percent at 3 days		12.8 ± 0.93 <sup>a</sup>	45.52 ± 2.99 <sup>a,b</sup>	451.68	<0.0001
Area percent at 7 days	56.18 ± 3.15	26.6 ± 2.53 <sup>a</sup>	51.97 ± 1.49 <sup>a,b</sup>	207.56	<0.0001
Area percent at 14 days		44.64 ± 1.61 <sup>a</sup>	54.83 ± 3.33 <sup>b</sup>	25.3	<0.0001

a: Significant difference between groups versus control group.


b: Significant difference between groups versus irradiation group.



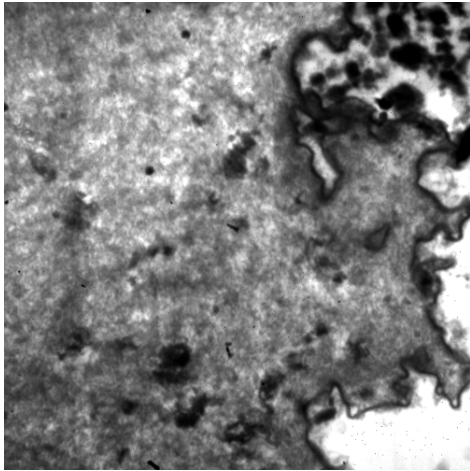
**Fig.1:** An electron micrograph of the stratum basal of the *irradiated group* at the third day post irradiation shows multinucleated cell (c). X1000



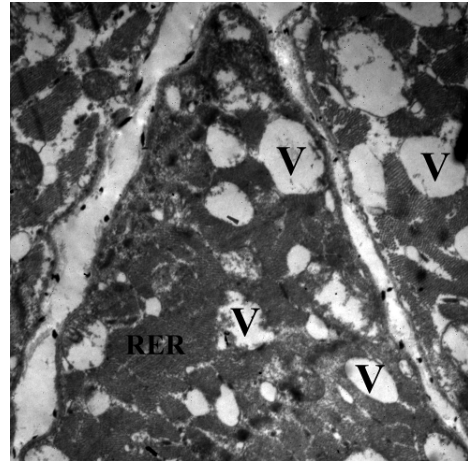
**Fig.2:** An electron micrograph of the stratum basal of the *grape seed irradiated group* at the third day post irradiation shows remnants of desmosomes (arrows) and the nuclei containing granulated chromatin as well as prominent nucleoli (N) and. X3000



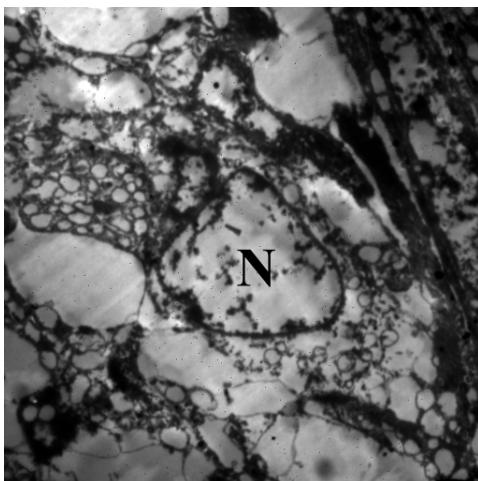
**Fig.3:** An electron micrograph of the stratum granulosum of the *irradiated group* at the third day post irradiation shows nucleus (N), kerato-hyaline granules (arrowheads) and Odland's bodies (arrows). X2000



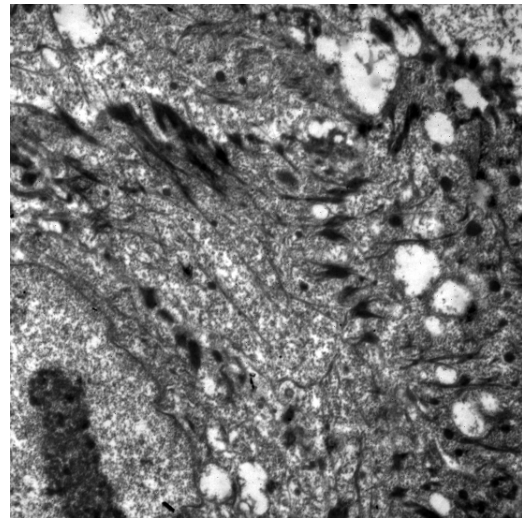
**Fig.4:** An electron micrograph of the keratin layer of the *grape seed irradiated group* at the third day post irradiation appears homogenous with an irregular surface. X3000



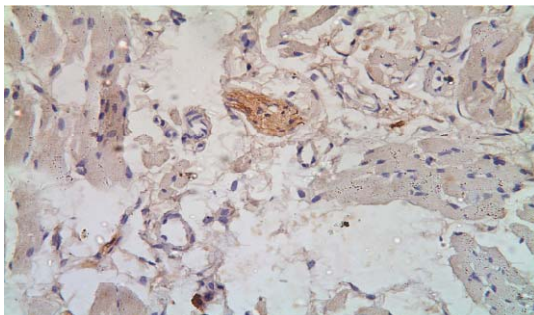
**Fig. 6:** An electron micrograph of the stratum basal of the *grape seed irradiated group* at the seventh day post irradiation shows rough endoplasmic reticulum (RER) and cytoplasmic vacuoles (V). X1000



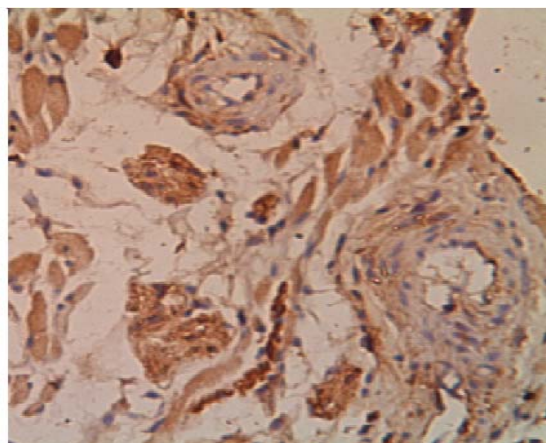
**Fig.5:** An electron micrograph of the fungiform papillae of the *irradiated group* at the seventh day post irradiation shows vacuoles of different sizes all over the cell and aborted nucleus (N). X1000



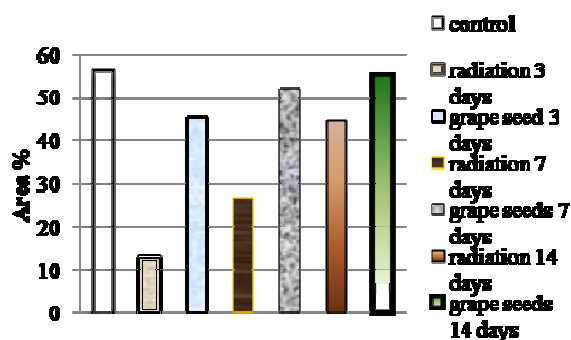
**Fig. 7:** An electron micrograph of the epithelium of the *grape seed irradiated group* at the fourteenth day post irradiation shows regenerated cytoskeleton and vacuolated cytoplasm. X2000



**← Fig. 8:** A photomicrograph of the tongue lamina propria of *irradiated group* at the seventh day after irradiation shows weak S100 immunoreactivity in the nerve fibers. S100x400



**Fig. 9:** A photomicrograph of the tongue lamina propria of *grape seed irradiated group* at the seventh day post irradiation shows moderate S100 immunoreactivity in the nerve fibers. S100x400



**Fig. 10:** A histogram shows the area percent of the innervations in the three groups at three, seven and fourteenth days post irradiation.

#### 4. Discussion

Patients with head and neck cancer are being treated more successfully with combined methods including radiation therapy in combination with chemotherapy, surgery or both. However, radiation therapy remains the primary method for treatment of patients with head and neck cancer [15,16]. **Zain and Hanks** [17] stated that there was no significant loss in the number of the fungiform papillae after a single dose of X-ray irradiation. However, they detected degenerative taste buds that regenerate after two weeks and matured at about thirty days. In 1997 **Obinata et al.** [18] found that lingual papillae and connective tissue papillae disappeared at day seven after irradiation. On the other hand, in radio-chemotherapeutic patients with taste disorders, laser scanning microscopy indicates changes of epithelia of fungiform papilla but no changes of the taste bud structure. Direct or indirect mucotoxic effects of

chemotherapeutic agents, and covering of taste pores by epithelial cells are likely reasons for taste loss during radio-chemotherapy [19]. **Yamazaki et al.** [20] revealed that there was not clear change in the spindle-shaped taste cells on day 4 after irradiation. The number of taste cells had decreased on day 8, and then remained unchanged until day 20, after which they increased and recovered to their original number by day 24. For these debates about the effect of radiation on fungiform or circumvallate papillae and taste buds that influence taste sensation directly or indirectly, the present study concerned with the epithelial changes that occurred in the fungiform papillae, neglecting their numbers, and the innervations of these papillae regardless the presence or absence of the taste buds.

The oral cavity has sometimes been described as a mirror that reflects the health of the individual. Changes indicative of disease are seen as alterations in the oral mucosa lining the mouth, which can reveal systemic conditions. Modern anticancer therapy represents a significant challenge to the integrity of the oral mucosa. Chemotherapeutic agents and radiation therapy limit the proliferative ability of the epithelium so that it becomes thin or ulcerated. This is manifest first in the more rapidly proliferating tissues, such as gastrointestinal and oral lining mucosa [21]. There may also be indirect effects, such as damage to the salivary glands that will reduce salivary production and impair barrier efficiency and a reduction in immunocompetence as a result of myeloablative therapy. This will increase the risk of local infection from oral organisms [22-24]. The ongoing study revealed degenerative nuclei as well as most of the cell organelles in the basal cell layer of the fungiform papillae of *IR group*. Multinucleated cells also could be detected. This histo-pathological finding was detected by **Obinata et al.** [18] and **Just et al.** [19]. **Yamazaki et al.** [20] also revealed that the basal cells of the mice circumvallate papillae had almost disappeared when exposed to a single 15 Gy dose of X-ray irradiation. This finding could be a hazard of the radiation that causes DNA damage in basal epithelial cells and generates reactive oxygen species. Further damage occurs to cells and blood vessels in the submucosa [25]. Meanwhile, the grape seed irradiated group revealed persistent nuclei and some of the cell organelles. This could be explained by the antioxidant effect of the grape seed extracts [26] that was performed by prevention of oxidative damage to cellular DNA [27,28]. Moreover, it was found that grape seed and skin have role in reduction of lipid peroxidation [29]. Lipid peroxidation could change the properties of biological membranes, resulting in severe cell damage [30]. These outcomes explain the integrity of the cell membranes that was

noticed from day three in the grape seed irradiated group. **Donnetti et al. 2009** [31] have performed immunofluorescence analysis of desmosomal cadherin expression (desmoglein 1/desmoglein 3) and demonstrated that the distribution of desmoglein 1 was not affected, whereas the expression of desmoglein 3 decreased in the suprabasal layers of irradiated samples. They suggested that this has consequences for the mechanical integrity of the mucosa and promotes the development of radiation mucositis. Persistent desmosomal junctions that were noticed in the grape seed irradiated group of the herein study suggested improvement effect of grape seed oil on these desmosomal cadherin.

Besides the foregoing mentioned epithelial changes that were perceived in this study and their possible effect on taste sensation, radiation-induced taste dysfunction could be also associated with damage to the nerve fibers. One of the most fascinating finding of the present investigation was significant reduction in the innervations of the fungiform papillae three days post irradiation. This reduction was greatly improved by feeding grape seed oil till reach to the normal level of innervations after fourteen days post irradiation. **Sollars et al.** [32] and **Sollars** [33] stated that changes in fungiform taste buds and papillae structure were occurred after chorda tympani transection nearly with similar pattern as was detected in this study. Thus the changes that were detected in this research could be of dual causes; the direct action of the radiation on the papillae and indirect effect on their innervation. **Sandow et al. 2006** [34] on the other hand, stated that radiation-induced taste dysfunction can be associated with damage to either the intraganglionic nerve cells or taste cells, or both. Because nerve fibers are non-dividing and do not proliferate, damage to these cells is unlikely to recover, and the related radiation-induced taste loss would not recover. However, damage to taste cells, which replenish approximately every 10 days, would likely recover at least partially, unless the proliferative capacity of the receptor cells is disrupted. In this study the nerve fibers regenerate especially in the grape seed irradiated group and thus taste sensation expected to be improved in this group.

### Conclusion

For these reasons, preservation of the oral mucosa integrity and their innervations, grape seed oil is recommended to be consumed as a dietary supplement and could be useful in synergizing the hazardous of radiation on the tongue papillae.

**Corresponding author**  
**Eman M El- Maghraby**

Health Radiation Research Department, National Centre for Radiation Research and Technology (NCRRT), Cairo, Egypt.  
[emey\\_maghraby@hotmail.com](mailto:emey_maghraby@hotmail.com)

### 5. References

1. Vissink A, Jansma J, Spijkervet FK, Burlage FR, Coppes RP. (2003): Oral sequelae of head and neck radiotherapy. *Crit Rev Oral Biol Med.*; 14:199–212.
2. Welge-Lussen A, Gudziol H. (2004): Schmeckstörungen: Ursache, Diagnostik und Therapie. *Ther Umsch.*; 61:302-7.
3. Pico JL, Avila-Garavito a, Naccache P. (1998): Mucositis: its occurrence, consequences and treatment in the oncology setting. *Oncologist.*; 3:446-51.
4. Uçüncü H, Ertekin MV, Yörük O, Sezen O, Ozkan A, Erdoğan F, *et al.* (2006): Vitamin E and L-carnitine, separately or in combination in prevention of radiation induced oral mucositis and myelosuppression: a controlled study in a rat model. *J Radiat Res (Tokyo).*; 47:91-102.
5. Shih A, Miaskowski C, Dodd MJ, Stotts NA, MacPhail L. (2002): A research review of the current treatments for radiation-induced oral mucositis in patients with head and neck cancer. *Oncol Nurs Forum.*; 29: 1063–80.
6. Scully C, Epstein J, Sonis S. (2003): Oral mucositis: a challenging complication of radiotherapy, chemotherapy, and radiochemotherapy: Part 1. Pathogenesis and prophylaxis of mucositis. *Head Neck.*; 25:1057–70.
7. Elting LS, Keefe DM, Sonis ST, Garden AS, Spijkervet FK, Barasch A, *et al.* (2008): Burden of Illness Head and Neck Writing Committee. Patient-reported measurements of oral mucositis in head and neck cancer patients treated with radiotherapy with or without chemotherapy: demonstration of increased frequency, severity, resistance to palliation, and impact on quality of life. *Cancer.*; 113:2704–13.
8. Peterson DE, Bensadoun RJ, Roila F. (2010): Management of oral and gastrointestinal mucositis: ESMO Clinical Practice Guidelines. *Ann Oncol.*; 21 (suppl 5): v261-v65.
9. Weiss JF and Landauer MR. (2000): Radioprotection by antioxidants. *Ann N Y Acad Sci.*; 899: 44-60.
10. Natella F, Bellelli F, Gentili V, Ursini F, Scaccini C. (2002): Grape seed proanthocyanidins prevent plasma postprandial oxidative stress in humans. *J Agric Food Chem.*; 50 (26):7720-5.
11. Busserolles J, Gueux E, Balasinska B, Piriou Y, Rock E, Rayssiguier Y, *et al.* (2006): In vivo

- antioxidant activity of procyanidin-rich extracts from grape seed and pine (*Pinus maritima*) bark in rats. *Int J Vitam Nutr Res.*; 76 (1):22-7.
12. Cetin A, Kaynar L, Koçyiğit I, Hacıoğlu SK, Saraymen R, Öztürk A, *et al.* (2008): The effect of grape seed extract on radiation-induced oxidative stress in the rat liver. *Turk J Gastroenterol. Jun*;19(2):92-8.
  13. Joshi SS, Kuszynski CA, Bagchi D. (2001): The cellular and molecular basis of health benefits of grape seed proanthocyanidin extract. *Curr Pharm Biotechnol.*; 2:187-200.
  14. Murakami T. (1974): A revised tannin-osmium method for noncoated scanning electron microscope specimens. *Arch Histol Jpn.*; 36:189-93.
  15. Shaha AR, Patel S, Shasha D, Harrison LB. (2001): Head and neck cancer. In: Lenhard RE Jr, Osteen RT, Gansler T (eds). *The American Cancer Society's Clinical Oncology*. Atlanta, Ga: American Cancer Society, 297-329.
  16. Department of veterans affairs laryngeal cancer study group (1991): Induction chemotherapy plus radiation therapy compared with surgery plus radiation in patients with advanced laryngeal cancer. *N Engl J Med.*; 324:1685-90.
  17. Zain R, Hanks CT. (1989): Morphological changes in taste buds of the fungiform papillae after a single dose of X-ray irradiation in rats. *Malays J Pathol.*; 11: 57-64.
  18. Obinata K, Ohshima H, Takano Y, Ito J. (1997): Early ultrastructural changes in the dorsal mucosa of rat tongue after irradiation, with special reference to the microvasculature. *Radiat Med.*; 15 (5):305-15.
  19. Just T, Pau HW, Bombor I, Guthoff RF, Fietkau R, Hummel T. (2005): Confocal microscopy of the peripheral gustatory system: comparison between healthy subjects and patients suffering from taste disorders during radiochemotherapy. *Laryngoscope.*; 115(12):2178-82.
  20. Yamazaki M, Fujii S, Ochiai A. (2010): Reduction of type II taste cells correlates with taste dysfunction after X-ray irradiation in mice. *Journal of Oral Pathology & Medicine.*; 39: 212–218.
  21. Christopher AS, Mary JK. (2001): Biology of Oral Mucosa and Esophagus. *J Natl Cancer Inst Monogr.*; 29: 7-15.
  22. Spielman AI. (1998): Chemosensory function and dysfunction. *Crit Rev Oral Biol Med.*; 9:267–91.
  23. Epstein JB, Emerton S, Kolbinson DA, Le ND, Phillips N, Stevenson-Moore P, *et al.* (1999): Quality of life and oral function following radiotherapy for head and neck cancer. *Head Neck.*; 21:1–11.
  24. Zheng WK, Inokuchi A, Yamamoto T, Komiyama S. (2002): Taste dysfunction in irradiated patients with head and neck cancer. *Fukuoka Igaku Zasshi.*; 93(4):64–76.
  25. Shea TC, Bruner R, Wiley JM, Serody JS, Sailer S, Gabriel DA, *et al.* (2003): An expanded Phase I/II trial of cyclophosphamide, etoposide, and carboplatin plus total-body irradiation with autologous marrow or stem cell support for patients with hematologic malignancies. *Biol Blood Marrow Transplant.*; 9: 443–52.
  26. Xu, C., Y. Zhang, L. Cao and J. Lu, (2010): Phenolic compounds and antioxidant properties of different grape cultivars grown in China. *Food Chem.*, 119: 1557-1565.
  27. Fan P, Lou H. (2004): Effects of polyphenols from grape seeds on oxidative damage to cellular DNA. *Mol Cell Biochem.*;267(1-2):67-74.
  28. Bagchi D, Sen CK, Ray SD, Das DK, Bagchi M, Preuss HG, *et al.* (2003): Molecular mechanisms of cardioprotection by a novel grape seed proanthocyanidin extract. *Mutat Res.*; 523-524:87-97.
  29. Shin MO and Moon JO. (2010): Effect of dietary supplementation of grape skin and seeds on liver fibrosis induced by dimethylnitrosamine in rats. *Nutr Res Pract.*; 4(5): 369–374.
  30. Parola M, Pinzani M, Casini A, Albano E, Poli G, Gentilini A *et al.* (1993): Stimulation of lipid peroxidation or 4-hydroxynonenal treatment increases procollagen alpha 1 (I) gene expression in human liver fat-storing cells. *Biochem Biophys Res Commun.*; 194:1044–50.
  31. Donetti E, Bedoni M, Capone P, Gualerzi A, Tartaglia G, Sforza C. (2009): An *in vitro* model of human oral explants to study early effects of radiation mucositis. *Eur J Oral Sci.*; 117 (2):169-74.
  32. Sollars SI, Smith PC, Hill DL. (2002): Time course of morphological alterations of fungiform papillae and taste buds following chorda tympani transection in neonatal rats. *J Neurobiol. Jun* 5;51 (3):223-36.
  33. Sollars SI. (2005): Chorda tympani nerve transection at different developmental ages produces differential effects on taste bud volume and papillae morphology in the rat. *J Neurobiol. Sep* 5;64(3):310-20.
  34. Sandow PL, Heirat-Yazdi M, Heft MW. (2006): Taste loss and recovery following radiation therapy. *JDR.*; 85(7): 608-11.