

Patch Angioplasty in Diffusely Diseased Left Anterior Descending Coronary Artery.

Emad Sarawy¹, Mahmoud El safty¹ and Ahmed Attia²

¹Cardiac Surgery Department, National Heart Institute (NHI), Egypt

²Mahalla Cardiac Center, Egypt

sarawy91@yahoo.com

Abstract: Background: Severely diseased left anterior descending coronary artery (LAD) is a surgical challenge and several procedures were suggested to achieve adequate reconstruction. **Aim of the work:** The aim of this study is to assess safety and surgical outcome of the use of patch angioplasty for the reconstruction of severely diseased LAD. **Material and methods:** In the period between January 2009 and January 2012, 40 patients (mean age 53.9 ± 7.9 years, 62.5% males) were chosen for reconstruction of a diffusely diseased left anterior descending coronary artery (LAD) with either left internal mammary artery (LIMA) patch or saphenous vein patch. Other associated significant coronary artery lesions were classically grafted with Inverted saphenous vein. **Results:** LAD patch was feasible in all cases and varied in length from 2-8 cm (4.8 ± 1.4 cm). Mean number of arterial and venous grafts was 2.1 ± 0.64 , mean aortic cross-clamp time and bypass times were 60.8 ± 18.2 and 80.2 ± 23 minutes, mean ICU and hospital stays were 44.9 ± 10.3 hours and 9 ± 3.2 days; respectively. There were one hospital mortality and one complications by deep sternal wound infection, patients were followed up from 1 month to 3 months. Mean postoperative NYHA class (1.2 ± 0.4) significantly improved, compared to the preoperative values (3.5 ± 0.51 ; $P < 0.001$). **Conclusions:** the use of LAD patch angioplasty is generally feasible and a safe alternative for the reconstruction of severely diseased LAD.

[Emad Sarawy, Mahmoud El safty and Ahmed Attia. **Patch Angioplasty in Diffusely Diseased Left Anterior Descending Coronary Artery.** *J Am Sci*2014;10(6s):8-12]. (ISSN: 1545-1003). <http://www.jofamericanscience.org>. 2

Key words: coronary artery bypass grafting, left anterior descending coronary artery, left internal mammary artery, LAD venous and or arterial angioplasty.

1. Introduction:

An increasing number of patients with a diffusely diseased LAD are referred for CABG, while a segmental stenosis is often treated with percutaneous intervention¹. Although combining endarterectomy to CABG was suggested for the management of the severely diseased LAD, yet we were reluctant in adopting the technique for the reports pointing to increased surgical risks and poor late outcomes, compared to CABG alone^{2,3}. On the other hand, extended revascularization with laying open the entire diseased LAD segment and patching it with either an *in-situ* left internal mammary artery (LIMA) on-lay patch⁴ without endarterectomy or venous patch with plaque exclusion appeared to be a safer approach that can minimize thrombogenicity and intimal proliferation associated with endarterectomy⁵. The aim of this study was to evaluate feasibility, early postoperative complications and early outcome of this suggested technique, combined with conventional CABG to other territories for diffuse coronary artery disease.

2. Patients and methods

In the period between September 2009 and February 2012, 40 patients were chosen for

reconstruction of a diffusely diseased left anterior descending coronary artery (LAD) with a left internal mammary artery LIMA patch or saphenous vein patch, at National heart institute and El mahalla cardiac center. We have followed the previously defined parameters where: an arterial patch angioplasty was defined as reconstruction of the LAD with a LIMA patch, without endarterectomy, for a length of at least 2 cm. venous patch when using saphenous venous patch with plaque exclusion for more than 2 cm and; a diffusely diseased LAD was defined as a diseased segment measuring 2 cm or more, involving the middle and distal thirds of the LAD^{4,1,6}.

Table 1 shows the patients' demographics. The age varied from 36 to 69 years, with a predominance of male sex (62.5%), diabetics (70%), hypertensive (60%) and smokers (65%). Patients benefited from the routine preoperative evaluation including; coronary angiography, echocardiography, ECG, complete blood picture, blood sugar levels, renal and hepatic functions and chest x-ray. Patients were operated through median sternotomy, aorto-bicaval cannulation and institution of cardiopulmonary bypass, under mild hypothermia. Myocardial protection was achieved by intermittent antegrade blood cardioplegia⁷, given initially for 3 minutes, then

for 1 minute after each distal anastomosis. Controlled reperfusion with normothermic blood was given for 3 minutes, before removal of the aortic clamp.

In general, distal anastomoses were performed first, followed by LAD patch either directly by LIMA or LIMA on venous onlay patch and ended with proximal anastomosis. LIMA was harvested pedicled well beyond its bifurcation. Dilute papaverine was injected from the distal divided end, and the LIMA was clipped distally. The diseased LAD segment was assessed and the arteriotomy was performed and extended distally and proximally as long as it takes to reach an acceptable LAD lumen. Saphenous vein patch was reconstructed to the lumen of LAD using 7/0 polypropylene. The LIMA was slit to match the coronary arteriotomy, and LIMA-to-LAD or LIMA-to-VEIN patch anastomosis was performed using 7/0 polypropylene. The aim of the patch is that about two-thirds of the reconstructed coronary artery is formed by the LIMA or vein patch. In the case the plaque is found to be ulcerated or fragile, the technique was left for the sake of other techniques, such as endarterectomy⁴.

The rest of the operation was routinely performed, with good hemostasis, closure in layers, respecting the usual indications for supportive drug therapy or insertion of an intra-aortic balloon pump. Patients were transferred to the ICU with routine monitoring, daily ECG, and enzyme analysis for the first 3 days. An echocardiogram was obtained on postoperative day 7; patients were discharged to be followed up at the outpatient clinic after 1 week, 1 month and then every 3 months.

3. Results

Operative data are shown in Table 2: seven patients benefited from patch angioplasty to LAD only (17.5%), 19 patients benefited from one additional saphenous vein graft (47.5%) and 14 patients benefited from 2 additional saphenous vein grafts (35%). The number of grafts implanted varied from 1 to 3 with a mean value of 2.1 ± 0.64 graft per patient. The length of the patch angioplasty varied from 2 to 8 cm with a mean value of 4.8 ± 1.4 cm. The aortic cross clamp and bypass times were varying from 13 to 88 minutes and 21 and 120 minutes; respectively. The respective mean times were 60.8 ± 18.2 and 80.2 ± 23 minutes. Only one patient needed the use of IABP to come out of bypass. He had 3 vessel disease, which were poor targets and his preoperative EF was 40%. This patient benefited from LIMA patch angioplasty to LAD and saphenous vein grafts to obtuse marginal and posterior descending coronary artery. His aortic cross clamp and by pass times were 60 and 110 minutes; respectively. The postoperative course was otherwise unremarkable.

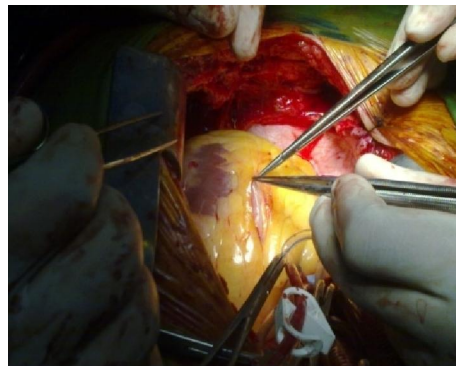


Figure (1) vein patch on LAD.

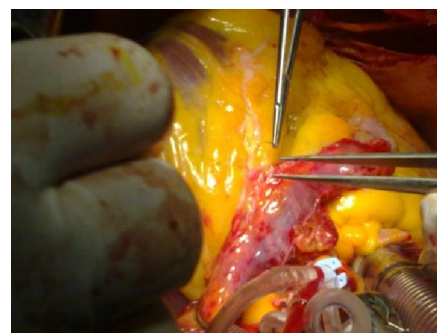


Figure (2) LIMA patch on LAD.

Table 1: Patients' demographic data (40 patients)

Age in years	53.9 ± 7.9
Sex male	25 (62.5%)
Diabetes mellitus	28(70%)
Hypertension	24 (60%)
History of smocking	26(65%)
Dyslipidemia	10 (25%)
NYHA FC	
Class III	19 (47.5%)
Class IV	21 (52.5%)
Mean NYHA	3.6 ± 0.52
Atrial fibrillation	4(10%)
Left main coronary artery disease	2 (6.6%)
Preoperative LVEDD (cm)	5.5 ± 0.69
Preoperative LVESD (cm)	3.77 ± 0.71
Preoperative EF%	54.7 ± 9.2

Values are presented as numbers (%) or mean \pm SD, as indicated. NYHA FC = New York heart association functional class, LVEDD = left ventricular end diastolic diameter, LVESD = left ventricular end systolic diameter, EF = ejection fraction.

In-Hospital outcomes are shown in Table 3. All patients were electively ventilated on the day of surgery and extubated along the classical criteria. The amount of postoperative blood loss was remarkable, however one patient was re explored for bleeding and

one mammary branch was found and clipped. One-third of patients needed positive inotropic support that was tailed over 12 to 48 hours. There was one postoperative mortality from persistent ventricular arrhythmias and one serious deep sterna wound infection which operated upon later and discharged well. There was no stroke, renal or hepatic failure. No patient developed postoperative myocardial infarction as shown by ECG or enzymatic analysis; including the case in whom intraoperative insertion of IABP was carried out. ICU stay varied from 30 to 72 hours, with

a mean of 44.9 ± 10.3 hours. Hospital stay varied from 6 to 17 days, with a mean of 9 ± 3.2 days.

Patients were followed up from 1 month to 3 months. As shown in Table 3, patients showed an overall improvement; with 29 patients (72.5%) being improved by 2 NYHA classes and 11 patients (27.5%) being improved by 3 NYHA classes. The mean postoperative NYHA class (1.2 ± 0.4) was significantly lower than the preoperative values (3.6 ± 0.52 ; $P < 0.001$).

Table 2: operative variables

Aortic cross clamp time (minutes)	60.8 ± 18.2
Bypass time (minutes)	80.2 ± 23
Patch size (cm)	5.1 ± 1.8
Vessel grafted :	
- LIMA patch to LAD	28(70%)
- VEIN patch to LAD	12(30%)
- patch angioplasty to LAD only	7 (17.5%)
- patch angioplasty to LAD + SVG to diagonal	6 (15%)
- patch angioplasty to LAD + SVG to diagonal and OM	7 (17.5%)
- patch angioplasty to LAD + SVG to OM	8(20%)
- patch angioplasty to LAD + SVG to PDA	5 (12.5%)
- patch angioplasty to LAD + SVG to OM and PDA	7 (17.5%)
Need of IABP	1 (2.5%)

Values are presented as numbers (%) or mean \pm SD, as indicated. LIMA= left anterior descending coronary artery, SVG = saphenous vein graft, OM = obtuse marginal coronary artery, PDA = posterior descending coronary artery, IABP = intra-aortic balloon pump.

Table 3: In-Hospital and Follow-up outcomes (30 patients)

A) In-Hospital outcomes:	
Need for inotropes	20 (50%)
Postoperative arrhythmia	7 (17.5%)
Postoperative bleeding (ml)	566 ± 292.8
Duration of mechanical ventilation (hours)	8.4 ± 4.6
ICU stay (hours)	44.9 ± 10.3
Hospital stay (days)	9 ± 3.2
Postoperative LVEDD (cm)	5.6 ± 0.8
Postoperative LVESD (cm)	3.74 ± 0.65
Postoperative EF%	54 ± 8.3
B) Follow-up outcomes	
Early mortality	1 (2.5%)
NYHA FC class (3 months after surgery)	
NYHA class I	32 (80%)
NYHA class II	8 (20%)
Mean postoperative NYHA	1.2 ± 0.4
NYHA FC class improvement (3 months after surgery)	
Patients improving by 2 NYHA classes	21 (70%)
Patients improving by 3 NYHA classes	9 (30%)
Mean NYHA improvement*	2.4 ± 0.12

Values are presented as numbers (%) or mean \pm SD, as indicated. NYHA FC = New York Heart association functional classification, * means of the differences of the preoperative NYHA FC subtracted from the postoperative NYHA FC.

4. Discussion

Incomplete revascularization, especially when it involves the LAD, is one of the most important factors influencing long-term mortality and morbidity after coronary bypass surgery.¹⁵

With the increased use of percutaneous interventions by invasive cardiologists, the number of high-risk patients referred for CABG operation has increased⁶. Among this population are patients with diffuse coronary disease who were before deemed inoperable and managed medically, with substantial number having persistent symptoms and restricted physical activity⁴. With a diffusely diseased LAD that is frequently encountered in this patient population, complete myocardial revascularization is hardly achieved by conventional bypass techniques^{8,6}, and the long-term patency of a LIMA to LAD graft is usually jeopardized by the multiple atheromatous plaques⁹; several technical variations and surgical combinations have been suggested to reconstruct the diffusely diseased LAD that included: jumping anastomosis and creation of more than one bypass to the LAD territory, endarterectomy, venous patch angioplasty followed by LIMA anastomosed on the patch¹⁰ and extended LIMA patch angioplasty, with or without endarterectomy^(1,6,11-13).

Our technique involves extended arteriotomy to the non-diseased LAD portion excluding all major plaques from the neo-coronary lumen while retaining all patent perforators and diagonals in the reconstructed coronary. Prabhu and colleagues advise to stop angioplasty just distal to the most proximal critical lesion so as to prevent competitive flow^{4,14}, which perfectly suits their off-pump technique. Barra and colleagues manage to exclude the atheromatous plaques from the lumen of the LAD, so as at the end of the procedure 75% of the newly formed LAD originates from the LITA and 25% originates from the native artery floor¹². On the other hand, major series promote combining endarterectomy to mammary artery patch angioplasty for the ability of the former to relieve the myocardium supplied by the equally diffusely diseased side branches from ischemia; an advantage that could not be achieved by any extension of the arterial grafting¹. The technique and extent of endarterectomy are also subjects of debate. For some, endarterectomy should be limited^{6,12}, others advocate for more liberal use with total removal of the plaque under direct vision^{11,17}.

We agree with Fukui that endarterectomy should be avoided if possible because the rate of postoperative myocardial infarction after endarterectomy was higher than that after long segment CABG with plaque exclusion in his study,

Moreover, the rate of transfusion and reexploration for bleeding were higher after endarterectomy.¹

We are still reluctant to combine endarterectomy to our technique, even if the early as well as the late results of more recent series have been acceptable and that the whole procedure can be safely performed off-pump^{1,11,13,14}. We still believe that in part, endarterectomy will add complexity to surgery for the need of a longer arteriotomy, more operative time, more blood loss and increased hospital mortality¹⁵. In another part, arteriotomy is a powerful trigger of the coagulation cascade by the lack of endothelium in the early stages and myofibro-intimal proliferation in the late stages¹⁵.

In our study, despite of the complexity of the technique, aortic cross-clamp and bypass times were reported to be comparable with those recorded in conventional CABG⁶; which was not the case in this early experience. For the same reason, we were not comfortable to do those cases off-pump, even if major series reported adequate feasibility and safety^{1,4,13}.

There is a general agreement that extended LAD revascularization carries a surgical risk and should be only performed when necessary¹¹. Tasdemir and colleagues have shown that the procedure was associated with 4 folds hospital mortality and 5-6 folds of in-hospital MI, compared to conventional CABG¹¹. The reported hospital mortality varied between <1% - 6.5%¹². The reported surgical risk of a combined endarterectomy was controversial. Tasdemir and colleagues reported non-significant lower rates of MI and mortality¹¹, while Fukui and colleagues have demonstrated a statistically significant higher rate of perioperative MI in this subgroup of patients, compared to those benefiting from angioplasty alone¹. We had one hospital mortality and no and cerebrovascular stroke, renal or hepatic complications, one case of re exploration for bleeding and one serious deep sterna wound infection. Patients achieved significant hemodynamic improvement as evident by statistically significant NHYA class reduction. On the other hand, we had a remarkably high postoperative blood loss, need of positive inotropic support in as much as one-third of cases and IABP in only 1 case. These results may be explained by our relatively young population as well as careful patient selection.

Our patients were followed up from 1 month to 3 months (9.5 ± 3.4 months) and 4 patients (10%) needed ICU admission for unstable angina (2 patients; 5%) or cardiac arrhythmia (2 patient; 5%).

In conclusion: The LAD reconstruction using LIMA patch or vein patch angioplasty can be performed with acceptable early results,

Study limitations: our sample is small and no comparable group was included, we considered the patients underwent LIMA and VEIN patch angioplasty the same, also we need long term results.

References

1. Fukui T, Takanashi S, Hosoda Y. Long segmental reconstruction of diffusely diseased left anterior descending coronary artery with left internal thoracic artery with or without endarterectomy. *Ann Thorac Surg* 2005; 80:2098–105.
2. Sommerhaug RG, Wolfe SF, Reid DA, Lindsey DE. Early clinical results of long coronary arteriotomy, endarterectomy and reconstruction combined with multiple bypass grafts for severe coronary artery disease. *Am J Cardiol* 1990; 66:651–9.
3. Goldstein J, Cooper E, Saltups A, Boxall J. Angiographic assessment of graft patency after coronary endarterectomy. *J Thorac Cardiovasc Surg* 1991;102:539–44.
4. Prabhu AD, Thazhkuni IE, Rajendran S, Thamaran RA, Vellachamy KA, Vettath MP. Mammmary artery patch reconstruction of left anterior descending coronary artery. *Asian Cardiovasc Thorac Ann*. 2008 Aug;16(4):313-7.
5. Sundt TM 3rd, Camillo CJ, Mendeloff EN, Barner HB, Gay WA Jr. Reappraisal of coronary endarterectomy for the treatment of diffuse coronary artery disease. *Ann Thorac Surg* 1999; 68:1272–7.
6. Ogus TN, Basaran M, Selimoglu O, Yildirim T, Ogus H, Ozcan H, Us MH. Long-term results of the left anterior descending coronary artery reconstruction with left internal thoracic artery. *Ann Thorac Surg*. 2007 Feb;83(2):496-501.
7. Guyton RA, Gott JP, Brown WM, Craver JM. Cold and warm myocardial protection techniques. *Adv Card Surg*. 1996;7:1-29.
8. Caparrelli DJ, Ghazoul M, Diethrich EB. Indications for coronary artery bypass grafting in 2009: what is left to surgery. *Gen Thorac Cardiovasc Surg*. 2011 Jan;59(1):6-13. Epub 2011 Jan 12.
9. Sirivella S, Gielchinsky I, Parsonnet V. Results of coronary artery endarterectomy and coronary artery bypass grafting for diffuse coronary artery disease. *Ann Thorac Surg* 2005;80:1738–44.
10. Santini F, Casali G, Lusini M, *et al*. Mid-term results after extensive vein patch reconstruction and internal mammary grafting of the diffusely diseased left anterior descending coronary artery. *Eur J Cardiothorac Surg* 2002;21:1020 – 5.
11. Tasdemir O, Kiziltepe U, Karagoz HY, Yamak B, Korkmaz S, Bayazit K. Long term results of reconstructions of the left anterior descending coronary artery in diffuse atherosclerotic lesions. *J Thorac Cardiovasc Surg* 1996;112:745–54.
12. Barra JA, Bezon E, Mondine P, Resk A, Gilard M, Boshat J. Coronary artery reconstruction for extensive coronary disease: 108 patients and two year follow-up. *Ann Thorac Surg* 2000;70:1541–5.
13. Fukui T, Tabata M, Taguri M, Manabe S, Morita S, Takanashi S. Extensive reconstruction of the left anterior descending coronary artery with an internal thoracic artery graft. *Ann Thorac Surg*. 2011 Feb;91(2):445-51
14. Eryilmaz S, Inan MB, Eren NT, Yazicioglu L, Corapcioglu T, Akalin H. Coronary endarterectomy with off-pump coronary artery bypass surgery. *Ann Thorac Surg* 2003;75:865–9.
15. Byrne JG, Karavas AN, Gudbjartson T, *et al*. Left anterior descending coronary endarterectomy: early and late results in 196 consecutive patients. *Ann Thorac Surg* 2004;78:867–73.
16. Lawrie GM, Morris GC Jr, Silvers A, *et al*. The influence of residual disease after coronary bypass on the 5-year survival rate of 1274 men with coronary artery disease. *Circulation* 1982; 66:717–23.

6/22/2014