

Role of Diffusion-weighted MR Imaging in diagnosis of intra-axial contrast enhanced brain masses

Ali Abdel-Fattah Alsyed Esmael, Mahmoud Abu-el-fadl; Mustafa Motawe, Ismail Badawy, Seham Abbas Aly and Emad Fawzy

Radiology & Neurology Departments, Faculty of medicine, Al-Azhar & Benha university
ali_helil@yahoo.com, isia992018@yahoo.com

Abstract: Differentiation of intra-axial brain masses with conventional MRI or CT imaging is difficult especially neoplastic from non neoplastic masses. Advanced MR imaging techniques, such as diffusion weighted MR imaging, perfusion MR imaging and MR spectroscopy can further improve the diagnostic accuracy of conventional CT and MR imaging. Diffusion-weighted MR imaging may detect inflammatory processes, whereas characteristics of peritumoral area may help to distinguish between metastases and glioblastomas. In solid tumors DWI, may also aid the differentiation between low grade gliomas and malignant tumors. Diffusion-weighted MR imaging also provides adjunctive information for detection of demyelinating processes. Diffusion-weighted MR imaging has an important role in diagnosis & differential diagnosis of the ring enhanced intracranial lesions with the conventional MR sequences after IV contrast injection. **Purpose:** To determine the accuracy of a Diffusion-weighted MR imaging in diagnosis and to differentiate and characterize the intra-axial enhancing focal lesions, according to its histopathological findings or clinical diagnosis. **Materials and Methods:** 40 patients (25 men and 15 women), mean age, 34.5 years) with neurological symptoms with or without previous investigations were enrolled into this study. **Results:** Search results showed 10 patients with high-grade and 5 with low-grade primary neoplasm, 10 with abscesses, 4 with lymphoma, 8 with demyelinating diseases, and 3 with metastases. Those lesions revealed different patterns of DW and ADC values. **Conclusion:** Diffusion-weighted MR imaging is significant in diagnosis and accurate in differentiation of several intra-axial brain focal lesions.

[Ali Abdel-Fattah Alsyed Esmael, Mahmoud Abu-el-fadl,; Mustafa Motawe, Ismail Badawy, Seham Abbas Aly and Emad Fawzy. **Role of Diffusion-weighted MR Imaging in diagnosis of intra-axial contrast enhanced brain masses.** *J Am Sci* 2013;9(5):131-139]. (ISSN: 1545-1003). <http://www.jofamericanscience.org>. 18

Keywords: weighted MR; Imaging; diagnosis; intra-axial; brain; mass

1. Introduction:

The brain is complex and full of glial, globular, membranes and other structures, which may or may not allow water to move freely. Because water spins will run into constituents of cells of different concentrations in different cellular compartments, they will spread at different rates when labeled with the “magic ink”. In addition, they will not behave in the same way when they are moving in different directions. The former is measured as the diffusion rate, diffusion coefficient, or simply diffusivity, depending on the unit used, and the latter is more formally described as diffusion anisotropy [1–2].

The aim:

The aim of this work is to determine the role of Diffusion imaging in diagnosis and differentiation of different intra-axial lesions.

2. Patients' and methods:

In this study 40 patients (25 men and 15 women), mean age, 34.5 years) in the period between January 2010 and September 2012 at Al-Azhar University hospitals and Al-Amin National hospital KSA.

Criteria of selection:

We have chosen our patients 1) with neurological symptoms of gradual onset and progressive course. 2) Age above 20 years old

Criteria of exclusion:

- 1) We excluded patients younger than 20 years. Patients younger than 20 years were not included because some pediatric brain tumors are known to have different imaging characteristics.
- 2) Extra-axial lesions
- 3) Focal lesions with immunodeficiency virus.
- 4) Post-operative patients except our patients included in this study for follow up.
- 5) Non enhancing lesions.
- 6) Patients with hyper-acute neurological deficit without history of previous pathology
- 7) Patients with bad general condition.
- 8) Post-traumatic patients

All patients presented with neurological symptoms & were subjected to medical history and thorough clinical examination: (general & neurological examination), ECG, Chest X ray, abdominal US, laboratory complete investigations, carotid Duplex Doppler US, CT and MRI examinations.

All patients underwent MR imaging with a 1.5-T systems (Philips super conducting Magnet system, signa prospeed Lx) at Sayed Galal university hospital and 1.5 –T GE system at Al-Ameen national hospital-Taif KSA.

The imaging protocol includes:

- 1- Three planes localizer: very rapid localizer sequences were taken.
 - 2- Axial T2 FSE with TR/TS : 6000/85 , ETL20 ,field of view : 24 , slice thickness /space :5/2 , matrix : 256 x 192 ,NEX :2, time of acquisition: 1 minute 21sec
 - 3- Axial T1SE with TR/TE : 600/28 acquisition time : 1minute 18 sec
 - 4- Axial FIAIR sequence TR/TE: 10000/100 interval time 2200 acquisition time: 1minute 25 sec
 - 5- Axial Diffusion sequence: (10000/118; field of view, 300 mm; section thickness, 5mm; number of signals acquired, one) by using sequential application of diffusion-sensitizing gradients(b values, 0 and 1000 sec/mm2) in three orthogonal (x,yandz) directions.
- Post processing of ADC map was also performed with standard software at a single workstation (FuncTool, version2; GE Medical System).
- 6 - Axial T2 * gradient echo sequence: TR / TE: 550/15, flip angle 20, field of view : 30,slice thickness/space 5/2, with acquisition time: 2minte 28 sec ((to exclude hyper acute hemorrhage))
 - 7- Coronal Diffusion sequence: acquisition time 25 seconds
 - 8- Rabid MRA, 3D TOF sequence for the carotid and vertebra-basilar circulation, acquisition time :6 minutes 30 sec, parameters: TR/TE : 36/7 ,flip angle 20 ,field of view :18.slice thickness 1.4

- overlap 1 ,locations per slab :60 ,frequency encoding 256 , phase encoding 192 Nex 1.
- 9- T1WI with contrast: IV administration of 0.1 – mmol/kg of gadolinium, single shot spin-echo echoplanner images were obtained.

3. Results: (Figs.1-5) and (Tables 1-6)

40 patients had imaging criteria of sub-acute or chronic neurological symptoms (10 cases of high grade glioma, 5 cases of low grade glioma, 4 cases of lymphoma and 3 cases of metastases, 10 cases of abscesses & 8 cases of MS), conventional MRI study, T1 with contrast, Diffusion &ADC map were done We classify masses according to pattern of enhancement to:

- 1) Heterogeneous enhancement: 1 abscess, 3 cases of lymphomas, 8 cases of high grade glioma, 4 cases of MS, 5cases of low grade glioma.
- 2) Rim enhancement: 9 cases of abscesses, 1 case of lymphoma, 2 cases of high grade glioma, 4 cases of MS, one of them shows complete ring and 3 show incomplete ring enhancement.

According to Diffusion to:

- 1) Diffusion facilitated:1 abscess, 10 high grade glioma, 3 low grade glioma, 7 cases of MS, 3 cases of metastases.
- 2) Diffusion restricted: 9 abscess, 2 cases of low grade glioma, 4 cases of lymphoma, 1 case of MS.

Table (1): Classification of intra-axial masses according to pattern of enhancement and Diffusion criteria:

Number of cases	Diffusion and contrast enhancement patterns			
	Facilitated	Restricted	Heterogenous	Rim
Cases(n=40)	24	16	22	18
	1 abscess 10 high grade glioma(HGG). 3 low grade glioma(LGG). 3 metastases. 7 MS	9 abscess. 2 low grade glioma. 4 lymphoma. 1 MS	1 abscess. 8 high grade glioma. 4 low grade glioma. 2 metastases. 4 MS. 3 lymphoma.	9abscess. 4 MS. 2 high grade glioma. 1 low grade glioma. 1 metastases. 1 lymphoma.
Diffusion+enhancement	Heterogenous+ facilitated=18(1 abscess, 8HGG, 3LGG, 2 metastases,4MS)	Heterogeneous + restricted=4 (3lymphoma, 1LGG)	Rim+facilitated=6(2HGG,3MS,1 metastases)	Rim+restricted=12(9abscess, 1lymphoma, 1MS&1LGG)

Table (2): ADC measurements of different intra-axial lesions: data x 10 -3 mm2/sec

Lesion type			
	Mean	±SD	
Glioma (n=15)	1.96	1.86	
Lymphoma (n=4)	0.91	0.26	
Metastasis(n=3)	1.42	1.12	
Abscess(n=10)	0.89	0.56	
MS(n=8)	1.41	0.46	

According to pattern of enhancement, Diffusion & ADC map we calculated the diagnostic accuracy, sensitivity, specificity in:

- (1) Discrimination of neo plastic from non-neo plastic disease, in which a true-positive finding is defined as a neoplasm classified as a neoplasm, a true negative finding is defined as a non neoplasm classified as a non-neoplasm, a false positive finding is defined as a non neoplasm classified as a neoplasm, and a false-negative finding is defined as a neoplasm classified as a non neoplasm.
- (2) Discrimination of high-grade from low-grade neoplasm, in which a true-positive finding is defined as a high grade neoplasm classified as a high-grade neoplasm, a true negative finding is defined as a low grade neoplasm classified as a low grade neoplasm, a false positive finding is defined as a low grade neoplasm classified as a high grade neoplasm and a false negative finding is defined as high grade neoplasm classified as a low grade neoplasm.
- (3) Discrimination of high grade neoplasm and lymphoma from low grade neoplasm and non neoplastic disease, in which a true-positive finding is defined as a high grade neoplasm or lymphoma classified as a high grade neoplasm or lymphoma, a true-negative finding is defined as a low grade neoplasm or non neoplastic disease classified as a low grade neoplasm or non neoplastic disease, a false positive finding is defined as low grade neoplasm or lymphoma, and a false negative finding is defined as a high grade neoplasm or lymphoma classified as a low grade neoplasm or non neoplastic disease.
- (4) Discrimination of different types of non-neoplastic lesions.

Table 3: Statistical analysis of the diagnostic accuracy & predictive value of diffusion & ADC in discrimination of neoplastic from non neoplastic cases

	Results			
	True +ve	False +ve	True -ve	False -ve
Cases(n=40)	19	2	16	3
Accuracy	Sensitivity	Specificity	+ve predictive	-ve predictive
=87.5%	=86.3%	=88.8%	=90.4%	=84.2%

We incorrectly diagnose 1 case of MS as a lymphoma, 1 abscess as a high grade glioma, 1 lymphoma and 1 low grade glioma as an abscess.

Table 4: Statistical analysis of the diagnostic accuracy & predictive value of diffusion & ADC in discrimination of high grade neoplasm and lymphoma from low grade glioma and non neoplastic cases

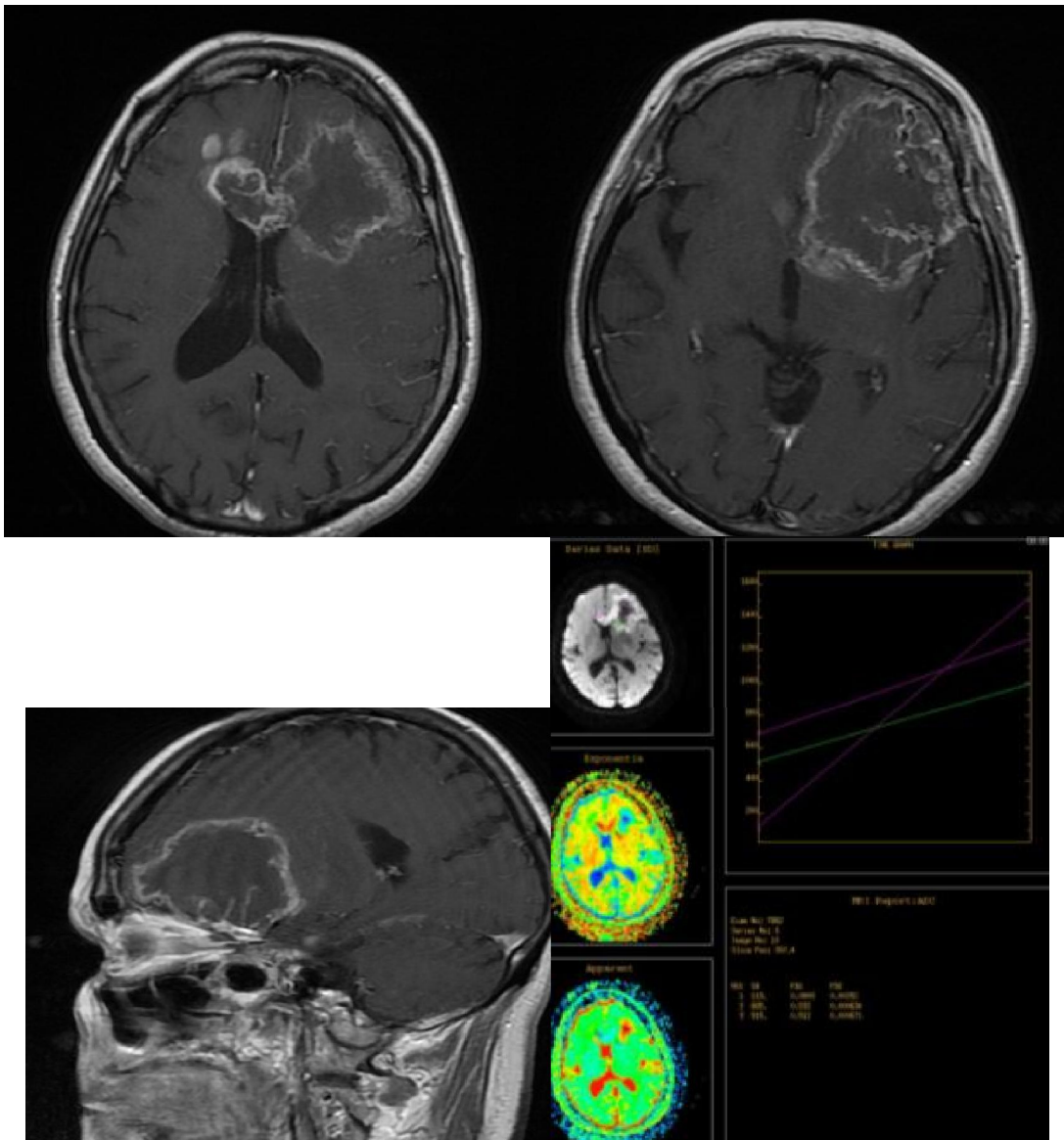
	Results			
	True +ve	False +ve	True -ve	False -ve
Cases(n=40)	16	5	18	1
Accuracy	Sensitivity	Specificity	+ve predictive	-ve predictive
=85%	=94.1%	=78.2%	=76.1%	=94.7%

Table 5: Discrimination of high grade neoplasm (HGG & metastases) from low grade neoplasm (10 HGG, 3 metastases, 5LGG)

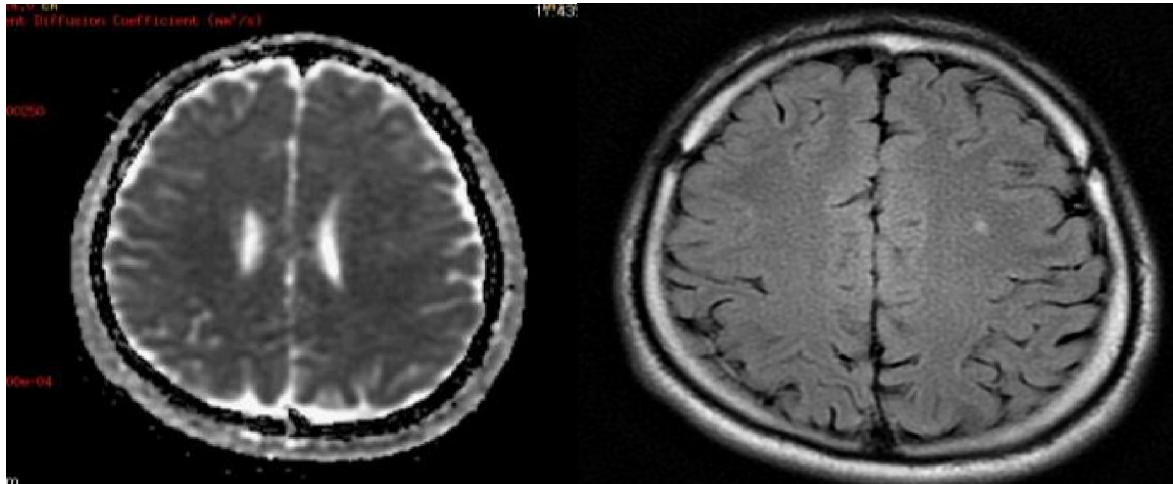
	Results			
	True +ve	False +ve	True -ve	False -ve
Cases(n=18)	10(8 HGG & 2 metastases) heterogeneous enhancement+ facilitated	3 (LGG, heterogeneous + facilitated diffusion)	2 (LGG, restricted diffusion)	3(2 HGG, 1 metastases, rim+ facilitated)
Accuracy	Sensitivity	Specificity	+ve predictive	-ve predictive
=66.6%	76.9%	=40%	=76.9%	=40%

Table(6) classification of benign lesions according to imaging criteria (enhancement pattern, Diffusion& ADC)

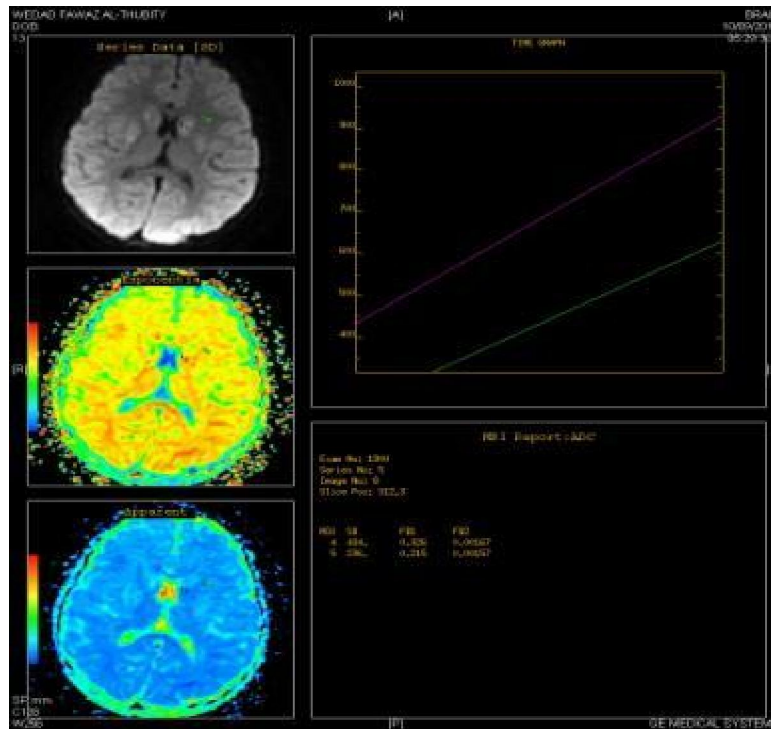
	Benign lesions=18			
	True +ve	False +ve	True -ve	False -ve
Abscess = 10	9 (rim enhancement + restricted diffusion)	2 (1 LGG & 1 lymphoma + restricted diffusion+ rim enhancement)	8 (cases of MS)	1 (heterogenous enhancement +facilitated diffusion)
MS=8	7 (facilitated diffusion + 4 heterogeneous enhancement, 3 incomplete rim enhancement)	0	10 (all cases of abscesses)	1(complete rim enhancement+ restricted diffusion)



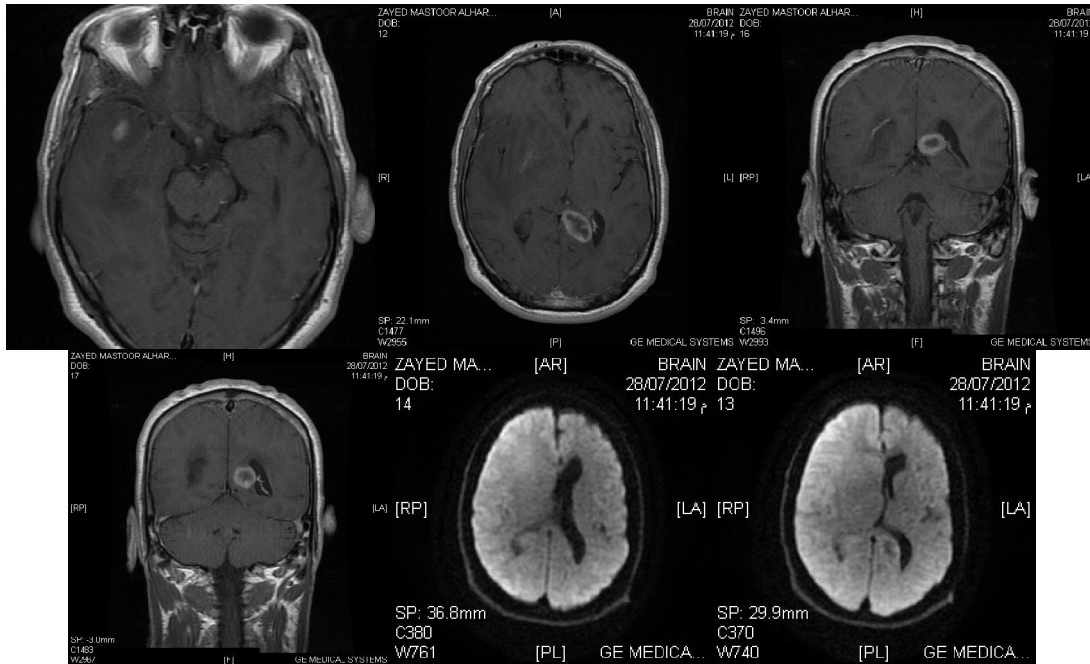
Case;1) Left frontal glioblastoma multiforme in 55 years old man: irregular ring enhancement of non-uniform thickness pattern with adjacent tissue infiltration, facilitated diffusion, the highest ADC(10000/118; b values, 0 and 1000 sec/mm²) = 1.46x10⁻³mm²/sec(necrosis has a higher ADC than enhancing areas)



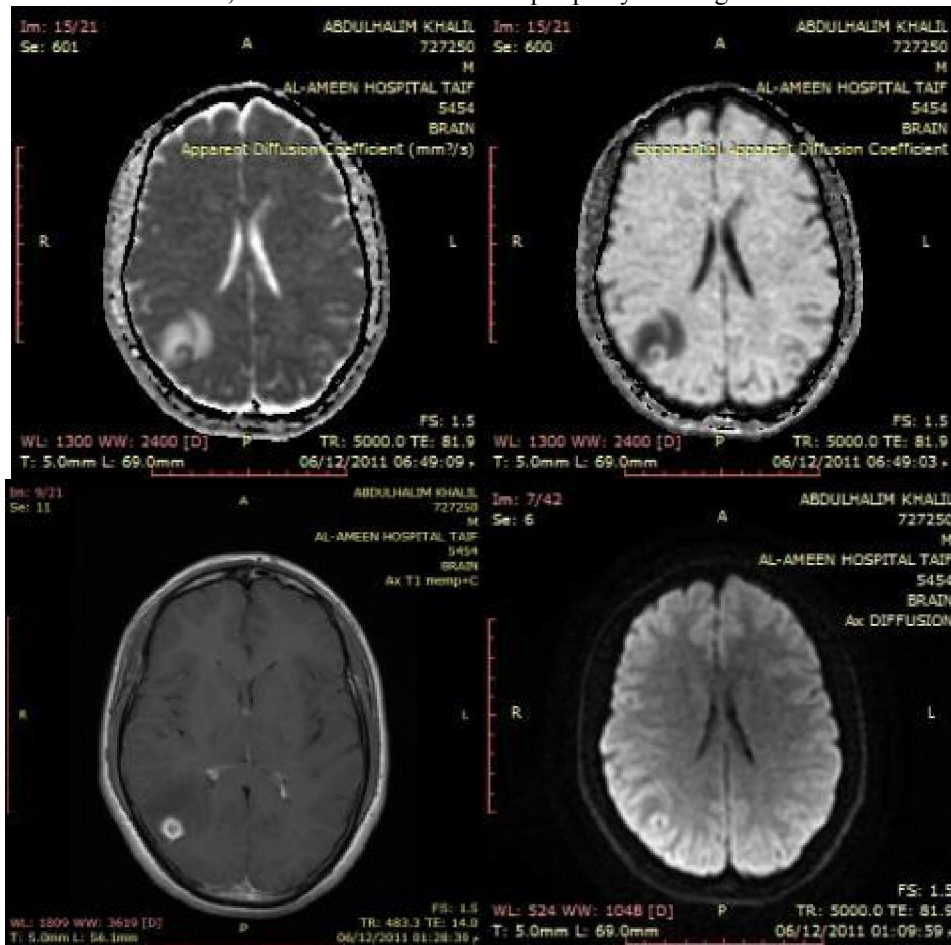
Case; 2) Multiple sclerosis: The plaques show diffusion facilitation and high ADC values= $1.33 \times 10^{-3} \text{mm}^2/\text{sec}$:

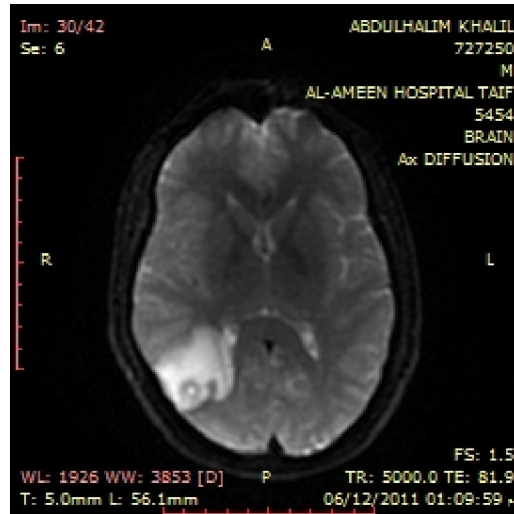


3) Mitochondrial disease: basal ganglia, corpora striata small mild DW hyper-intensity (mild diffusion restriction), mild low ADC values.



4)Right parietal&temporal and left occipital metastases :the parietal appears ill defined+heterogenous enhancement, the right temporal and left occipital show ring irregular enhancement at T1 +C , DWI shows mild high signal intensity at the centre of the tumor, diffusion facilitation at the periphery with high ADC values=1.42x10-3mm/sec.





5) Right occipital abscess: DWI: Abscess cavities are homogeneously hyperintense on DW MR images with low ADC, the signal intensity of the abscess cavity (central portion) is markedly higher and the ADC ratios are markedly low= $0.69 \times 10^{-3} \text{mm}^2/\text{sec}$.

4. Discussion:

Diffusion-weighted imaging can provide valuable information about tumor cellularity and help in the characterization and grading of tumors of the brain. In most situations, it is difficult to differentiate between specific tumors and to determine tumor infiltration. DWI distinguishes cytotoxic from vasogenic edema in complicated cases; especially helpful for evaluation of new deficits following tumor-resection. (1, 2, 4, 5).

Future studies will show whether diffusion tensor imaging can improve our ability to characterize and grade brain tumors on imaging studies.(14). Many authors⁽¹⁵⁻¹⁷⁾, demonstrated that tumor and edema have higher ADCs than do's normal brain tissue and that central necrosis has a higher ADC than do tumor, edema, or normal brain tissue, the present study confirmed that results. Tien et al. (15) demonstrated that enhancing tumors have significantly lower ADCs than does adjacent edema, but Brunberg et al. (16) found that there is no significant difference between ADCs of enhancing tumor and edema. Both concluded that the ADC alone cannot be used to differentiate a nonenhancing tumor from adjacent edema. Brunberg et al. suggested that both enhancing and non-enhancing tumors can be distinguished from edema because edema has significantly higher indices of diffusion anisotropy when compared with adjacent tumor, presumably due to intact myelin within the edema. Demarcation of tumor from surrounding vasogenic edema with DW MR imaging is important in determining radiation ports, surgical margins, and biopsy sites. A number of investigators (16-18-19) have demonstrated that DW MR imaging cannot be used to differentiate between high- and low-grade

gliomas or between tumor types. Osborn, et al found that there is no diffusion restriction is typical but diffusion tensor imaging of white matter may help surgical planning in future. DW MR imaging is also valuable in the assessment of tumor resections that are complicated, in the immediate postoperative period, by acute neurologic deficits. Although both extracellular edema and infarction are hyperintense on spin-echo T2-weighted images, cytotoxic edema is characterized by a low ADC, and vasogenic edema is characterized by a high ADC, relative to brain parenchyma. Thus, an acute infarction can easily be differentiated from postoperative edema.

In intracranial infections, the present study revealed characterizations of the pyogenic infection & its DD of the ring enhanced lesions, primary neoplasm, metastasis, demyelination, resolving clot and subacute infarct. Abscess cavities and empyemas are homogeneously hyperintense on DW MR images, with signal intensity ratios of abscess cavity to normal brain tissue that range from 2.5 to 6.9 and with ADC ratios range from = 0.87 to $0.53 \times 10^{-3} \text{mm}^2/\text{sec}$ (20-21). In one study (22), the ADC of the abscess cavity in vivo was similar to that of pus aspirated from the cavity in vitro. In another study (21), the ADC ratio of empyema compared with CSF was 0.13 in one patient. The relatively restricted diffusion most likely results from the high viscosity and cellularity of pus. Although intracranial abscesses and intracranial neoplasms may appear similar on images obtained with conventional MR sequences, the signal intensity of the abscess cavity (central portion) is markedly higher and the ADC ratios are markedly lower than those of necrotic tumors on DW MR images, we confirmed the results of (15, 16, 20, 4) in addition, the

primary or metastatic neoplasm have a thick nodular enhancing wall (4). Other ring enhanced lesions as resolving hematoma, has a history of trauma or vascular lesion with conventional MRI manifestations of blood products, demyelination has enhancement often incomplete ring, characteristic lesions elsewhere in brain & less amount of mass effect for size of the lesion, subacute infarct, has a history of stroke, vascular distribution & gyriform enhancement. (4) Bacterial meningitis may be complicated by subdural effusions or subdural empyemas, which are difficult to differentiate on conventional MR images

In multiple sclerosis, acute lesions show concentric ring pattern on diffusion-weighted images with hyperintense rim. Inactive MS plaques show variable ADC, anisotropic values, not statistically different from normal appearing white matter.

Active plaque centers show increased ADC & low anisotropy. Subacute & chronic lesions show intermediate increased ADC & moderate decreased anisotropy. (4)

The elevated diffusion in active stages may result from an increase in the size of the extracellular space due to edema and demyelination acutely and to axonal loss and gliosis chronically. In rare instances, acute plaques have restricted diffusion. This may result from increased inflammatory cellular infiltration with little extracellular edema. Of interest, normal-appearing white matter has a mildly increased ADC (25). This correlates with histologic results in which multiple sclerosis was shown to diffusely affect white matter (26). Horsfield et al. (25) demonstrated that benign multiple sclerosis lesions have ADCs similar to those of secondary progressive multiple sclerosis. Furthermore, the degree of ADC elevation within individual lesions did not correlate with the degree of patient disability.

Increased apparent diffusion coefficient (ADC) values and decreased fractional anisotropy can be seen in normal-appearing white matter of patients with MS. This is clearly different from healthy control subjects, where these abnormalities are not seen [27, 28].

In acute disseminated encephalomyelitis, the ADC values appear normal within normal appearing white matter, unlike MS (4). Pamela et al. (3) demonstrated that DW MR imaging cannot help distinguish between multiple sclerosis and acute disseminated encephalomyelitis lesions because both usually have elevated diffusion. Because acute infarctions are characterized by restricted diffusion, however, DW MR imaging should be reliable for help in the differentiation between demyelinating lesions and stroke. In mitochondrial disease, basal ganglia, corpora striata affected more than globi pallidi, brain stem or thalami which appear as a small discrete foci less than 1 cm with symmetric areas of restricted

diffusion at acute phase with decreased ADC values (4).

Conclusion

The DW MR pulse sequence with ADC map is a valuable technique in differentiating neoplastic from non neoplastic lesions, high grade neoplasia and lymphoma from low grade neoplasia and non-neoplastic lesions. It is valuable in the evaluation of intracranial lesions with post-contrast ring enhancement and MS activity.

We recommend its use with relative cerebral blood volume, Cho/NAA ratio to improve accuracy, sensitivity and specificity of diagnosis and DD of intra-axial focal lesions.

Acknowledgments:

The authors thank Prof Dr/Kamal Al-sharkawy, MD, Mr/Abdel-fattah Mohammed Abdel-fattah, Mr/Mohammed Gharbawy, Mr/Akram & Abdullah Farwanah (Al-Ameen radiology department MRI specialists), and Dr/Adnan Ameen, MD, Dr/Saleam Gamal-Eldin, MD, (Medical managers of Al-Ameen Hospital) for their help in the preparation of this manuscript.

Footnotes

Abbreviations: ADC = apparent diffusion coefficient, CSF = cerebrospinal fluid, DW = diffusion weighted, rTPA: recombinant tissue plasminogen activator TTP=time to peak, rCBV=regional cerebral blood volume.

Corresponding author :

Ali Abdel-Fattah Alyed Esmael

Radiology & Neurology Departments, Faculty of medicine, Al-Azhar & Benha university
ali_helil@yahoo.com

References:

- 1) Le Bihan D, Breton E, Lallemand D, Grenier P, Cabanis E, Laval-Jeantet M (1986) MR imaging of intravoxel incoherent motions: application to diffusion and perfusion in neurologic disorders. *Radiology* Nov; 161(2):401-407
- 2) Zhong J, Petroff OAC, Prichard JW, Gore JC (1993) Changes in water diffusion and relaxation properties of rat cerebrum during status epilepticus. *Magn Reson Med* 30:241
- 3) Pamela W Schaefer, P. Ellen Grant, and R. Gilberto Gonzalez, Diffusion-Weighted MR imaging of the brain, *Radiology*, November 2000, 217, 331-345.
- 4) Osborn A., S.Blaser, K.Salzman, Diagnostic brain imaging, 1st edition, AMIRSYS 2004.
- 5) Lavblad Ko, Laubach HJ, Braid AE, Curtin F, Schlaug G, Edelman RR, warach S, clinical experience with DW MR in patients with acute stroke, *AJNR Am J. Neuroradiol.* 19 : 1061 1066 .1998

- 6) Schellinger PD, Jonsen O, Fiebach JB . et al.: Stroke magnetic imaging within 6 hours after onset . *Ann . Neural .*, 49:460-469 .2001
- 7) Albers G: Expanding the window of thrombolytic therapy in acute stroke: The potential role of acute MRI for patient selection . *Stroke*; 20:2230-2237 1999
- 8) Sunshine JL, Tarr RW, Lanzieri CF, Landis DM, Selman WR, Lewin JS, *Radiology*, 1999, 212 : 325 .
- 9) Van Gelderen P, De Vleeschouwer M, Despres D, et al.: Water diffusion in acute stroke. *Magn. Reson. Med.* 1994; 31:154
- 10) Joel R, Meyer, Arturo gutierrez, et al. :high b-value DW MRI of suspected brain infarctions. *Am J of Neuroradiology* 21:1821 (11- 2002)
- 11) Abbas Y.A ., Karima M.M and Nevine N : The utility of special MR stroke protocol in the evaluation and management of hyperacute stroke patients, the Egypt . *J of Radiology & Nucl . Med.*, vol . 33 No. 1, (March) : 129 – 140, 2002
- 12) Tsuruda J, Chew W, Moseley M, Norman D. Diffusion-weighted MR imaging of the brain: value of differentiating between extra-axial cysts and epidermoid tumors. *AJNR Am J Neuroradiol* 1990; 11:925-931.
- 13) Maeda M, Kawamura Y, Tamagawa Y, et al. Intravoxel incoherent motion (IVIM) MRI in intracranial, extra-axial tumors and cysts. *J Comput Assist Tomogr* 1992; 16:514-518.
- 14) T.Moritani, S.Kholm and P.L.Wastesson, DW MR imaging of the brain, 2nd edition, Springer-Verlag Berlin Heidelberg, 2005
- 15) Tien R, Felsberg G, Friedman H, Brown M, MacFall J. MR imaging of high-grade cerebral gliomas: value of diffusion-weighted echoplanar pulse sequences. *AJR Am J Roentgenol* 1994; 162:671- 677.
- 16) Brunberg J, Chenevert T, McKeever P, et al. In vivo MR determination of water diffusion coefficients and diffusion anisotropy: correlation with structural alteration in gliomas of the cerebral hemispheres. *AJNR Am J Neuroradiol* 1995; 16:361-371.
- 17) Ostergaard L, Hochberg F, Rabinov J, et al. Early changes measured by magnetic resonance imaging in cerebral blood flow, blood volume and blood brain barrier permeability following dexamethasone treatment in patients with brain tumors. *J Neurosurg* 1999; 90:300-305.
- 18) Aronen H, Cohen M, Belliveau J, Fordham J, Rosen B. Ultrafast imaging of brain tumors. *Top Magn Reson Imaging* 1993; 5:14-24.
- 19) Eis M, Els T, Hoehn-Berlage M. High resolution quantitative relaxation and diffusion MRI of three different experimental brain tumors in rats. *Magn Reson Med* 1995; 34:835-844.
- 20) Kim Y, Chang K, Kim H, Seong S, Kim Y, Han M. Brain abscess and necrotic or cystic brain tumor: discrimination with signal intensity on diffusion-weighted MR imaging. *AJR Am J Roentgenol* 1998; 171:1487-1490.
- 21) Schaefer P, Wang B, Gonzalez R. Echo planar diffusion weighted imaging in pyogenic infections (abstr) In: Proceedings of the 35th Annual Meeting of the American Society of Neuroradiology. Oak Brook, Ill: American Society of Neuroradiology, 1997; 103.
- 22) Ebisu T, Tanaka C, Umeda M, et al. Discrimination of brain abscess from necrotic or cystic tumors by diffusion-weighted echo planar imaging. *Magn Reson Imaging* 1996; 14:1113-1116.
- 23) Schaefer P, Tievsky A, Gonzalez R. Echo planar (EP) diffusion weighted imaging (dwi) in diffuse axonal injury (dai) (abstr) In: Proceedings of the 36th Annual Meeting of the American Society of Neuroradiology. Oak Brook, Ill: American Society of Neuroradiology, 1998; 216.
- 24) Atlas SW, Dubois P, Singer MB, Lu D. Diffusion measurements in intracranial hematomas: implications for MR imaging of acute stroke. *AJNR Am J Neuroradiol* 2000; 21:1190-1194.
- 25) Horsfield M, Lai M, Webb S, et al. Apparent diffusion coefficients in benign and secondary progressive multiple sclerosis by nuclear magnetic resonance. *Magn Reson Med* 1996; 36:393-400.
- 26) Allen IV, McKeown SR. A histological, histochemical and biochemical study of the macroscopically normal white matter in multiple sclerosis. *J Neurol Sci* 1979; 41:81-91.
- 27) Horsfield MA, Larsson HB, Jones DK, Gass A (1998) Diffusion magnetic resonance imaging in multiple sclerosis. *J Neurol Neurosurg Psychiatry* 64 Suppl 1:S80-S84
- 28) Guo AC, MacFall JR, Provenzale JM (2002) Multiple sclerosis: diffusion tensor MR imaging for evaluation of normal appearing white matter. *Radiology* 222:729-736
- 29) Gauvain KM, McKinstry RC, Mukherjee P, et al. (2001) Evaluating pediatric brain tumor cellularity with diffusion-tensor imaging. *AJR Am J Roentgenol* 177:449-454
- 30) Tsuruda JS, Chew WM, Moseley ME, Norman D (1990) Diffusion-weighted MR imaging of the brain: value of differentiating between extraaxial cysts and epidermoid tumors. *AJNR Am J Neuroradiol* 11:925-931
- 31) Annet L, Duprez T, Grandin C, Doods G, Collard A, Cosnard G (2002) Apparent diffusion coefficient measurements within intracranial epidermoid cysts in six patients. *Neuroradiology* 44:326-328.