

Intravitreal Ranibizumab versus Bevacizumab in Treatment of Choroidal Neovascular Membrane

Mohamed A.H Aboelenine

Ophthalmology Department, Faculty of Medicine– Al Azhar University

Abstract: Aim of the study: The aim of the study to compare the effect Intravitreal Ranibizumab(IVR) and Intravitreal Bevacizumab (IVB) in treatment of Choroidal Neovascular membrane(CNV) and follow-up for 1 year. **Patients and Methods:** This study was performed in 38 eyes of 38 patients suffering from CNV of different aetiologies in the period from April 2012 till July 2013. All patients were randomized and divided into two groups: **A- Bevacizumab group:** include 20 eyes of 20 patients. A dose of 1.25 mg/0.05 ml was injected in the inferotemporal quadrant using 30 gauge needle. Paracentesis was done followed by Bevacizumab (Avastin) injection. Retreatment done after one month and two months. **B- Ranibizumab group** Intravitreal Ranibizumab (Lucentis), injections were similarly performed in dose of 0.5 mg/0.05 ml. Retreatment done after one month. Monthly examination of all cases, and after the 4th month. OCT, fundus photography were checked every 4 months. **Results: Group(A) Bevacizumab (Avastin)** Twenty eyes of 20 patients with CNV with mean age 69.5 ± 3.2 years were treated with IVB. Avastin 1.25 mg in 0.05 mL (13 eyes had CNV due to age – related macular degeneration (AMD), 7 eyes had CNV due to myopia, all patients were followed up for 1 year. The mean BCVA pre injection was 5/60, (0.09 ± 0.03), the mean BCVA post injection was 0.31(6/24), 12 cases (60%) showed improvement of visual acuity, three cases of them show initial curing followed by recurrence. 6 cases (30%) showed no visual improvement, 2 cases showed deterioration of vision (10%). The mean central retinal thickness decreases significantly from $435 \pm 70.5 \mu\text{m}$ to $250.22 \pm 15 \mu\text{m}$ and correlated with improvement of BCVA. **Group (B) Ranibizumab group (Lucentis)** Eighteen eyes of 18 patients with CNV with mean age 65.5 ± 2.3 were treated with Intravitreal Lucentis, 11 eyes of CNV complicating AMD, 7 eyes had CNV complicating myopia, with follow up for 1 year. The mean BCVA pre- injection 6/60 (0.1 ± 0.03) the mean BCVA post- injections 6/24 (0.3 ± 0.2), 12 cases(66%) show improvement of visual acuity, 4 cases show recurrence after initial improvement and need more doses, 3 cases(16%) show no improvement, 3 cases(16%) shows deterioration of visual acuity, The mean central retinal thickness decreases from $355 \pm 122 \mu\text{m}$ to $190 \pm 105 \mu\text{m}$. **Conclusion:** The current study results showed that both intravitreal Ranibizumab and intravitreal Bevacizumab are effective in treating CNV with improving visual acuity and anatomic changes.

[Mohamed A.H Aboelenine. **Intravitreal Ranibizumab versus Bevacizumab in Treatment of Choroidal Neovascular Membrane.** *J Am Sci* 2013;9(11):294-299]. (ISSN: 1545-1003). <http://www.jofamericanscience.org>. 39

Keywords: anti- vascular endothelial growth factor (VEGF), intravitreal bevacizumab (IVB), intravitreal ranibizumab (IVR), choroidal neovascular membranes, optical coherent tomography.

1.Introduction

Choroidal neovascularization (CNV) is the term used to describe the growth of abnormal new vessels beneath the sensory retina or retinal pigment epithelium (RPE).⁽¹⁾

Choroidal neovascularization is abnormally found in many diseases in which the integrity of RPE or Bruch's membrane and choriocapillaries has been compromised.⁽²⁾

Anti- vascular endothelial growth factor (VEGF) have the ability to arrest the progression of CNV without transforming a neovascular membrane to scar tissue and preserving the native RPE and retinal architecture.⁽³⁾

Aim of the study

The aim of the study to compare the effect of Intravitreal Ranibizumab (IVR) and Intravitreal Bevacizumab (IVB) in treatment of Choroidal Neovascular membrane.

2.Patients and Methods:

This study was performed in 38 eyes of 38 patients suffering from CNV of different aetiologies in the period from April 2012 till July 2013.

All patients were submitted to full ophthalmic examination at baseline and follow up visits till 1 year including: BCVA, intra-ocular pressure (IOP) measurements using applanation tonometer, slit lamp biomicroscopy, fundus examination using indirect ophthalmoscope and slit lamp ophthalmoscopy using +90 volk lens.

The main outcome were measurement of the improvement in BCVA and tomographic signs of intra- or subretinal fluid as well as central retinal thickness.

Active CNV was confirmed by fluorescein angiography (FA) and optical coherence tomography (OCT). Lesions were defined as quiescent when being flat on OCT or devoid of leakage of FA.

Active lesions shows leakage of FA or when intra- retinal or subretinal fluid was noticed on OCT.

Inclusion criteria: Include patients who met the following criteria of active CNV confirmed by FA and OCT with absence of other ocular diseases that could affect BCVA.

Exclusion criteria: History of intra-ocular surgery within 6 months before the study, any other ocular disease that could compromise vision, ocular hypertension or glaucoma, uncontrolled systemic hypertension, peripheral vascular disease and history of thromboembolism, ischemic heart disease or stroke.

All patients were randomized and divided into two groups:

(A) Bevacizumab group: include 20 eyes of 20 patients 12 females (60%) and 8 males (40%).

Steps: The procedure was performed in the operating room under sterile conditions and using topical anaesthetic (Benoxonate hydrochloride 4%). Povidone iodine 5% were instilled before the procedure followed by ofloxacin 0.3% eye drops at the end of procedure then 4 times daily for the next week.

A dose of 1.25 mg/0.05 ml was injected at the pars plana 3.5 mm in pseudophakic eyes, 4 mm in phakic eyes in the inferotemporal quadrant using 30 gauge needle. Paracentesis was done followed by Bevacizumab (Avastin) injection to avoid reflux of the dose to subconjunctival space, retreatment done after one month and two months.

Intravitreal Ranibizumab (IVR) (Lucentis), injections were similarly performed in dose of 0.5 mg/0.05 ml, retreatment done after one month.

Post injection evaluation:

The patients examined as 1st day, 1st week, then monthly till 1 year, using examination with slit lamp biomicroscopy, fundus examination BCVA, IOP. Fundus photography, and OCT were checked every 4 months.

3. Results:

Group (A) Bevacizumab (Avastin)

Twenty eyes of 20 patients with CNV (12 males 60% and 8 females (40%) with mean age 69.5 ± 3.2 years were treated with IVB. Avastin group include 13 eyes **Fig(1a,2a)** had CNV due to age-related macular degeneration (AMD), 7 eyes had CNV due to myopia. All patients were followed up for 1 year. The mean BCVA pre-injection 5/60 (0.09 ± 0.03), the mean BCVA post-injection was (6/24), 12 cases (60%) showed improvement of visual acuity, three cases of them show initial improvement then start recurrence of CNV, 6 cases (30%) showed no visual improve, 2 cases (10%) showed deterioration of vision.

The mean central retinal thickness decreases significantly from $435 \pm 70.5 \mu\text{m}$ to $250.22 \pm 15 \mu\text{m}$ and correlated with improvement of BCVA. **Fig(1b,2b)**.

(B) Ranibizumab group

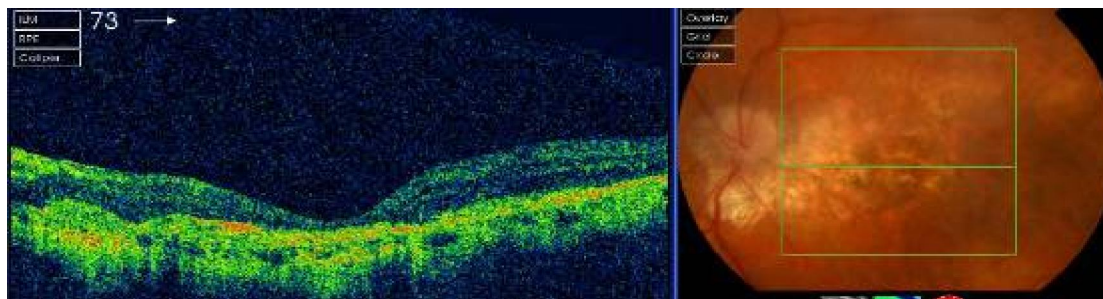


Fig (1a): OCT and fundus photography show CNV pre-injection with Avastin.

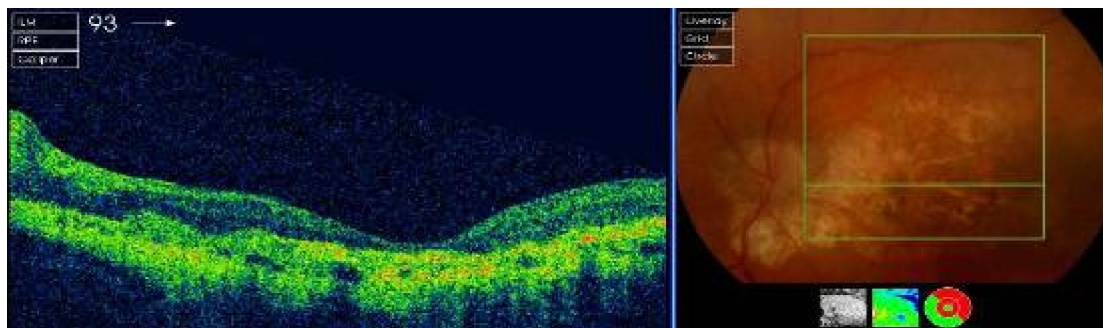


Fig (1b): OCT and fundus photography show CNV 8 months post-injection with Avastin.

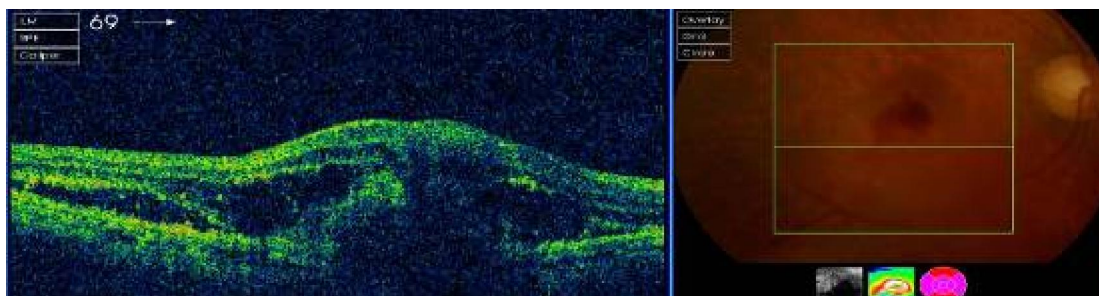


Fig (2a): OCT and fundus photography show CNV pre- injection with Avastin

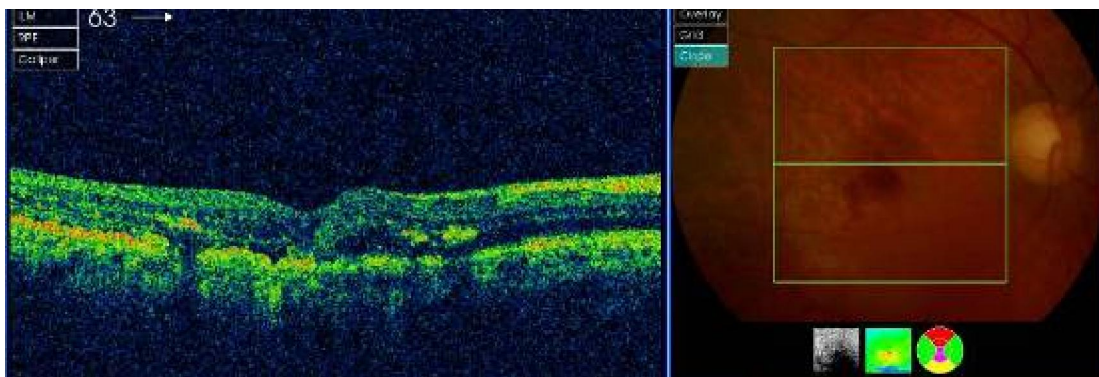


Fig (2b): OCT and fundus photography show CNV 4 months post- injection with Avastin.

Group (B) Ranibizumab group (Lucentis)

Eighteen eyes of 18 patients with CNV (10 males and 8 females) with mean age 65.5 ± 2.3 years were treated with Intravitreal Lucentis, 11 eyes of CNV complicating AMD, 7 eyes had CNV complicating myopia. **Fig. (3a,4a,5a)**

The mean BCVA pre- injection 6/60 (0.1 ± 0.03) the mean BCVA post- injections 6/18 (0.3 ± 0.2), 12 cases(66%) show improvement of

visual acuity, 3 cases (16%) show no improvement, 3 cases(16%) shows deterioration of visual acuity.

The mean central retinal thickness decreases from $355 \pm 122 \mu\text{m}$ to $190 \pm 105 \mu\text{m}$. **Fig(3b,4b,5b)**. Four cases show initial improvement followed by recurrence of CNV and need more number of doses. **Fig(4c,5c)**

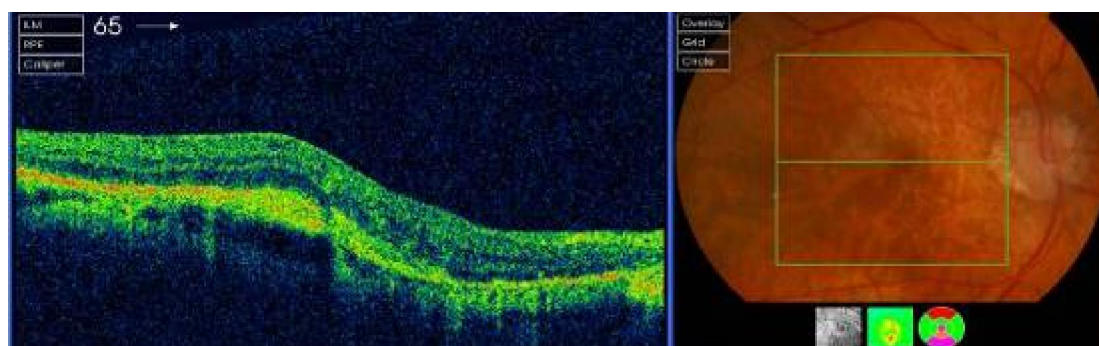


Fig. (3a): OCT and fundus photography show CNV pre- injection with Lucentis.

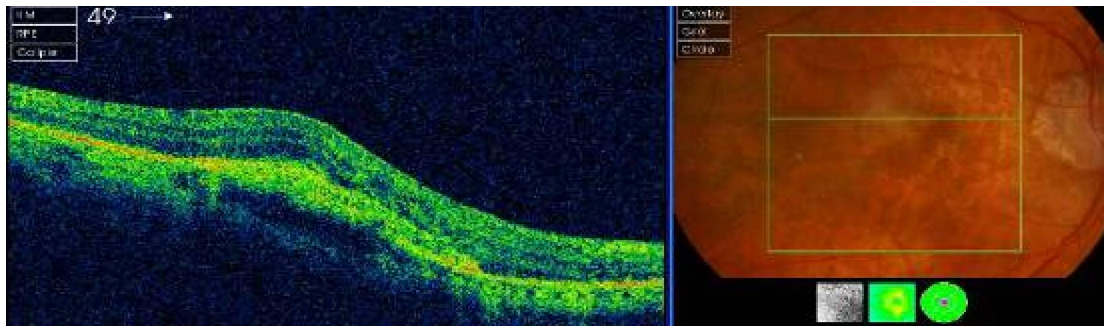


Fig. (3b): OCT and fundus photography show CNV 4 months post- injection with Lucentis.

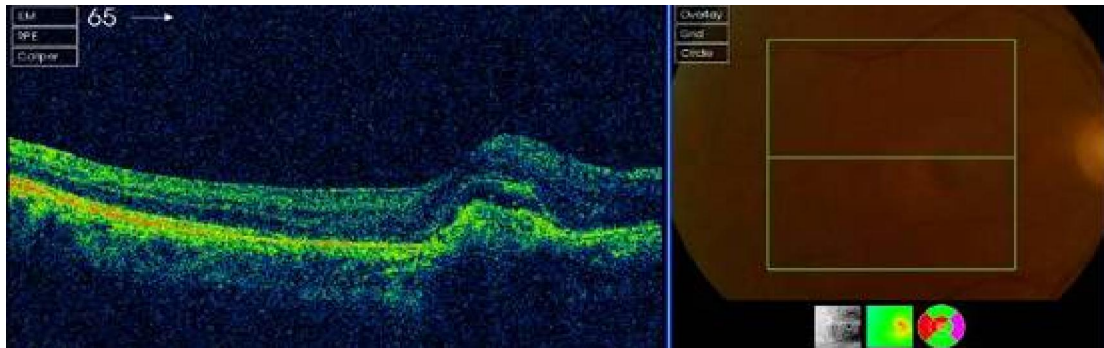


Fig. (4a): OCT and fundus photography show CNV pre- injection.

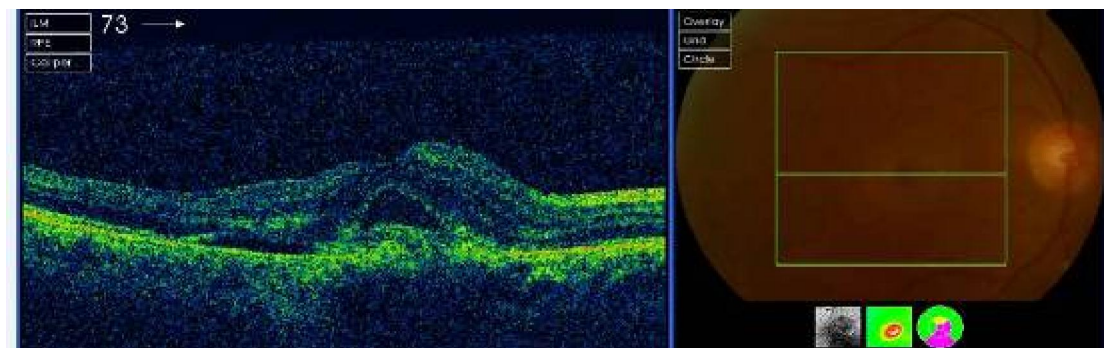


Fig. (4b): OCT and fundus photography show CNV after 8 months post injection.

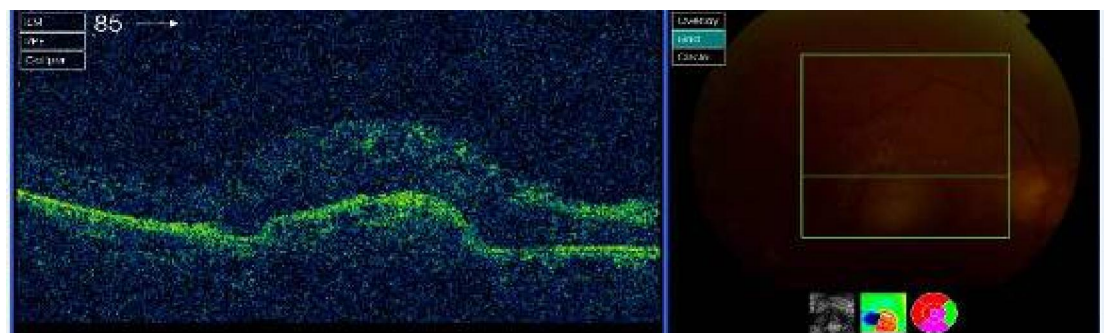


Fig (4c): Show recurrence CNV post injection 12 months with Lucentis

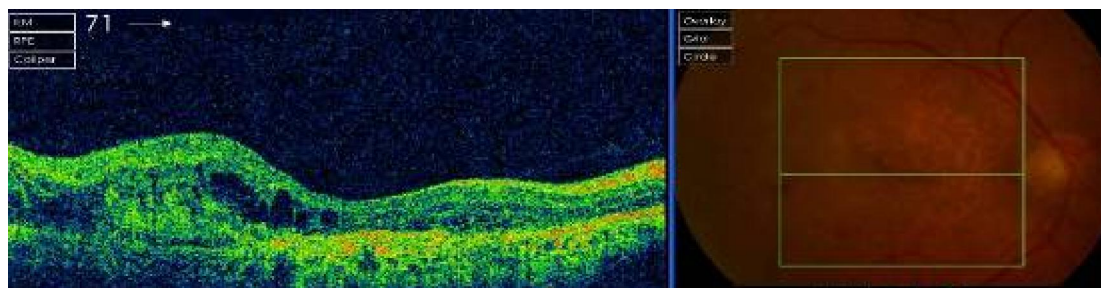


Fig. (5a): OCT and fundus photography show CNV pre- injection

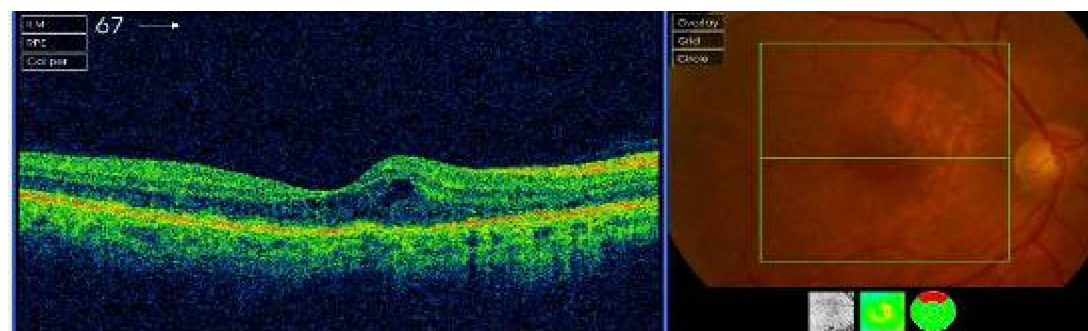


Fig. (5b): OCT and fundus photography show CNV 4 months post- injection with lucentis

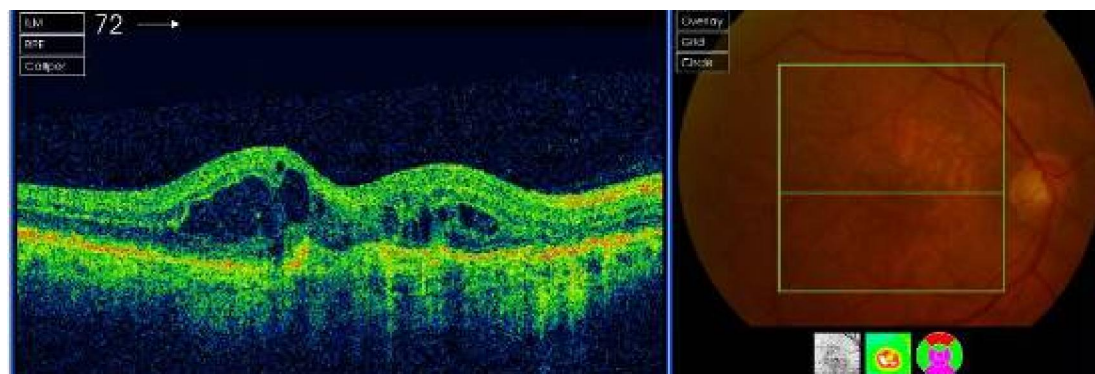


Fig. (5c): Show recurrent CNV complicating AMD 6 months post-injection with Lucentis.

4. Discussion:

Ranibizumab is an antibody fragment with higher binding affinity for VEGF than Bevacizumab which is a complete antibody with a higher molecular weight and inferior binding capacity to VEGF. Smaller size of Ranibizumab molecule may account for its faster and deeper penetration through retinal layers and RPE that lead to more sustained CNV stability and reducing number of injections.

A lower retreatment rate in eyes that undergo Ranibizumab treatment during 1 year follow up with lower number of injections required to stabilize myopic CNV and easier control than CNV associated with AMD.⁽⁴⁾

Anti-VEGF is the current standard treatment for age related macular degeneration.⁽⁵⁾

CNV is a major vision threatening complication of pathological myopia occurring up

10% of myopic individuals. It represent the most common cause of CNV in patients aged 50 year or younger.⁽⁶⁾

The treatment of intravitreal Ranibizumab has become the standard therapy for AMD worldwide.⁽⁷⁾

Intravitreal anti- VEGF therapy with Bevacizumab or Ranibizumab is an effective and safe treatment for Choroidal neovascularization complicating either AMD or myopia.⁽⁴⁾

According to the finding of OCT and FA deterioration of BCVA due to chronic macular lesions with fibrosis following injection of Avastin and Lucentis. Regarding to complication in that study no uveitis, endophthalmitis, no rise of IOP or retinal detachment

Avastin has advantage as low cost in comparison to Lucentis.

Although uncommon, visual loss may occur during anti VEGF treatment because of natural course of AMD in most cases.⁽⁸⁾

In our study both Bevacizumab and Ranibizumab group showed similar significant visual improvements, starting from one month and continue up to 1 year. As occurrence of 3 cases of recurrence with Avastin and 4 cases of recurrence with Lucentis patients in need for close post-injection follow-up for long period and inform patients to inform about any change or distortion of vision.

Gharbiya et al., 2010⁽⁹⁾ approved that both drugs were simply effective in reducing retinal thickness.

It has been established that treatment with antiangiogenic drugs, particularly anti-VEGF drugs able to block progression of CVN associated with age related macular degeneration and prevents the corresponding visual acuity loss⁽¹⁰⁾. Significant drawbacks of the present study including few number of patients, and shortness of the follow up period limited to 12 months.

Although both Lucentis and Avastin show similar visual outcomes, Ranibizumab seems to achieve a slightly greater efficacy than Bevacizumab in the term of mean number of injections and CNV stabilization.

Further studies are warranted to determine the best treatment in the management of CNV over a longer term follow up.

The current study showed that both Ranibizumab and Bevacizumab significantly improved visual acuity and anatomic changes in patients with CNV during 12 months follow up period.

Our results agree with results of Fine *et al.*, 2009⁽¹¹⁾ as concluded that Bevacizumab and Ranibizumab were effectively improving visual acuity over 6 months in patients with multifocal choroiditis associated with CNV.

Other study⁽¹²⁾, demonstrated improvements in many parameters of visual function in eyes with neovascular AMD undergo monthly intravitreal Ranibizumab.

Another study⁽⁴⁾ showed significant visual improvements with Ranibizumab from 1 month and continuing up to 18 months when comparing Ranibizumab and Bevacizumab in treating CNV associated with myopia.

Other researches^(13,14) reported the results of intravitreal Ranibizumab 20 eyes after initial BCVA improvement at 6 months, 12 months and 24 months. Conclusion.

The current study results showed that both intravitreal Ranibizumab and intravitreal Bevacizumab are effective in treating CNV with improving visual acuity and improve anatomic changes in patients with CNV.

References

1. **Compochiaro PA and Glaser BM:** A retinal derived stimulators of retinal pigment epithelial cells and astrocytosis proliferation, *Exp Eye Res.* 1986; 43: 449-457.
2. **Gass JDM:** Stereoscopic atlas of macular disease diagnosis and treatment, 3rd St Louis CV Mosby 1987.
3. **Bhatnagar P, Freud KB, Spaide RF, et al.** Intravitreal Bevacizumab for management of Choroidal neovascularization in pseudo-xanthoma elasticum. *Retina*, 2007; 27: 897-902.
4. **Iacono P, Parodi MB, Papayannis A, et al.** Intravitreal Ranibizumab versus Bevacizumab for treatment of myopic choroidal neovascularization. *Retina*, 2012; 32: 1539-1546.
5. **Ip MS, Scott IU, Brown GC, Brown MM, Ho AC, et al.** Anti-vascular endothelial growth factor pharmacotherapy for age-related macular degeneration: a report by the American Academy of Ophthalmology. *Ophthalmology*, 2008; 115: 1837-1846.
6. **Ohno-Matsui K, Yoshida T, Futagami S, Yasuzumi K, Shimada N, Kojima A, et al.** Patchy atrophy and lacquer cracks predispose to the development of choroidal neovascularisation in pathological myopia. *Br J Ophthalmol.* 2003; 87: 570-573.
7. **Mitchell P, Korobelnik JF, Lanzetta P, et al.** Ranibizumab (Lucentis) in Neovascular age related macular degeneration evidence from clinical trials. *BR. J. Ophthalmol.* 2010; 94: 2-13.
8. **Cohen SY, Oubrahim H, Uzzan J, Dubois L, Tudayoni R.** Causes of unsuccessful ranizumab treatment in exudative age related macular degeneration in clinical settings, *Retina*, 2012; 32: 1480-1485.
9. **Gharbiya M, Giustolisi R, Allievi F et al.** Choroidal neovascularization in pathologic myopia, intravitreal Ranibizumab versus Bevacizumab - a randomized controlled trial. *Am J Ophthalmol* 2010; 149: 458-464.
10. **Brown DM, Kaiser PK, Micheles M, et al.** Ranibizumab versus Verteporfin for neovascular age-related macular degeneration. *N Engl J Med* 2006; 355: 1432-44.
11. **Fine HF, Zhitomirsky IB, Freund KB et al.:** Bevacizumab (Avastin) and Ranibizumab (Lucentis) for choroidal neovascularization in multifocal choroiditis. *Retina* 2009 29 (1) 8-12.
12. **Sabour SP, Longman J, Nolan JM, Pesudovs K et al.,** Visual performance in patients with neovascular age related macular degeneration undergoing treatment with intravitreal Ranibizumab. *Ophthalmology*, volume 2013 (2013). Article ID 268438
13. **Lalloum F, Souied EH, Bastugi-Garin S et al.:** Intravitreal Ranibizumab for choroidal neovascularization complicating pathologic myopia. *Retina* 2010; 30: 399-406.
14. **Baba T, Kubota-Tanini M, Kitahashi M et al.** Two years comparison of photodynamic therapy and intravitreal Bevacizumab for treatment of myopic choroidal neovascularization. *Br. J. Ophthalmol.* 2010; 94: 864-870.