

Nasty surprise of traumatic Diaphragmatic Rupture

Rifaat kamar¹, Emad Sarawy¹, Mohamed Ahmed Osman¹ and Reham M Khalil²

¹Cardiac Surgery department, National Heart Institute (NHI)

²Radiodiagnosis department, Ain Shams University
sarawy91@yahoo.com

Abstract: Diaphragmatic rupture is a serious complication of thoracoabdominal trauma. The resulting hernia may be initially small and easily missed, to enlarge later as more viscera are sucked into the thorax. Severity of trauma may not always be compatible with the patients' clinical situation. Due to its rarity and difficulty in diagnosing, delayed detection of diaphragmatic injuries can occur. Delayed presentation is the single most important contributor to increased morbidity and mortality in patients with blunt diaphragmatic rupture. We prospectively studied 25 patients from January 2006 to October 2013. This study was performed in multiple centers. In 21 patients (84%) diaphragmatic injury was discovered during the acute phase of trauma, 4 patients presented late (16%). Surgical treatment consists of hernia reduction, pleural drainage and repair of diaphragmatic defect. The standard surgical approach was laparotomy or, less commonly, thoracotomy. The generally accepted protocol in the acute setting is laparotomy because the concomitant intra-abdominal injuries are more likely present than thoracic injuries. There is an increasing trend towards approaching long-standing hernias with a transthoracic or thoracoabdominal approach. We found that the most common cause of traumatic diaphragmatic hernia was road traffic accident (20 patients, 80%), then fall from a height (3 patients, 12%). Stab wound (1 patient, 4%) and gun shots (1 patient, 4%) We found that initial imaging work-up is crucial, good exposure of the defect is the corner stone of the repair, and Dacron mesh has a role in repairing large defects.

[Rifaat kamar, Emad Sarawy, Mohamed Ahmed Osman and Reham M Khali. **Nasty surprise of traumatic Diaphragmatic Rupture.** *J Am Sci* 2014;10(2s):97-103]. (ISSN: 1545-1003). <http://www.jofamericanscience.org>. 13

Keywords: Trauma, Hernia, Diaphragm, delayed.

1. Introduction:

Diaphragmatic injuries are rarely seen and accurate diagnosis is difficult because of the paucity of clinical symptoms and thus those injuries may be easily overlooked (1, 2)

Diaphragmatic injuries remain a diagnostic challenge for both radiologists and surgeons. The detection of traumatic diaphragmatic rupture in the acute setting is problematic because specific clinical signs are usually not evident (3). Furthermore, the high frequency of associated injuries (52–100%) may distract from diaphragmatic injury (4,5).

The clinical picture does not reflect the severity of trauma. For the accurate and duly diagnosis of those patients, the physicians must suspect the severity from the diaphragmatic rupture (DR), as any delay in the diagnosis may lead to significant morbidity and mortality (6).

In conservatively managed patients, the rate of initially missed diaphragmatic injuries ranges from 12 to 66%, and they may even be overlooked at laparotomy (7, 8). Diagnosis of a diaphragmatic injury requires a high index of suspicion, as delayed diagnosis increases the chance of visceral herniation and strangulation, which has mortality as high as 60% (9). Thus, the ability to detect diaphragmatic injuries with noninvasive techniques is increasingly important (10).

The first traumatic diaphragmatic hernia was described by Sennertus in 1541(7). The first two deaths were described by Ambrose Paré in 1578, one from strangulated bowel (11).

Diaphragmatic hernias require a high index of suspicion to detect. Patients can be asymptomatic in up to 53% of hernias from blunt trauma and 44% from penetrating trauma. Routine chest x-ray detects only 33% of hernias when interpreted by the trauma team leader at initial evaluation. Missed injuries are associated with significant morbidity and mortality (12).

The incidence of diaphragmatic ruptures secondary to trauma is 0.8–5%. Due to the difficulty in diagnosing traumatic diaphragmatic injuries, up to 30% present as late findings (13). Delayed presentation is the single most important contributor to increased morbidity and mortality. Mortality rates as high as 16–33% are seen, owing to the fact that many blunt diaphragmatic ruptures remain clinically silent until they present with life-threatening complications (14).

Although post mortem studies report an equal incidence of right and left sided ruptures, antemortem reports suggest that 88–95% of diaphragmatic ruptures occur on the left and ruptures of the right side are associated with more severe injuries and therefore an increased morbidity and mortality (15). This disparity

of increased incidence in left-sided rupture can be explained by multiple factors: under diagnosis of right-sided injuries, relative strength of the right hemidiaphragm compared to the left due to embryonic fusion points and hepatic protection of right-sided injuries (16).

2. Patients and methods:

In order to revise and evaluate the outcome of surgical repair of acquired traumatic diaphragmatic hernia, we prospectively studied 25 patients from January 2006 to October 2013. This study was performed in multiple centers: King Fahd Hospital, Jazan, KSA; As Salam international hospital, Cairo, Egypt.

Twenty one patients presented with acute hernia while four patients presented with late hernias.

Clinical findings included for suspecting diaphragmatic hernia were:

- (1) Marked respiratory distress.
- (2) Decreased breath sounds on the affected side.
- (4) Palpation of abdominal contents upon insertion of a chest tube.
- (3) Auscultation of bowel sounds in the chest.
- (5) Paradoxical movement of the abdomen with breathing and/or diffuse abdominal pain.
- (6) High index of suspicion from the history is very important

Imaging Studies:

• Chest X-ray:

AP (antero-posterior) supine CXR was performed in most patients, and if the general condition (GC) is good PA (postero-anterior erect CXR was done. Also lateral view is performed in some cases.

Radiographic findings that indicate traumatic rupture include the following (17):

- Abdominal contents as hollow viscus in the thorax, with or without signs of focal constriction ("collar or hour glass sign").
- Nasogastric tube seen in the thorax above the level of Lt hemidiaphragm.
- Elevated hemidiaphragm (>4 cm higher on left vs right).
- Distortion of diaphragmatic margin.
- If with large intrathoracic hernia, positive mass effect may cause contralateral mediastinal shift. This may be mistaken as hydropneumothorax

• Helical CT (Computed Tomogram):

CT (with contrast) was performed using multi-detector MDCT in patients with fair GC, yet patients with seriously bad GC necessitated immediate intervention & thus limited CT examination. Multiplanar reconstruction (MPR) was done in sagittal & coronal planes.

CT findings indicating rupture include the following (17):

- Direct visualization of injury.

- Failure of visualization of a diaphragmatic segment.
- Intrathoracic herniation of viscera.
- Collar sign.
- Peridiaphragmatic active contrast extravasation.
- Dependent viscera sign when herniated organs directly rest on posterior ribs in supine position due to absence of posterior support by diaphragm.
- Thickened diaphragm.
- Presence of both hemothorax and hemoperitoneum.

Surgical repair:

As with any trauma, initial stabilization and resuscitation was imperative before embarking on any operation, however most of cases (18 patients, 72%) had concomitant injuries that necessitated emergency exploration.

We adopted the routine management of such cases as mentioned in literature with emphasis on 3 main points. The first point is achievement of a good exposure of the defect regarding the size and angles. This was achieved and facilitated by the use of many Allis forceps. Good visualization helped us in reduction of abdominal contents back into abdomen. The Second point is the use of interrupted polypropylene 3/0 sutures followed by a second layer of continuous suture. The Third point is to use a Dacron mesh in cases of difficult or large defects.

Open surgical repair has been the traditional method of treating blunt traumatic diaphragmatic injuries. Surgical approach is most often abdominal in acute cases, but may require a thoracic approach, especially with right-sided injury. Mesh or prosthetic repair is rarely needed in the acute stage, but may be useful for a delayed repair. Laparoscopy may be a useful technique when standard diagnostic methods fail to reveal a DR and it is also useful for management.

3. Results:

In this study we included 25 patients, they were 21 males (84%) and 4 females (16%). Their ages ranged between 4 to 65 years with a mean of 24.26 ± 11.74 years. 21 patients presented with acute injury while 4 patients presented late with respiratory distress. The most common cause of traumatic diaphragmatic hernia was car accident (20 patients, 80%), then fall from a height (3 patients, 12%), stab wound (1 patient, 4%), gun shoot (1 patient, 4%).

Table (1): Selected demographic characteristics of the study patients

Gender:	
Males	21 (84%)
Females	4 (16%)
Age (years) (mean \pm SD)	24.26 ± 11.74
Mode of presentation:	
Acute	21 (84%)
Late	4 (16%)

Table (2): Selected demographic characteristics of the study patients

Cause of injury	
Road traffic accident	20 (80%)
Stab wound	1 (4%)
Gun shot	1 (4%)
Fall from a height	3 (12%)
Side of hernia	
Right	4 (16%)
Left	21 (84%)

Table (3): associated injuries

Splenic injury	7 (28%)
Liver tear	6 (24%)
Rib fracture	7 (28%)
Myocardial contusions	2 (8%)
Other fractures	8 (32%)
Head injury	4 (16%)

Table (4): Surgical approach

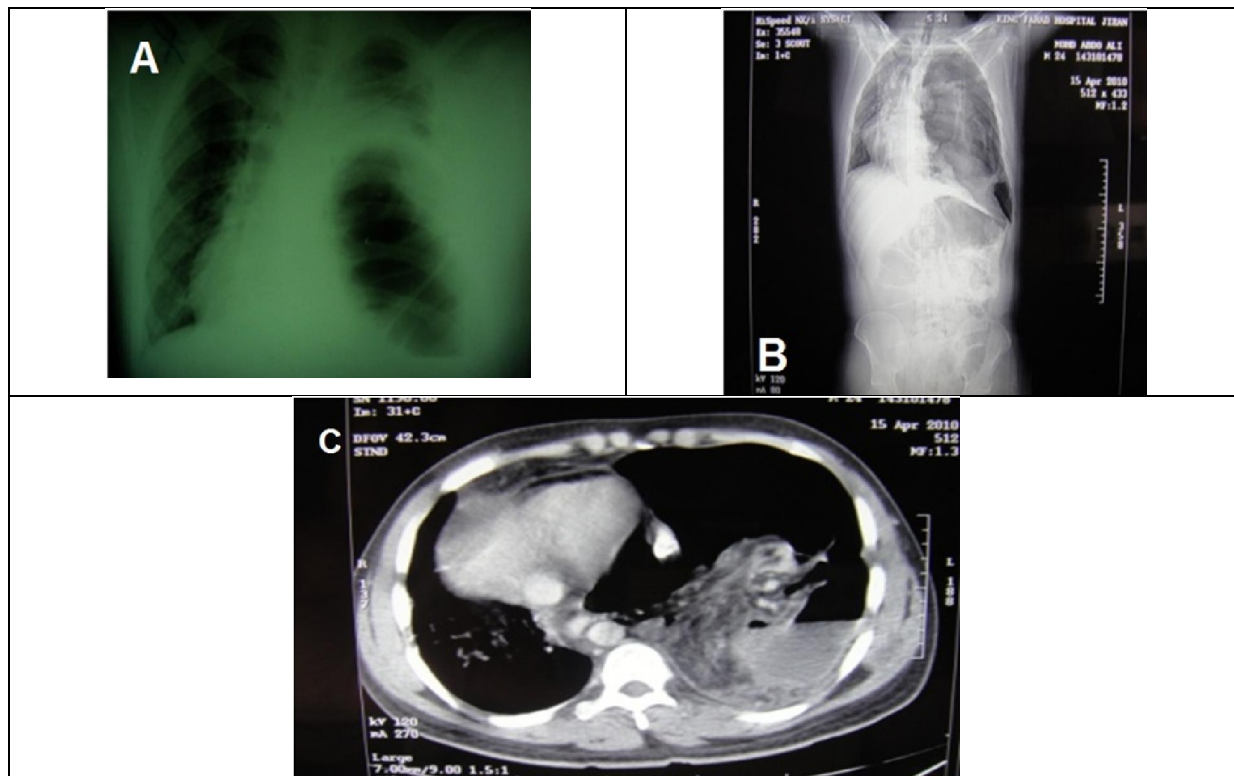
Thoracotomy alone	3 (12%)
Laparotomy alone	18 (72%)
Combined	3 (12%)
Nothing (patient refused surgery)	1 (4%)

Selected interesting cases will be highlighted:**The First Case**

A 29-year-old gentleman was admitted to another hospital complaining of GIT troubles that lasted for two weeks before admission. After receiving medical treatment for a week, the patient was discharged

without improvement. The patient was then referred to our hospital in miserable a condition. He presented with severe dyspnea, hypotension and oxygen saturation 70%. After resuscitation, chest X-ray revealed massive shadow in the left hemithorax with depressed left copula and shifted mediastinum to the right side. Chest CT scan confirmed shift of mediastinum to the right side with presence of omentum in the left hemithorax. The case was diagnosed as left side diaphragmatic hernia mimicking tension pneumothorax. Initial resuscitation was followed by preparation for surgery. Via a left thoracotomy, omentum and large intestine were protruding from a small tear (4 cm) in the diaphragm. A part from large intestine was found gangrenous. Reposition of the abdominal contents back into abdomen was performed followed by repair of the defect and closure of chest with 2 intercostal drains. Via a laparotomy, general surgeon managed to perform resection and colostomy.

Postoperatively, a thorough history taking and re-examination of the patient revealed a history of stab wound in left posterior axillary line at the 5th space, before 5 months that required no further management. Patient's postoperative course was uneventful and he continued his follow-up as an out-patient for 6 months.

**Figure (1): Imaging results of the first case:**

- (A) CXR shows positive mass effect exerted by the herniated contents with shift of mediastinal structures to contralateral side.
- (B) Scout image in CT as (A).
- (C) Axial CT image shows the herniated omentum and part of the stomach lying adjacent to the posterior ribs instead of within the expected confines of the dome of the diaphragm i.e. dependent viscera sign.

The Second Case

An 11-year-old boy presented to the hospital after a road traffic accident with fracture of the left humerus. Initial chest X-ray was free, so the patient was treated & discharged from hospital.

Two months later, the boy was presented to the hospital in severe distress with dyspnea, tachycardia, congested neck veins, and oxygen saturation 74%. Provisionally, a diagnosis as tension pneumothorax was adopted on clinical basis. This was confirmed by chest X-ray that revealed in addition shifted trachea and mediastinum to the right side due to herniated stomach through the diaphragm.

Resuscitation, intubation and ventilation took place promptly. Moreover, a nasogastric tube was inserted under imaging that improved the case.

Patient was taken to theater as an emergency case. Via a left thoracotomy, stomach was repositioned back into the abdomen, and remaining defect was large that required a mesh to repair.

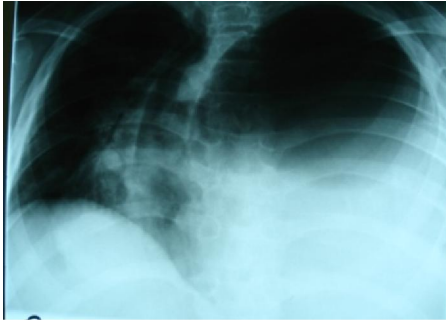


Figure (2): Imaging results of the second case CXR shows stomach herniation into Lt hemithorax, shift of mediastinum to right side, and non identification of the Lt costal diaphragm.

The Third Case

A 25-year-old male patient presented to the emergency department after a road traffic accident

(RTA) with loss of consciousness. His conditions necessitated intubation and mechanical ventilation.

Base-line chest X-ray was normal. Subsequent investigations suggested an internal hemorrhage that necessitated Laparotomy exploration along with splenectomy.

Eighteen days later, routine chest X-ray revealed massive right pleural opacity. Aspiration of this effusion was bloody, so initial diagnosis was right hemothorax. Two successive intercostal tubes clotted shortly after insertion on the right side; hence the case was diagnosed as right clotted hemothorax. We decided to go for a right thoracotomy that revealed a big diaphragmatic tear through which the liver is herniating into right hemithorax, and the intercostal tube was passing into the liver. The liver was repaired & repositioned back into abdomen and good repair of the diaphragmatic tear without need for mesh.

Post operatively, liver enzymes peaked after one week then normalized after one month. Patient was doing well over one year follow-up.

The Fourth Case

A 4-year-old boy was referred from another hospital with two intercostal tubes in the right hemithorax as a case of post road traffic accident. Upon arrival to emergency department, the patient was stable, thus we proceeded with his work-up. Chest x-ray and CT chest & abdomen with contrast were done that revealed GIT contents in the right hemithorax. Patient was prepared for surgery. Right side Thoracotomy exploration revealed large intestine in the right hemithorax with a big tear in right costal diaphragm. After reposition of the GIT back into the abdomen, repair of the diaphragm with the use of a mesh was done. Subsequent laparotomy revealed a small tear in liver. His post-operative course was uneventful.

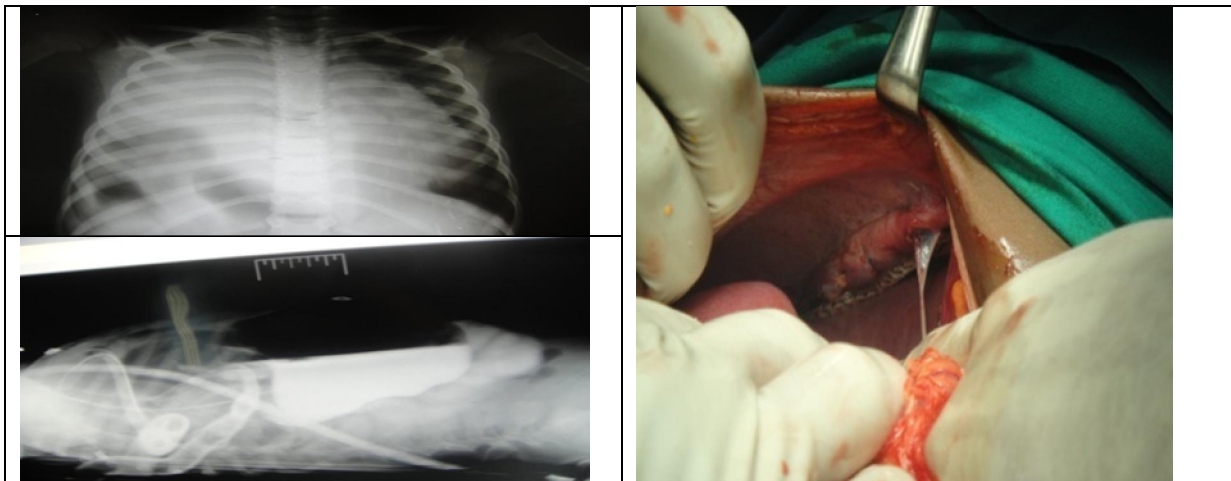


Figure (3): Imaging results and an intraoperative view of the fourth case.

The Fifth Case

A 20-year-old young man was presented to emergency department after a road traffic accident. Immediate resuscitation and intubation took place due to unconsciousness and hypotension. Initial imaging work-up revealed bilateral multiple fractured ribs (5, 6, 7, 8, 9, 10 on right side, and 8, 9, 10, 11 on left side), bilateral thoracic opacities, Abdominal Sonar reveal intra-abdominal hemorrhage, and injury of spleen as well as liver.

After insertion of an intercostal tube on each side, laparotomy was done with Splenectomy and repair of a liver tear. Exploration revealed bilateral tears in diaphragm with herniation on left side. Both tears were repaired with direct sutures.

Immediate postoperative course was stormy although maximal inotropic support. This might be attributed to accompanying myocardial contusions and pelvic fracture. Unfortunately, patient passed-off after 8 hours.

The Sixth Case

A 65-year-old woman referred with a complaint of intermittent GIT troubles. Initial Chest X-ray revealed large intestine in right hemithorax. Thorough history taking showed a traffic road accident before 10 years. The patient refused to undergo any surgical procedure although she was informed about the consequences of her case.

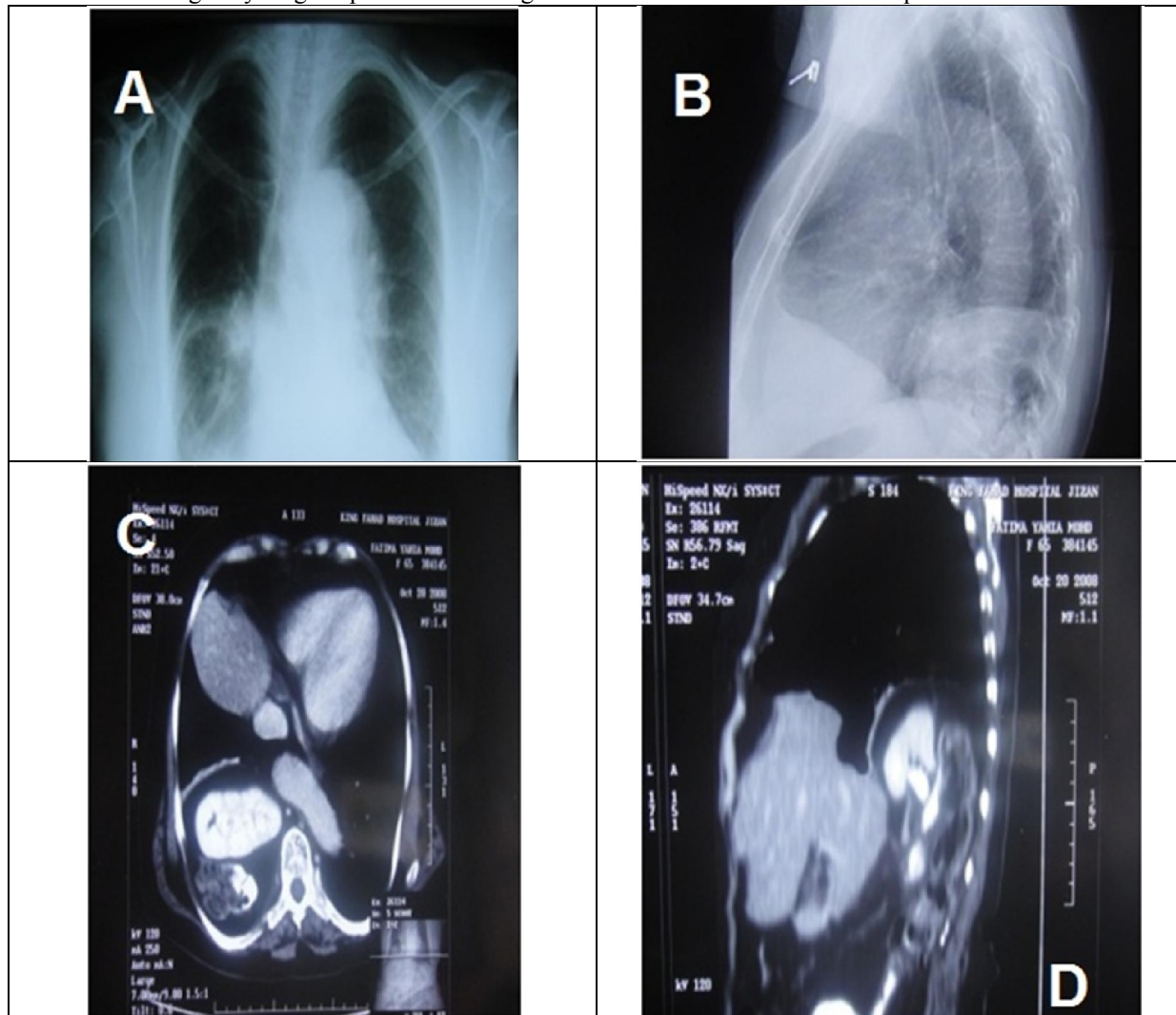


Figure (4): Imaging of the sixth case:

- (A) CXR shows herniated hollow structure into Rt hemithorax.
- (B) Lateral CXR confirms the presence of intestinal loop at posterior costophrenic angle.
- (C) Axial CT image with contrast shows the loop filled with contrast & fecal matter with positive dependent viscera sign.
- (D) Sagittal reformatted CT image easily elicits collar sign (focal constriction) at dome of the liver indicating partial herniation of the liver too.

The Seventh Case

A 25-year-old young man was presented to emergency department with a gunshot. The bullet inlet was determined on the back with no exit. Chest x-ray and CT scan revealed single shrapnel in the mid lower lobe of the left lung, with left side mild to moderate hemothorax.

After stabilization of the patient and preparation for surgery, left thoracotomy for extraction of the shrapnel was done. We found the shrapnel by the help of C arm X-ray. A small tear in the left copula of the diaphragm was noticed with minimal bulge of the stomach. Stomach was repositioned digitally and the defect was closed directly.

The Eighth Case

A 12-year-old boy fall off a camel was presented to emergency department. Initial imaging work-up revealed a mild opacity on left hemithorax due to fractured ribs. Left intercostal drain was inserted that initially drained bloody 500 ml and continued to shed off 120 ml/hour for more than 5 hours. Left thoracotomy revealed free lung but a small tear (2cm) in left copula of diaphragm with blood coming through it. The defect was repaired by direct sutures. Simultaneous laparotomy for splenectomy and lavage was performed.

The Ninth case

A 24-year-old male presented to the emergency department in shock and loss of consciousness after a road traffic accident. Initial assessment revealed low arterial oxygen saturation ($S_aO_2 = 93\%$) and low hemoglobin (6 mg %). We decided to electively intubate and resuscitate before completing his work-up. Chest X-ray revealed no rib fracture; however there was a massive right-sided hemothorax. Abdominal ultrasonography revealed minimal fluid. A right-sided tube thoracostomy initially drained 1500 cc and continued to drain. Subsequent right thoracotomy revealed a large tear in the diaphragm, through which the liver was plugged and lacerated which was the source of bleeding. General surgeon managed to repair the liver tear through the defect, and then diaphragmatic tear was repaired. Unfortunately, the patient arrested and passed off while performing laparotomy.

The Tenth Case

A 33-years-old man presented with disturbed conscious level to emergency department after falling from a mountain on sharp edge stone resulted in thoraco-abdominal wound from which contents were protruding outside. The patient was initially resuscitated in emergency department then transferred without delay to operative theatre, which revealed a skin wound extending from umbilicus to left side of the chest, fractured left 10th and 11th ribs, and protrusion of the left lung through the wound, exploration revealed

tear of the diaphragm, small tear in pericardium, lacerated liver, and ruptured spleen. The patient underwent splenectomy which was done by the general surgeon, then Via a left thoracotomy, the diaphragm was repaired by a patch to cover the large defect. Left intercostal tube was inserted before closing chest and abdomen. Unfortunately, his postoperative course was stormy and pt passed off few hours after surgery.

4. Discussion:

The incidence of diaphragmatic rupture varies from 0.8 to 8% following major blunt trauma (18). Sennertus was the first to describe a traumatic diaphragmatic hernia in 1541(7). Bowditch made an antemortem diagnosis of a traumatic diaphragmatic rupture in 1853 (19). Shanmuganathan *et al.*, has stated that more than 90% of blunt traumatic diaphragmatic ruptures occur following motor vehicle accident (20).

Because motor vehicle accidents are increasing day after day, the number of reported cases tends to increase. Injuries to the left hemidiaphragm occur three times more frequently than to the right side following blunt trauma. On the left side, the left posterolateral aspect is the commonest site. This is structurally weak area as it originates from the pleuroperitoneal membrane (21). The right hemidiaphragm is congenitally stronger and is partially protected by the liver, preventing the transmission of force through the abdominal viscera to the right hemidiaphragm. Bilateral hemidiaphragm injuries are uncommon and are seen in up to 4.5% of patients (21).

High incidence of associated injuries such as pelvic fractures, thoracic aortic injury, hepatic, and splenic injuries has been reported in up to 100% of patients with diaphragmatic injury (20). Brasness *et al.* (22) have found that associated abdominal injuries are common with liver (38%), spleen (34%), and renal injuries in (30%) and splenic injuries were seen in 7%. Similar findings were seen in our series.

The clinical diagnosis of rupture diaphragm is difficult & can be missed in up to 65% of patients. Therefore, imaging is essential.

- Chest radiography is usually abnormal but not specific. Also positive pressure ventilation may prevent the injury from being discovered on an X-ray as it keeps the abdominal organs from herniating into the chest cavity. Additionally, often another injury such as pulmonary contusion masks the injury on the X-ray film.
- Bedside emergency Ultrasonography can be safe & accurate. But it can be compromised by pulmonary aeration, gastric & colonic gas, subcutaneous emphysema, bandages, abdominal pain & obesity.
- MRI is less readily adapted to acute trauma setting & should be reserved for patients with uncertain CT diagnosis or delayed suspected diaphragmatic tear.

- Helical CT allows: quick acquisition of volumetric data with subsequent reduction in motion & beam hardening artifacts, better spatial resolution, better demonstration of subtle signs of diaphragmatic rupture, and evaluation of other associated injuries.

Minimally invasive techniques for diaphragmatic repair are becoming more common than before. With advances in technology and surgical skills, repairing both acute and chronic diaphragmatic hernias is possible with laparoscopic, thoracoscopic, or combined approaches.

Conclusions:

- A) Acute diaphragmatic hernias need repair as early as possible. The patient should not leave hospital except after repair which is mandatory).
- B) In late discovery of hernia, thoracotomy is preferred.
- C) A high index of suspicion concerning a diaphragmatic tear should be always present, in post blunt trauma, in which x ray show hemothorax without any fracture of ribs or vertebral column and after insertion of ICD, to evacuate (drain) hemothorax with continuous bleeding,
- D) Multidetector Ct chest scan is the gold standard for diagnosis.

Recommendations:

- A) In all trauma patients, chest x-ray is imperative upon admission, followed by another one after 2 weeks, one month, 3 months, and 6 months, in order to avoid late presentation of diaphragmatic hernia and its complications.
- B) In order to achieve a good exposure of the defect regarding the size and angles, using many Allis forceps is recommended. Good visualization helps in reduction of abdominal contents back into abdomen.
- C) In large defects, use of a Dacron mesh is recommended.

References:

1. Sivit CJ, Taylor GA, Eichelberger MR. Chest injuries in children with blunt abdominal trauma: evaluation with CT. *Radiology*. 1989; 171:815–8.
2. Shah R, Sabanathan S, Mearns AJ, Choudhury AK. Traumatic rupture of diaphragm. *Ann Thorac Surg*. 1995; 60:1444–9.
3. Gelman R, Mirvis SE, Gens D. Diaphragmatic rupture due to blunt trauma: sensitivity of plain chest radiographs. *Am J Roentgenol*. 1991; 156:51–57.
4. Mirvis SE, Shanmuganathan K. MR imaging of thoracic trauma. *Magn Reson Imaging Clin N Am*. 2000; 8:91–104.
5. Shanmuganathan K, Killeen K, Mirvis SE, White CS. Imaging of diaphragmatic injuries. *J Thorac Imaging*. 2000;15:104–111.
6. Adnan Narci, Tolga Altuğ Şen, and Reşit Köken Asymptomatic diaphragmatic rupture with retroperitoneal opening as a result of blunt trauma. *J Emerg Trauma Shock*. 2010; jul- sep;3(3): 301.
7. Reber PU, Schmied B, Seiler CA, Baer HU, Patel AG, Büchler MW. Missed diaphragmatic injuries and their long-term sequelae. *J Trauma*. 1998; 44:183–188.
8. Murray JG, Caoili E, Gruden JF, Evan SJ, Halvorsen RA, Jr, Mackersie RC. Acute rupture of the diaphragm due to blunt trauma: diagnostic sensitivity and specificity of CT. *Am J Roentgenol*. 1996;166:1035–1039.
9. Carter BN, Guiseffi J, Felson B. Traumatic diaphragmatic hernia. *Am J Roentgenol*. 1951;65:56–72.
10. Iochum S, Ludig T, Walter F, Sebbag H, Grosdidier G, Blum AG. Imaging of Diaphragmatic injury: a diagnostic challenge. *Radiographics*. 2002;22:S103–S106.
11. Blaivas M, Brannam L, Hawkins M, Lyon M, Sriram K. Bedside emergency ultrasonographic diagnosis of diaphragmatic rupture in blunt abdominal trauma. *Am J Emerg Med*. Nov 2004;22(7):601–4.
12. Hanna WC, Ferri LE, Fata P, Razek T, Mulder DS. The current status of traumatic diaphragmatic injury: lessons learned from 105 patients over 13 years. *Ann Thorac Surg*. Mar 2008; 85(3):1044–1048.
13. Crandall M., Popowich D., Shapiro M., West M. Posttraumatic hernias: historical overview and review of literature. *American Surgeon*. 2007; 73:845–850.
14. Anderson D.W. Bilateral diaphragm rupture: a unique presentation. *Journal of Trauma*. 2002; 52:560–561.
15. Rashid F., Chakrabarty M.M., Singh R., Iftikhar S.Y. A review on delayed presentation of diaphragmatic rupture. *World Journal of Emergency Surgery*. 2009;4 (Article 32).
16. Shah R., Sabanathan S., Mearns A.J., Choudhury A.K. Traumatic rupture of the diaphragm. *Annals of Thoracic Surgery*. 1995; 60:1444–1449.
17. Magu S, Yadav A, Agarwal S. Computed tomography in blunt chest trauma. *Indian J Chest Dis Allied Sci*. 2009; 51:75–81.
18. Larici AR, Gotway MB, Litt HI, Reddy GP, Webb WR, Gotway CA, Dawn SK, Marder SR, Storto ML. Helical CT with sagittal and coronal reconstruction: Accuracy for detection of diaphragmatic injury. *Am J Roentgenol*. 2002; 179:451–457.
19. Mansoor KA. Trauma to the diaphragm. *Chest Surg Clin N Am*. 1997; 7:373–383.
20. Shanmuganathan K, Mirvis SE. Imaging diagnosis of nonaortic thoracic injury. *Radiol Clin N Am*. 1999; 37:533–551.
21. Nachimi A, Szapiro D, Ghaye B. Helical CT of blunt diaphragmatic rupture. *Am J Roentgenol*. 2005; 184:24–30.
22. Brasness KA, Bensard DD, Patric DA. Blunt diaphragmatic rupture in children. *J Trauma*. 2004; 56:80–82.

2/21/2014