

## Testicular toxic effect of Di-N-Butyl phthalate on adult male albino rat and the possible protective role of Vitamin C & E (ultrastructural, histological and histochemical study)

Hala Elharoun<sup>1</sup> and Manar A. Bashandy<sup>2</sup>

Histology<sup>1</sup> and Anatomy<sup>2</sup> Departments, Faculty of Medicine, Menoufiya University

[A\\_z491@yahoo.com](mailto:A_z491@yahoo.com)

**Abstract: Introduction:** Phthalic acid esters (PAEs) are industrial chemicals used as plasticizers. They are present in a wide variety of products as building materials and food products. Several experimental studies have widely demonstrated the testicular toxicity caused by di-n-butyl phthalate (DBP). **Aim of the work:** The aim of the present study is to clarify the possible protective effect of vitamin C & E with di-n-butyl phthalate induced testicular germ cell toxic model using simple histological, histochemical and ultrastructure methods. **Materials and Methods:** Forty adult male albino rats were subjected to experiment for ten days. The animals were divided randomly into four equal groups: control; vitamin C & E treated; treated with Di-N-Butyl phthalate (DBP) and protective (DBP and vitamin C & E treated). Control group, rats in this group were given orally the same amount of vehicle (distilled water and corn oil) and vitamin C & E treated group, received vitamin C & E at a dose of (250 mg/kg b.wt /day) orally daily. Di-N-Butyl phthalate treated group, was administered (DBP) orally with daily dose of (500 ml /kg b.wt/day). Protective group, received vitamin C & E at a dose of (250 mg /kg b.wt /day) orally daily 1 hour before oral administration of Di-N-Butyl phthalate. All the animals were sacrificed at day eleven. Both testis of each animal were processed for histological, histo-chemical and ultrastructural studies. **Results:** In Di-N-Butyl phthalate treated group, histologically and histochemically, rat testis showed marked vacuolations of the lining germinal epithelium of the seminiferous tubules, which show marked distortion with very wide lumen, no sperms, a reduction in the thickness of their epithelial lining and reduction of seminiferous tubules diameter. Degeneration of germinal epithelium was observed as well as interstitial tissue. There was strong PAS reaction in relatively thickened basal lamina of seminiferous tubules and overall reduction of PAS reaction in seminiferous tubules germinal epithelium. The ultrastructural changes showed irregular thickened basement membrane, degeneration and shrinkage of spermatocytes. Disorganization of the germinal epithelium, with loss of the spermatogenic cells especially spermatocytes and spermatids with variable sized intracellular vacuoles were observed also. The previous histopathological changes reported in Di-N-Butyl phthalate treated group confirmed by morphometric measurements as: decrease in tubular diameter, reduction in germinal epithelial height and decrease in testicular weight when compared to control group. Additionally, histological, histochemical and ultrastructural examination of the protective group treated with vitamin C & E displayed improvement in seminiferous tubules structure, but still some tubules appeared degenerated. **Conclusion:** toxic effect of Di-N-Butyl phthalate should be kept in mind during chronic usage. Vitamin C & E advised to be administered in concomitant with DBP as it could ameliorate its adverse effect on rat testis.

[Hala Elharoun and Manar A. Bashandy. **Testicular toxic effect of Di-N-Butyl phthalate on adult male albino rat and the possible protective role of Vitamin C & E (ultrastructural, histological and histochemical study).** *J Am Sci* 2014;10(11):147-157]. (ISSN: 1545-1003). <http://www.jofamericanscience.org>. 20

**Key Words:** Di-N-Butyl phthalate – vitamin C – vitamin E- rat testis.

### 1. Introduction

Phthalic acid esters (PAEs) are industrial chemicals used as plasticizers. They are present in a wide variety of products, including building materials, food products such as butter and infant formula, as well as in a variety of cosmetics and medical devices (Hubinger and Havery, 2006). As di-n-butyl phthalate (DBP) is not bound to the final product, it can be released during use or disposal of the product (Hauser et al., 2004). They can migrate from the plastic to the external environment (Bosnir et al., 2003). Humans can be affected through ingestion of contaminated food and water, indoor air or dermal contact (Kavlock et al., 2002). PAEs are usually absorbed from the

gastrointestinal tract after oral administration, and they are catalytically converted to toxicologically active monoesters by esterases (Bao et al., 2011).

Previous studies have reported anti-androgenic effect in rodents exposed to di-n-butyl phthalate (DBP), butylbenzyl phthalate and diethylhexyl phthalate during gestational, lactation and pubertal age (Nair et al., 2008). Additionally, Phthalate esters have been implicated in the decline of human sperm counts (Shanna et al., 1997) and testicular atrophy in rat models (Farombi et al., 2007). Severe damage to the reproductive system of mature male rats after 250 mg/kg DBP administration (Zhang et al., 2004), Leydig cell aggregation on fetal exposure

to DBP (Mahood et al., 2005) was observed. Sertoli cells in DBP exposed fetal testes had retracted apical processes, altered organization of vimentin cytoskeleton and abnormal cell-cell contacts with gonocytes (Kleymenova et al., 2005).

Several mechanisms have been proposed to explain the induction of testicular atrophy by depletion of zinc (Alam et al., 2010), increased oxidative damage of proteins, lipids and DNA (Fukuoka et al., 1990), alteration of vimentin cytoskeleton organization or membrane alteration in Sertoli cells leading to sloughing of spermatogenic cells (Kleymenova et al., 2005).

Phthalic acid esters exerted their anti-androgenic effects by disrupting testosterone (T) biosynthesis (Gray et al., 2006). The inhibition of T synthesis was due to the down-regulated expression of genes involved in cholesterol transport and the testosterone synthesis pathway in male rats (Borch et al., 2006; Thompson et al., 2005). In other studies, the exact mechanisms involved in the formation of phthalate-induced testicular atrophy were not known (Farombi et al., 2007).

Based on this concept, a variety of anti-oxidant or anti-apoptotic agents have been employed to counteract phthalate ester-induced testicular damage in rats (Farombi et al., 2007). Antioxidants, both water soluble and lipid soluble represented an important aspect of the antioxidant defense system that, when present at low concentrations significantly delays or prevents oxidation of oxidant substances (e.g. proteins, lipids, carbohydrates and nucleic acid) (Lodhi et al., 2011).

Vitamin E is a fat soluble vitamin. It is a well known antioxidant, plays an important role in scavenging free oxygen radicals (Gurel et al., 2005). It exists mainly in the cell membranes thus helping to maintain membrane stability (Ozden et al., 2009). A number of studies have shown that, Vitamin E pretreatment significantly protects testis against oxidative damage (Murugesan et al., 2005).

Vitamin C is thought to be important water soluble antioxidant which reported to neutralize reactive oxygen species and reduce the oxidative stress (El-Gendy et al., 2010).

Recently, it was shown that, administration of antioxidant vitamins together with di-ethyl-hexylphthalate prevented phthalate ester-induced testicular atrophy in rats suggesting that the formation of reactive oxygen species may be involved in the formation of testicular atrophy in phthalate-exposed rats (Ishihara et al., 2000).

The aim of the present study is therefore to clarify the possible protective effect of vitamin C & E with di-n-butyl phthalate induced testicular germ cell

toxic model using simple histological, histochemical and ultrastructure methods.

## 2. Material and Methods

### *Martials:*

#### **Animals:**

Forty adult male Albino rats of an average weight (150-200 grams) were selected for this study. The animals obtained from breeding animal house, Faculty of Medicine, Menofya University (Menofya, Egypt). During the study, they were feed standard animal food and tap water ad libitum. They also, kept under good hygienic conditions and maintained at normal room temperature.

#### **Drugs and chemicals:**

##### ***Di-N-Butyl phthalate :***

Di-N-Butyl phthalate (98%) was obtained from the El-Gomhoureya Pharmaceutical Company (Cairo, Egypt).

##### ***Vitamins:***

##### **Vitamin C:**

1 gm effervescent tablets were obtained from Cid Pharmaceutical Company (Cairo Egypt). The calculated dose was dissolved in 25 ml distilled water.

##### **Vitamin E:**

400 mg oily capsules were obtained from Pharco Pharmaceutical Company (Cairo Egypt). Then, the estimated dose was dissolved in 8 ml corn oil.

#### **Experimental protocol:**

Animal experimentations were carried out in an ethical manner following guidelines set by Ethical Committee of Menofya University. The animals were divided into 4 groups, each of 10 rats:

**Group I:** Rats in this group were given the same amount of vehicle (distilled water and corn oil) orally by intragastric gavage along the time of the experiment (ten days).

**Group II:** The control group received vitamins C and E (250 mg/kg b.wt./ day) orally for nine days (hsu et al., 1998; Bashandy et al., 2012)

**Group III:** Rats in this group were administered (500 ml/kg b.wt.) of Di-N-Butyl phthalate orally (Nair et al., 2008) dissolved in corn oil at a dose of volume of 0.5 ml/kg (Higuchi et al., 2003; Farombi et al., 2007). This dose was reported to be toxic for rats.

**Group IV:** Rats in this group were received Vitamin C and E (250 mg/kg b.wt./day) orally 1 hr before the administration of same dose of Di-N-Butyl phthalate as group III daily for 10 days. Di-N-Butyl phthalate and antioxidants were administered orally to each animal using curved needle- like tube to be introduced directly into the stomach (a gavage process).

On day eleven, 24 hrs after last dose of drug administration, the rats were weighted then sacrificed. From each rat, both testes were removed and cleaned of accessory tissues and weighted with an electronic

balance in gm. Specimen of right testis were excised then immersed in normal saline. The tissues were divided and subjected to the following studies:

### **I -Histopathological evaluation:**

The right testis of each animal was dissected out then fixed in 10% formal saline. The specimens were processed to obtain paraffin blocks from which 5  $\mu$ m thick sections were cut and stained with haematoxylin & eosin for the general architecture of the testis (Stevens and Wilson, 1996).

### **II- Histochemical studies:**

Paraffin sections were stained with Periodic acid chief (PAS) counter stained with haematoxylin and masson trichrome (M.T) stain. PAS stain is specific for estimation of glycogen. Masson trichrome stain is specific for collagen fibers (Stevens and Wilson, 1996).

### **III-Tissue preparation for ultrastructure study:**

The testis of each rat of all groups were sliced to form small pieces (1 mm<sup>3</sup>) which were fixed in a mixture of 2.5% gluteraldehyde and paraformaldehyde (pH: 7.3) and fixed overnight at 4° C. Specimens were post-fixed in 1% osmium tetroxide. The specimens were dehydrated in ascending grades of alcohol and then passed in two changes of propylene oxide to be lastly embedded in epon. Ultra thin sections (60 nm thick) were cut mounted on copper grids and stained with uranyl acetate and lead citrate. The grids were then examined with the transmission electron microscope (Seo-Russia) in Alexandria medical research institute. Identification of testis sections was achieved by staining semi-thin sections (1um thickness) with 1% aqueous toluidine blue and examining them with light microscope (Oberley et al., 2008).

### **Morphometric study :**

Using H&E stained sections, morphometric measurements in the form of seminiferous tubules diameter and germinal (seminiferous) epithelial height were done. From each rat, 10 microscopic fields were used. At least 50 seminiferous tubules diameter were measured from each rat. Precautions were taken to use rounded or nearly rounded tubules. The tubular diameter was measured and expressed in  $\mu$ m at x100 magnification with a semi automatic system which is formed of a trinocular microscope (Olympus Corporation, Japan), Digimizer program version 2 and personal computer (Toshiba, Japan). Measurements were calibrated in term of micrometer using Nikon micrometer slide before performing any measurements (Aiad et al., 2008).

The germinal (seminiferous) epithelial height was obtained with the same tubules used to determine tubular diameter. Germinal epithelium was measured from the basement membrane to the latest stage of germinal cell (spermatids) (Batra et al., 2001).

### **Statistical analysis:**

The data (rat body weight, testis weight, seminiferous tubules diameter and germinal epithelial height) were expressed as mean $\pm$  SD. The student t-test was used to test the significant change in each parameter in the experimental animals of groups II, III and IV rats in comparison with the control animals of group I. The statistical analysis of data was carried out using Excel and statistical package for the Social Science Software, version 11 (SPSS, Inc., Chicago, USA.) on An IBM compatible computer (Peat and Barton, 2005). Results were considered significant when the P-value was less than 0.05.

## **3. Results**

### **Histological results:**

#### **Group I: Control group:**

##### **Light microscopy:**

Examination of sections of the testis of control adult male albino rats showed the typical features of normal testicular parenchyma with densely packed seminiferous tubules with intertubular connective tissue interstitium (Fig.1). Each tubule is lined with stratified germinal epithelium formed of spermatogonia and primary spermatocytes. Sertoli cells with their large pale nuclei are observed between the cells. The sperms are observed in the lumen of seminiferous tubules. The interstitium contains clusters of interstitial cells (Fig. 2). Periodic Acid Chief's (PAS) reaction of the testis showed a strong reaction in a well circumscribed basal lamina which appeared as a thin layer, magenta red in color. Other cells of the spermatogenic epithelium exhibited moderate PAS reaction (Fig.3). Masson trichrome stained sections showed moderate greenish collagen fibers in the wall of seminiferous Tubules as shown in (Fig. 4).

##### **Electron microscopy:**

In the control group, seminiferous tubule of rat testis containing spermatogonia and sertoli cells resting on the basal lamina and each having nucleus. Primary spermatocyte is having large oval euchromatic nucleus, golgi bodies composed of multiple parallel cisternae with attached ribosomes, free ribosomes and rounded or oval mitochondria with cisternae. Sertoli cells appeared with its large triangular nucleus and having granular cytoplasm with mitochondria and dense bodies. The cytoplasm of sertoli cells extend between primary spermatocytes with tight junction (blood testes barrier) appeared between adjacent sertoli cells (Fig.5 &6).

Spermatid is having rounded nucleus with finely granular chromatin with several dark clumps. Well formed acrosomal vesicle (cap) covering the anterior half of the nucleus. It's cytoplasm contains multiple mitochondria. From the posterior margin of

the acrosomal cap arise many microtubules forming the manchette (Fig. 7).

**Group II: Vitamin C&E group:**

**Light microscopy:**

Showed the same light microscopic appearance like control group

**Electron microscopy:**

Showed the same electron microscopic appearance like control group

**Group III: Di-N-Butyl phthalate treated group:**

**Light microscopy:**

The testis of di-n-butyl phthalate treated rats showed most of seminiferous tubules are markedly distorted with very wide lumen no sperms and a reduction in the thickness of their epithelial lining. Most of seminiferous tubules epithelium is formed of a few spermatogenic cells with sloughed cells in its lumen with acidophilic hyaline materials in the interstitium. Vacuolation in the germinal epithelium as well as in the interstitium are observed (Fig.8). PAS reaction of this group showed overall reduction in the reaction in the seminiferous tubules, with loss of the magenta discoloration due to arrest of germinal epithelium and loss of sperms and thickened basal lamina of the seminiferous tubules, which exhibited strong PAS reaction (Fig.9). Moderate degeneration and necrosis of the spermatogenic cells as well as vacuolation within cells were also noticed. Masson trichrome stained sections showed marked increase in the greenish Connective tissue in the walls of the seminiferous tubules. There was also a thickening in the wall of blood vessels (Fig.10).

**Electron microscopy:**

In this group, the main finding is thickened irregular basement membrane of seminiferous tubule and shrinkage of primary spermatocyte when compared to control group (Fig. 11). Seminiferous tubules showed markedly distorted germinal epithelium. There were overall different degrees of atrophy in the seminiferous tubules. Disorganization of the germinal epithelium, with loss of the spermatogenic cells specially spermatocytes and spermatids. Spermatogenic cells showed degeneration (Fig.12). Spermatogonia with cytoplasm contained multiple intercellular variable sized vacuoles, degenerated mitochondria and dilated was observed. Degenerated primary spermatocytes were noticed with different size intercellular vacuoles (Fig. 13).

**Group IV: Di-N-Butyl phthalate, Vitamin C & E treated group:**

**Light microscopy:**

Examination of the histological sections of rat testis of this group revealed that the testes start to

regain its normal general architecture. Many tubules are packed together with regular outline but others are still distorted with few sperms. Many tubules have stratification in their epithelium and sperms are observed in their lumen. Acidophilic hyaline materials are still observed between some tubules (Fig.14). PAS reaction of this group showed strong reaction on basal lamina of the seminiferous tubules when compared to control group. (Fig.15). Masson trichrome stained sections showed marked increase in the greenish connective tissue in the Wall of seminiferous tubules with hyalinization in the interstitium (Fig.16)

**Electron microscopy:**

In this group, the main finding is the basal part of seminiferous tubule having irregular basal lamina, sertoli cells with oval pale nucleus near basal lamina with prominent nucleolus. The cytoplasm of sertoli cells contain small vacuoles, mitochondria, dense bodies and still some dilated SER (Fig.17). Oval spermatid could be seen containing oval nucleus covered by acrosomal vesicle and mitochondria. From the posterior margin of the acrosomal cap arise many microtubules forming the manchette (Fig.18).

**Morphometric results:**

Exposure of albino rats to di-n-butyl phthalate lead to a significant decrease in the body weight of animals as well as a significant decrease in the testicular weight of animals when compared to the control group ( $P<0.05$ ). Vitamin C & E treated group showed mean body weight and testicular weight nearly similar to control group. Similarly, Administration of Vitamin C & E in concomitant to di-n-butyl phthalate improve body and testicular weight to near normal (Table 1).

Morphometric analysis of group III which administered di-n-butyl phthalate confirmed the testicular atrophy with marked highly significant decrease in tubular diameter when compared to the control group ( $P<0.005$ ). Administration of Vitamin C & E in association di-n-butyl phthalate (group IV) improve tubular diameter, but still there is significant difference in tubular diameter between this group when compared to control group ( $P<0.05$ ) as shown in (Table 1).

Testicular atrophy was also expressed by highly significant decrease mean seminiferous epithelial height in group III when compared to control group ( $P<0.005$ ).Supplementation of Vitamin C & E with di-n-butyl phthalate improve this parameter, but still there is significant difference in this parameter between this group when compared to control group ( $P<0.05$ ) as shown in (Table 1).

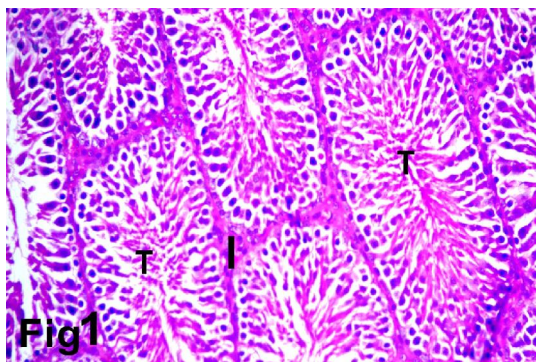


**Table (1): Effect of administration of Di-N-Butyl phthalate and in concomitant with vitamin c&e on the parameters of rat testis**

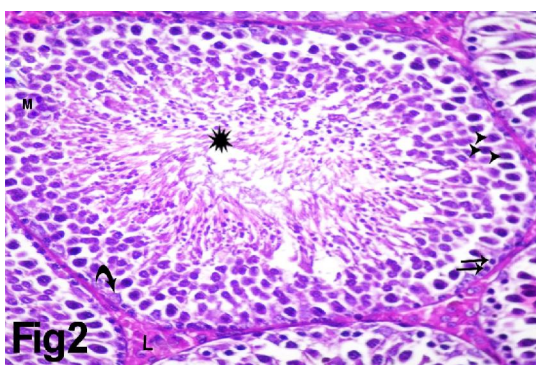
Group	Mean Body weight (gm)±SD	Mean testicular weight (gm)±SD	Mean Seminiferous tubular diameter (µm) ±SD	Mean Seminiferous epithelial height (µm) ±SD
Control group (I)	153±2.1	1.41±0.1	355.66±3.21	247.8±2.66
Vit.c&e treated group (II)	141±1.5	1.27±0.2	345.41±2.4	250.2 ±3.79
Di-N-Butyl phthalate treated group (III)	109±2.4*	1.04±0.1*	220.51±4.31**	108.4±3.22**
Di-N-Butyl phthalate and Vit.C&E treated group (IV)	133±1.3	1.17±0.18	295.62±3.28*	189.1±1.86*

Comparison was done between Group I (control group) and groups II, III & VI.

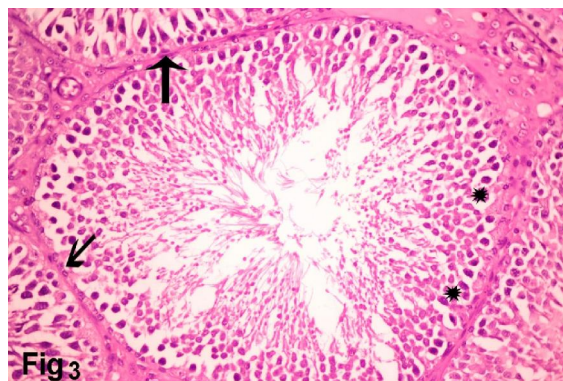\*p < 0.05, \*\*p < 0.01, \*\*\*p < 0.001, NS: Non significant.



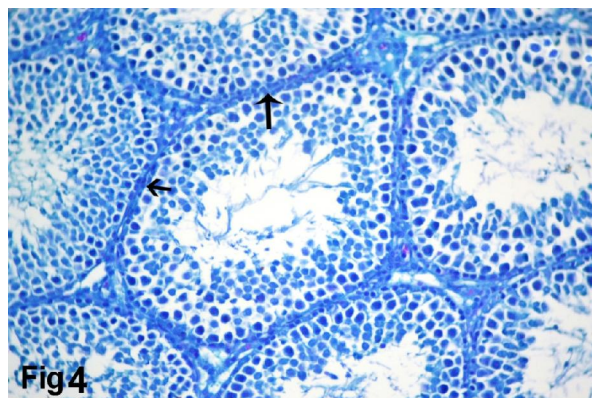
**Fig.1.** A photomicrograph of a control adult rat testis showing parts of densely packed eight seminiferous tubules with their testicular parenchyma (T) and little interstitium (I). (Hx&E, X100)



**Fig.2.** A photomicrograph of a control adult rat testis showing seminiferous tubules. Each tubule is lined with stratified germinal epithelium formed of spermatogonia (→), primary spermatocytes (▶) with mitotic figures (M) and sertoli cells (curved arrow) with their large pale nuclei are observed between the cells. The interstitium contains clusters of interstitial cells (Leydig cells) (L). The sperms are observed in the lumen of seminiferous tubules (\*) (Hx&E, X400)

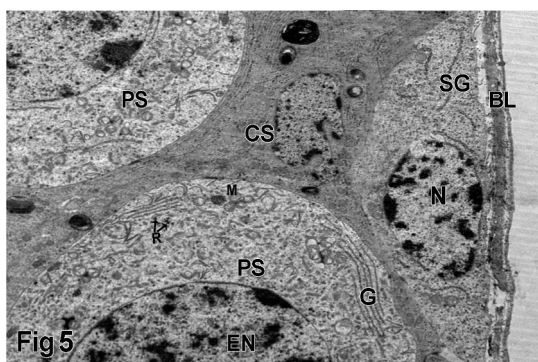


**Fig.3.** A photomicrograph of a control adult rat testis showing strong PAS positive reaction in a well circumscribed basal lamina which appeared as a thin layer, magenta red in colour (→) and moderate reaction is observed in other spermatogenic epithelium (\*). (PAS, X400)

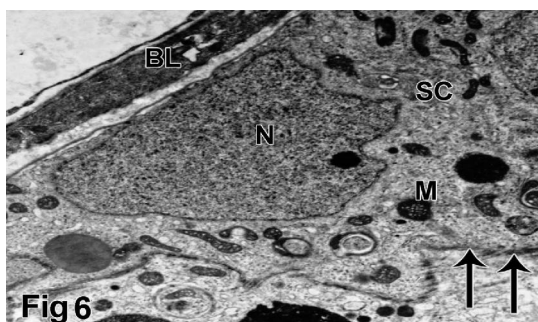


**Fig.4.** A photomicrograph of a control adult rat testis showing moderate greenish collagen fibers in the wall of seminiferous Tubules (→) (Masson's Trichrome, X400)

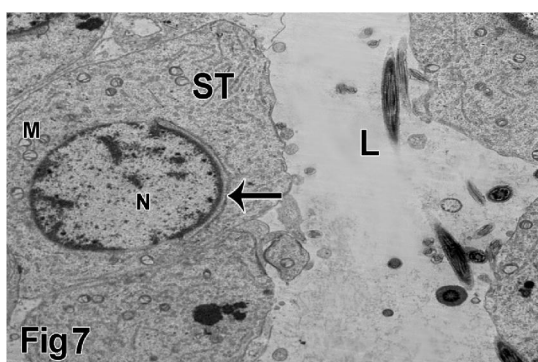




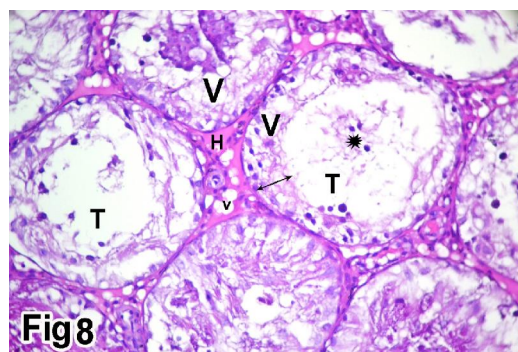
**Fig.5.** An electron photomicrograph of transverse section of a control adult rat testis showing basal part of seminiferous tubule with spermatogonia (SG) resting on basal lamina (BL) and having nucleus (N). Primary spermatocyte (PS) is observed having large euchromatic nucleus (EN), golgi bodies (G), free ribosomes (R) and mitochondria (M). Note: The cytoplasm of Sertoli (CS) cells extended between primary spermatocytes. (X 1500)



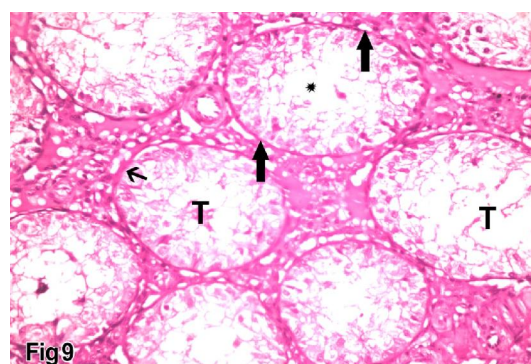
**Fig.6.** An electron photomicrograph of transverse section of a control adult rat testis showing basal part of seminiferous tubule containing Sertoli cell (SC) resting on basal lamina (BL) with its large triangular nucleus (N) and having cytoplasm with mitochondria. Note: Tight junction (blood testis barrier) (→) between adjacent Sertoli cells. (X 2500)



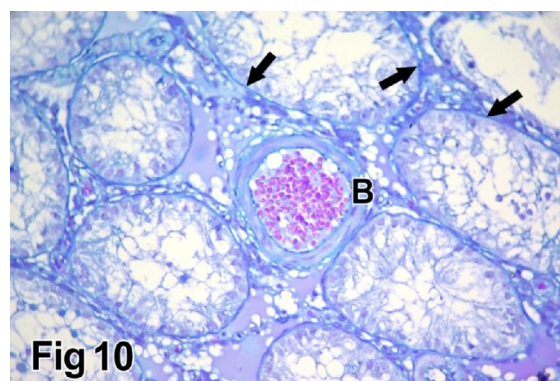
**Fig.7.** An electron photomicrograph of transverse section of a control adult rat testis showing upper part of seminiferous tubule near lumen (L) demonstrating spermatid (ST) having round nucleus (N) covered by acrosomal vesicle (→) and cytoplasm containing multiple mitochondria (M). (X 1500)



**Fig.8.** A photomicrograph of an adult rat testis treated with di-n-butyl phthalate (DNP) showing most of seminiferous tubules (T) are markedly distorted with very wide lumen, no sperm and relative reduction in the thickness of their epithelial lining with sloughed cells in its lumen (\*). Acidophilic hyaline materials (H) are seen in the interstitium. Vacuolation (V) in the germinal epithelium as well as in the interstitium are observed. (Hx&E, X400)

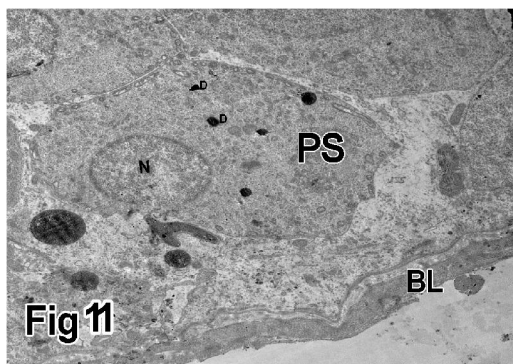


**Fig.9.** A photomicrograph of an adult rat testis treated with di-n-butyl phthalate (DNP) showing overall reduction in the PAS reaction in the seminiferous tubules (T), with loss of the magenta red discoloration due to arrest of germinal epithelium, loss of sperms (\*) and thickened basal lamina of the seminiferous tubules, which exhibited intense PAS reaction (→) (PAS stain, X400)

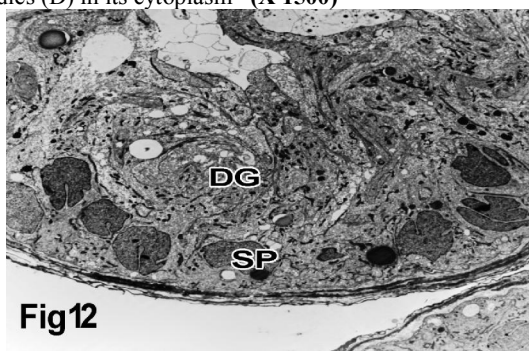


**Fig.10.** A photomicrograph of an adult rat testis treated with di-n-butyl phthalate (DNP) showing marked increase in the greenish connective tissue in the walls of the seminiferous tubules (→). There was also a thickening in the wall of blood vessels (B). (Masson's Trichrome, X400)

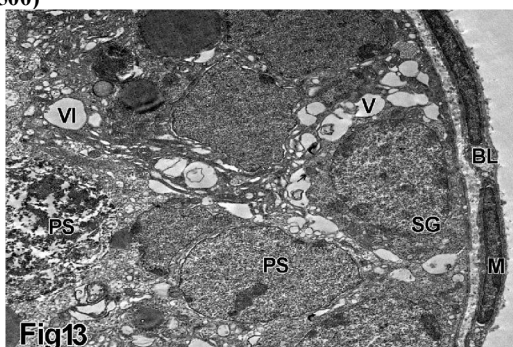




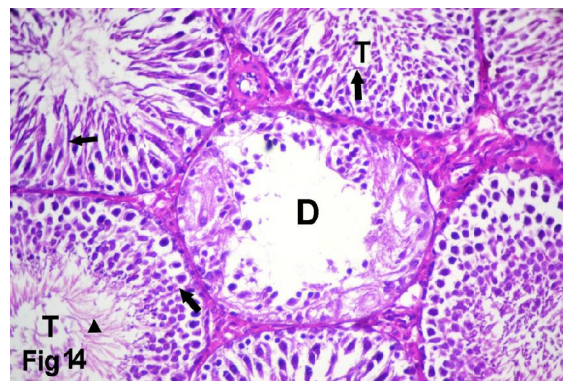**Fig.11.** An electron photomicrograph of transverse section of an adult rat testis treated with di-n-butyl phthalate (DNP) showing basal part of seminiferous tubule having thick irregular basement membrane (BL) and shrinkage primary spermatocyte (PS) which contain nucleus (N) and some dense bodies (D) in its cytoplasm (X 1500)



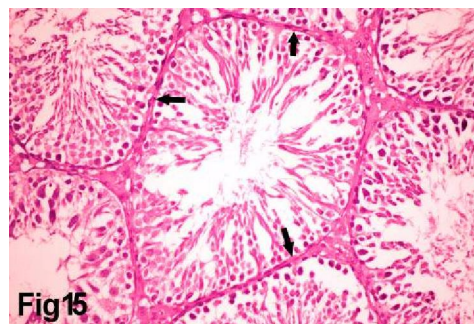
**Fig.12.** An electron photomicrograph of transverse section of an adult rat testis treated with di-n-butyl phthalate (DNP) showing seminiferous tubule with markedly distorted germinal epithelium (DG). There were overall different degrees of atrophy in the seminiferous tubules. At the same time a disorganization of the germinal epithelium, with loss of the spermatogenic cells specially spermatocytes and spermatids. Spermatogenic cells (SP) showed degeneration. (X 500)



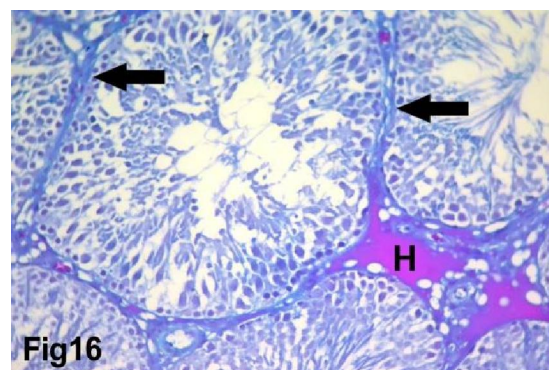
**Fig.13.** An electron photomicrograph of transverse section of an adult rat testis treated with di-n-butyl phthalate (DNP) showing lower part of seminiferous tubule having basal lamina (BL) containing myoid cell (M). Spermatogonia (SG) with cytoplasm contained multiple intercellular variable sized vacuoles (V), degenerated mitochondria (→) and dilated SER (curved arrow) was noticed. Degenerated primary spermatocytes (PS) were shown with different size intercellular vacuoles (VI). (X 1500)



**Fig.14.** A photomicrograph of an adult rat testis treated with di-n-butyl phthalate (DNP) and vitamin c & e showing the testes start to regain its normal general architecture. Many tubules are packed together with regular outline (T) but others are still distorted (D) with few sperms. Many tubules have stratification in their epithelium (→) and sperms are observed in their lumen (►) (Hx & E, X400)

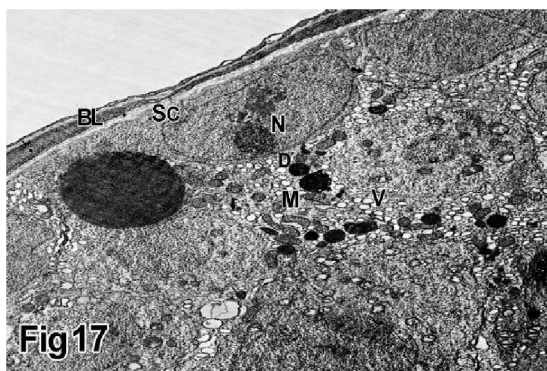


**Fig.15.** A photomicrograph of an adult rat testis treated with di-n-butyl phthalate (DNP) and vitamin c & e showing normal strong PAS positive reaction in the Basal Lamina of the Seminiferous tubules (→) when compared to (DNP) treated group (PAS stain, X400)

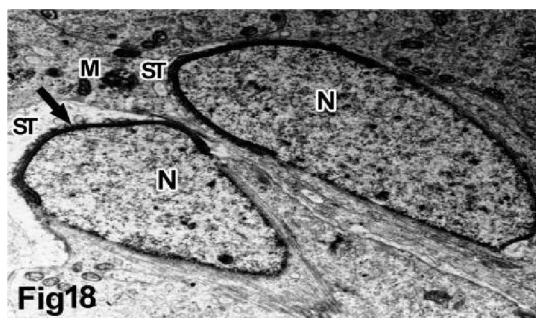


**Fig.16.** A photomicrograph of an adult rat testis treated with di-n-butyl phthalate (DNP) and vitamin c & e showing marked increase in the greenish connective tissue in the wall of seminiferous tubules (→). Hyalinization (H) can be observed in the interstitium. (Masson's Trichrome, X400)





**Fig.17.** An electron photomicrograph of transverse section of an adult rat testis treated with di-n-butyl phthalate (DNP) and vitamin c & e showing basal part of seminiferous tubule having irregular basal lamina (BL), sertoli cells (SC) with oval pale nucleus (N) near basal lamina. The cytoplasm of sertoli cells contain small vacuoles (v) and mitochondria (M), dense bodies (D) and still some dilated SER (→). (X 1500)



**Fig.18.** An electron photomicrograph of transverse section of an adult rat testis treated with di-n-butyl phthalate (DNP) and vitamin c & e showing part of seminiferous tubule demonstrating oval spermatid (ST) containing oval nucleus (N) covered by acrosomal vesicle (arrow) and mitochondria (M). (X 2500)

#### 4. Discussion

According to the national institute of health, male infertility involved approximately 40% of infertile human couple and the environmental causes represent one of the major factors affecting male fertility (Marcia, 2007). Di-n-butyl phthalate is one of the most widely used chemical as a plasticizer in cosmetics, printing inks and pharmaceutical coating (Alam et al., 2010). It has been associated with both reproductive and developmental toxicity in animal models (Hauser et al., 2004). The most prominent effect of di-n-butyl phthalate is testicular atrophy (Gray et al., 1982).

Therefore, the aim of the present study is to clarify the possible protective effect of vitamin C & E with di-n-butyl phthalate induced testicular germ cell toxic model using simple histological, histochemical and ultrastructure methods.

In the present study, rat treated with di-n-butyl phthalate showed significant morphological and morphometric changes compared to control rats. These

parameters include reduction in body, testis weight, tubular diameter and seminiferous epithelial height. Quantitative data obtained in the present study are in agreement with that available data from previous studies. For example, and inhibition of steroid biosynthesis of leydig cells.

Testicular tissue of control group shows normal general structure Chapin et al., (1997); Farombi et al., (2007) had reported nearly the same findings in their experiment. They stated that, the weight of the testis is largely dependent on the mass of the differentiated spermatogenic cells. They concluded that, the reduction of the weight of the testis may be due to reduced tubular size, spermatogenic arrest as finding reported by Sakr and Nooh, (2013) who described normal testis structure during their experiment and this proved that, studied animals were healthy.

In the present study, the seminiferous tubules basement membrane of the experimental group showed thickening which was reported by Santoro et al., (1999) in their study. They concluded that, exogenous stimulant may induce myoid cells to produce more collagen and extracellular matrix which are responsible for increase basal lamina thickness and may change its appearance to irregular wavy multilaminar shape.

In the current study, observation of seminiferous tubules with detached, disorganized germ cells and dislocation of spermatozoa to positions that are closely related to the basement membrane was reported and confirmed by decreased seminiferous epithelial height in group administered di-n-butyl phthalate. These findings was in agreement with Richburg (2000) who explained his results may be due to the rapid disruption of sertoli-germ cell interaction due to disturbance of normal supportive function of sertoli cells as a result to exposure to some drugs and injurious toxicants. The physical interaction ultimately leads to sloughing of the germ cells from the seminiferous epithelium.

Microscopic examination of the testicular sections of di-n- butyl phthalate treated rats showed vacuolation in the germinal epithelium as well as interstitium. Feinberg et al., (1997) reported interstitium vacuolation in their experimental animals, he explained his finding may be due to depletion of lydig cells due to its close relation to blood vessel suggests that these cells are at high risk to exogenous toxicant. While the results of Gopalkrishnan et al., (1998) showed vacuolation in germinal epithelium which may be resorted to progressive apoptosis of the sertoli cells, which affect spermatogenesis and sperm parameters. Additionally, Blanco et al., (2002) described that, apoptosis occurred in all germ line cells especially in spermatogonia and spermatocytes The apoptotic bodies can be phagocytosed by sertoli cells as



reported by **Neishimura et al., (1995)**. Some previous reports suggested that vacuoles present in some seminiferous tubules may represent phagocytic vacuoles remained after the digestion of the necrotic germ cells as a result of vacuolar degeneration which may be found in parenchymatous organs subjected to toxicant, poisons and stress (**Walter and Talbot, 1996**).

Under normal conditions, apoptosis maintains the number of germ cells within the supportive capacity of sertoli cells. However disturbances in this pathway can interrupt the spermatogenic cascade (**Tesarik et al., 1998**)

During the course of this investigation, electron microscopic results of group III which received DNP revealed vacuolation of the cytoplasm, dilatation of SER and mitochondrial affection in the different types of spermatogenic cells. Dilatation of SER in spermatogonia was reported in some areas. **Trump et al., (1965)**; **Ali et al., (2008)** postulated that, changes in SER were among the earliest evidence of the cellular damage, and its enlargement may reflect the accumulation of water inside it. Later, **Wing and Chistensen (1982)** interpreted the dilatation of SER as a result of the functional derangement of ATP-dependent membrane transport mechanism of the cell which result in accumulation of water inside SER. However, **Roncero et al., (1992)** explained that, this change might be a consequence of final hypoactivity prior to cell necrosis. Also, in this study, mitochondria showed degeneration and destruction of their cisternae in spermatogonia in some areas, this finding explained by **Singer, (1987)** as those mitochondrial changes might represent a very clear demarcation of early pathological development.

This study shows the possible protective effect of vitamin C and E. Vitamin C is associated with the regeneration of  $\alpha$ -tocopherol. It supplies electrons necessary for hydroperoxide reductase that directly reduces  $\alpha$ -tocoperoxy radical to  $\alpha$ -tocopherol, thus contributing toward the protection of cellular membranes (**Chepda et al., 2001**). Vitamin E is an important antioxidant, plays a role in inhibition of mutagen formation, and repair of membranes and DNA. Therefore, it has been suggested that, vitamin E may be useful in cancer prevention (**Saalu et al., 2007**). It has two important functions in the membrane: as a liposoluble antioxidant that prevent reactive oxygen species damage in polyunsaturated fatty acids and also as membrane stabilizer agent acting against the damage caused by phospholipid (**Parra-vizute et al., 2009**).

In the current study, examination of the seminiferous tubules of the group IV, which received di-n-butyl phthalate along with vitamin C & E, revealed that, the tubules start to regain its normal general architecture and outlines with exception of

some tubules are packed together with distorted outlines. Many tubules retained its sperms in their lumen. Our results are in agreement with previous studies which focused on chemoprevention of phthalate effects through supplementation with antioxidants. **Ishihara et al. (2000)** observed the possible protective effect on vitamins C and E on DEHP-induced spermatogenesis. They concluded that, Vitamin E can protect critical cellular structures against damage from both free radicals such as peroxy radical, hydroxyl radical, and super oxide and from oxidation products such as malondialdehyde and hydroxynonenal. In other studies,, Isolated vitamin C or in association with vitamin E, has been used as an antioxidant for the prevention of harmful effects of many toxic compounds such cadmium (**Acharya et al., 2008**), sulfur dioxide (**Zhao et al. 2008**), and hexavalent chromium (**Hemmati et al. 2008**). Additionally significant improvement in the histological profiles of the cryptorchid testes of vitamin-E-treated group was observed as compared to the cryptorchid alone group (**Rahangadale et al., 2012**). Partial protective role of vitamin E was recorded earlier during ethane dimethane sulfonate-induced testicular toxicity in rats (**Sahinturk et al., 2007**).

#### Conclusion:

Toxic effect of Di-N-Butyl phthalate should be kept in mind during chronic usage. Vitamin C & E advised to be administered in concomitant with DBP as it could ameliorate its adverse effect on rat testis.

#### Corresponding author:

Manar A.Bashandy  
Anatomy Department, Faculty Medicine- Menoufyia University – Egypt.  
E-mail: [A\\_z491@yahoo.com](mailto:A_z491@yahoo.com).

#### References

1. Acharya, R.; Mishra, M.; Patro, J. and Panda, K. (2008): Effect of vitamins C and E on spermatogenesis in mice exposed to cadmium. *Reprod Toxicol*; 25:84–88.
2. Aiad, H.; Abdou, A.; Bashandy, M.; Said A.; Ezz-Elarab, S. and Zahran, A. (2008): Computerized nuclear morphometry in diagnosis of thyroid lesions with predominant follicular pattern. *J. Egypt Soc. Path.* 28 (1), june: 105-13.
3. Alam, M.; Ohsako, S.; Matsuwaki, T.; Zhu, X.; Tsunekawa, N.; Kanai, Y.; Sone, H.; Tohyama, C. and Kurohmaru, M. (2010): Induction of spermatogenic cell apoptosis in prepubertal rat testis irrespective of testicular steroidogenesis: a possible estrogenic effect of di (n-butyl) phthalate. *Reproduction*; 139: 427-37.
4. Ali, A.; Ktan, A.; Alqudsi, F. and Karim, S. (2008): Ultrastructural changes of the testicular tissues of immature and mature mice under the effect of lithium carbonate. *Bull. Alex. Fac. Med.* 44 (3):805-15.

5. Bao, A.; Man, X.; Guo, X.; Dong, H.; Wang, F.; Sun, H.; Wang, Y.; Zhou, Z. and Sha, J. (2011): Effects of di-n-butyl phthalate on male rat reproduction following pubertal exposure. *Asian J. of Andrology*;13: 702-9.
6. Bashandy, M.; Zanaty, A.; El-eidy, A. and El-Shafie, M. (2012): Combined effects of vitamin C and E on acute ethanol toxicity of the liver and jejunum of albino rats: histological, immunohistochemical and biochemical. *Egyptian J. of Histology*.Vol.35 (3):496-508.
7. Batra, N.; Nehru, B. and Bansal, M. (2001): Influence of lead and zinc on rat male reproduction at biochemical and histological level. *J. Applied. Toxicology*; 21:507-12.
8. Blanco, A.; Flores-Acuna, F.; Roldan-villalbos, R. and Monterde, J. (2002): Testicular damage from anabolic treatment with the beta (2)-adrenergic agonist clenbuterol in pigs: a light and electron microscope study. *Vet. J*; 163(3): 292-98.
9. Borch, J.; Metzдорff, B.; Vinggaard, M.; Brokken, L. and Dalgaard, M. (2006): Mechanisms underlying the anti-androgenic effects of diethylhexyl phthalate in fetal rat testis. *Toxicology*; 223: 144–55.
10. Bosnir, J.; Puntaric, D.; Skes, I.; Klaric, M. and Simic, S. (2003): Migration of phthalates from plastic products to model solutions. *Coll Antropol*; 27 (Suppl 1): 23–30.
11. Chapin, R.; Harris, M. and Davis, B. (1997): The effect of perinatal juvenile methoxychlor exposure on adult rat nervous, immune and reproductive system function. *Fundam Appl Toxicol*; 40: 138-57.
12. Chepda, T.; Cadau, M.; Lassabliere, F.; Reynaud, E.; Perier, C.; Frey, J. and Chamson, A. (2001): Synergy between ascorbate and  $\alpha$ -tocopherol on fibroblasts in culture. *Life science*; 69: 1587-96.
13. El-Gendy, K.; Aly, N.; Mahmoud, F.; Kenawy, A. and El-Sebae, A. (2010): The role of vitamin C as antioxidant in protection of oxidative stress induced by imidacloprid. *Food Chem. Toxicol*;48: 215-221.
14. Farombi, E.; Abarikwu, S.; Adedara, I. and Oyeyemi, M. (2007): Curcumin and Kolaviron ameliorate Di-n-Butylphthalate Induced testicular damage in rats. *Basic and Clinical Pharmacology and Toxicology*; 100: 43-48.
15. Feinberg, M.; Lumia, A. and McGinnis, M. (1997): The effect of anabolic-androgenic steroids on sexual behavior testicular morphology and serum hormonal profile of reproductive hormones. *Contras and reproductive tissues in male rats. Physio. Behav*; 62(1):23-30.
16. Fukuoka, M.; Zhou, Y.; Tanaka, A.; Ikemoto, I. and Machida, T. (1990): Mechanism of testicular atrophy induced by di-n-butyl phthalate in rats. Part 2.The effects on some testicular enzymes. *Journal of Applied Toxicology*; 10: 285-93.
17. Gopalkrishnan, K.; Gill-Sharma, M.; Balasinor, N.; Padwal, V.; D'Souza, S. and Parte, P. (1998): Tamoxifen induced light and electron microscopic changes in the rat testicular morphology and serum hormonal profile of reproductive hormones. *Contraception*; 57(4): 261-69.
18. Gray, T.; Rowland, I.; Foster, P. and Gangolli, S. (1982): Species differences in the testicular toxicity of phthalate esters. *Toxicology Letters*; 11: 141– 47.
19. Gray, L.; Wilson, V.; Stoker, T.; Lambright, C. and Furr, J. (2006) : Adverse effects of environmental anti-androgens and androgens on reproductive development in mammals. *Int J Androl*; 29: 96–104.
20. Gurel, A.; Coskun, O.; Armutcu, F.; Kanter, M. and Ozen, O. (2005): Vitamin E against oxidative damage caused by formaldehyde in frontal cortex and hippocampus: Biochemical and histological studies. *J Chem-Neuroanat*; 29: 173-8.
21. Hauser, R.; Duty, S.; Godfery-Bailey, L. and Calafat, A. (2004): Medications as a source of human exposure to phthalates. *Environ Health Perspect*; 112: 751-3.
22. Hemmati, A.; Nazari, Z.; Ranjbari, N. and Torfi, A. (2008) Comparison of the preventive effect of vitamin C and E on hexavalent chromium induced pulmonary fibrosis in rat *Inflammo-pharmacology*;16:195 – 97.
23. Higuchi, T.; Palmer, J.; Gray, L. and Veeramachaneni, D. (2003): Effects of di-butyl phthalate in male rabbits following in utero, adolescent, or post-pubertal exposure. *Toxicol. Sci*; 72: 301-13.
24. Hsu, P.; Liu, M.; Hsu, C.; Chen, L. and Guo, Y. (1998): Effects of vitamin E and/or C on reactive oxygen species related lead toxicity in the rat sperm. *Toxicology*; 128(3): 169-79.
25. Hubinger, C. and Havery, C. (2006): Analysis of consumer cosmetic products for phthalate esters. *J. Cosmet Sci*;57: 127– 37.
26. Ishihara, M.; Itoh, M.; Miyamoto, K.; Takeuchi, Y.; Takenaka, I. and Jitsunari, F. (2000): Spermatogenic disturbance induced by di-(2-ethylhexyl) phthalate is significantly prevented by treatment with antioxidant vitamins in rat. *Int J Androl*; 23: 85-94
27. Kavlock, R.; Boekelheide, K.; Chapin, R. and Cunningham, M. (2002): NTP center for the evaluation of risks to human reproduction: phthalates expert panel report on the reproductive and developmental toxicity of di(2-ethylhexyl) phthalate. *Reprod Toxicol*; 16: 529– 653.
28. Kleyменова, E.; Swanson, C.; Boekelheide, K. and Gaido, K. (2005): Exposure in utero to di (n- butyl) phthalate alters the vimentin cytoskeleton of fetal rat Sertoli cells and disrupts Sertoli cell- gonocyte contact. *Biol. Reprod*; 73: 482-90.
29. Lodhi, G.; Hameed, W.; Ahmed, T.; Latif, R. and Aslam, M. (2011): Effects of ascorbic acid and alpha tocopherol supplementation on basal testosterone cortisol ratio in male Sprague Dawley rats. *Pak. J Physiol*; 7(2); 7-10.
30. Mahood, I.; Hallmark, C.; McKinnel, M. and Walker, J. (2005): Fisher and R.M. Sharpe: Abnormal Leydig cell aggregation in the fetal testis of rats exposed to di (n-butyl) phthalate and its possible role in testicular dysgenesis. *Endocrinol*; 146: 613-23.
31. Marcia, C. (2007): Masculinity, Reproduction and male infertility in the Middle East. *J. of the Middle East Woman studies*; 3 (3): 1-20.
32. Murugesan, P.; Muthusamy, T.; Balasubramanian, K. and Arunakaran, J. (2005): Studies on the protective role of vitamin C and E against polychlorinated



- biphenyl (Aroclor 1254)- induced oxidative damage in Leydig cells. *Free Radic Res*; 39: 1259-72.
33. Nair, N.; Bedwal, S.; Kumari, D.; Bedwal, S. and Bedwal, R. (2008): Effect on histological and sperm kinetics in DBP exposed Wistar rats. *Journal of Environmental Biolog*; 29(5): 769-72.
  34. Neishimura, T.; Aze, Y. and Ozeki, Y. (1995): Effects of nitrofurazone on spermatogenesis and reproductive toxicity in male rats: Part of a collaborative work to determine optimal administration period and end points. *J. Toxicological Sciences*; 20: 341- 49.
  35. Oberley, T.; Swanlund, J.; Zhang, H. and Kregel, K. (2008): Aging results in increased autophagy of mitochondria and protein nitration in rat hepatocytes following heat stress. *J. Histochem. Cytochem*; 56(6): 615-27.
  36. Ozden, S.; Catalgol, B.; Gezginci-Oktayoglu, S.; Arda-Princci, P.; Bolkent, S. and Alpertunga, B. (2009): Methiocarb induced oxidative damage following subacute exposure and the protective effects of vitamin E and taurine in rats. *Food Chem. Toxicol*; 47:1676-84.
  37. Parra-vizuet, J.; Camacho-Luis, A.; Madrigal-Santillan, E.; Bautisata, M.; Esquivel-Soto, J. and Esquivel-Chirino, C. (2009): Hepato-protective effects of glycine and vitamin E, during the early phase of liver regeneration in the rat. *Afr. J. Pharm Pharmacol*; 3: 384-90.
  38. Peat, J. and Barton, B. (2005): Medical statistics. A Guide to data analysis and critical appraisal. First Edition. Wiley- Blackwell. 113-19.
  39. Rahangdale, S.; Jangir, B.L.; Patil, M.; Verma, T.; Bhandarkar, A.; Sonkusale, P. and Kurkure, N. (2012): Evaluation of protective effect of vitamin E on acrylamide induced testicular toxicity in Wistar rats. *Toxicol Int*; 19:158-61.
  40. Richburg, J. (2000): The relevance of spontaneous and chemically induced alterations in testicular germ cell apoptosis to toxicology. *Toxicol. Lett.*; 113:79 – 86.
  41. Roncero, V.; Duran, E.; Soler, F.; Masot, J. and Comez, L. (1992): Morphometric and ultrastructural studies of tench (*tinca tinca*, L) after copper sulfate administration. *Environ Res*; 57: 45-58.
  42. Saalu, L.; Oluyemi, K. and Omotuyi, I. (2007):  $\alpha$ -Tocopherol (vitamin E) attenuates the testicular toxicity with experimental cryptorchidism in rats. *Afr. J. Biotechnol*; 6:1373-77.
  43. Sahinturk, V.; Guclu, C. and Baycu, C. (2007): Protective effect of vitamin E on ethane dimethane sulfonate-induced testicular toxicity in rats. *Asian J Androl*; 9:117-24.
  44. Sakr, A. and Nooh, H. (2013): Effect of *Ocimum basilicum* extract on cadmium-induced testicular histomorphometric and immunohistochemical alterations in albino rats. *Anat Cell Biol*; 46: 122-30.
  45. Santoro, G.; Romeo, C.; Impellizzeri, P.; Arco, A.; Rizzo, G. and Gentile, C. (1999): A morphometric and ultrastructural study of the changes in the lamina propria in adolescents with varicocele. *BJU. Int*; 83(7): 828-32.
  46. Shanna, H.; Eric, P. and Laura, F. (1997): Have sperm density decline ? Are analyses of global trend data. *Environ Health Perspect*; 105: 1228-32.
  47. Singer, H. (1987): Response of fed and starved roach, *Rutilus lethal* copper contamination. *J. Fish Biol*; 30: 423-37.
  48. Stevens, A. and Wilson, G. (1996): The haematoxylin and eosin. In: Bancroft, J, Stevens, A and Turner, D: (Theory and practice of histological techniques. 4<sup>th</sup> edition: Churchill Livingstone, New York.
  49. Tesarik, J.; Greco, E.; Cohen-Bacrie, P. and Mendoza, C. (1998): Germ cell apoptosis in men with complete and incomplete spermiogenesis failure. *Mol. Human. Reprod*, 4(8): 757-62.
  50. Thompson, C.; Ross, S.; Hensley, J.; Liu, K. and Heinze, S. (2005): Differential steroidogenic gene expression in the fetal adrenal gland versus the testis and rapid and dynamic response of the fetal testis to di(n-butyl) phthalate. *Biol Reprod*; 73: 908–17.
  51. Trump, B.; Gldbt, P. and Stowell, R. (1965): Studies of necrosis in vitro of mouse hepatic parenchyma cells. Ultra structure alterations in endoplasmic reticulum, Golgi apparatus, plasma membrane and lipid droplets. *Lab. Invest*; 14: 2000-28.
  52. Walter, J. and Talbot, I. (1996): Walter and Talbot general pathology. 7<sup>th</sup> Edition. Churchill Livingstone. New York Cell response to injury. P.87.
  53. Wing, T. and Chistensen, K. (1982): Morphometric studies on rat seminiferous tubules. *Am. J. Anat*; 165:13-25.
  54. Zhang, Y.; Jiang, X. and Chen, B. (2004): Reproductive and developmental toxicity of F1 Sprague Dawley male rats exposed to di-n-butyl phthalate in-utero and during lactation and determination of its NOEL. *Reprod. Toxicol.*; 18: 669-76.
  55. Zhao, H.; Xu, X.; Na, J.; Hao, L.; Huang, L.; Li, G. and Xu, O. (2008): Protective effects of salicylic acid and vitamin C on sulfur dioxide-induced lipid peroxidation in mice. *Inhal. Toxicol* 20:865–71.

10/25/2014