

## Usefulness of 128 slice Multidetector Computed Tomography in evaluation of Coronary Stent Patency

Mai E.M. Khamis<sup>1\*</sup>, Ghada A Abdel monem<sup>1</sup>, Enass M Khattab<sup>1</sup>, Hisham Samir Roshdy<sup>2</sup>.

<sup>1</sup>Radiodiagnosis Department, Faculty of Medicine, Zagazig University, Egypt.

<sup>2</sup>Cardiology Department, Faculty of Medicine, Zagazig University, Egypt.

\*maikhamis2@yahoo.com

**Abstract: Objectives:** The objective of the study was to assess diagnostic performance of 128 slice multidetector computed tomography (MDCT) in the evaluation of coronary stent patency. **Patients and methods:** Twenty two patients with 30 evaluable coronary stents were included, they examined by 128 slice MDCT followed by conventional coronary angiography. **Results:** In MDCT, stent restenosis was diagnosed in 6 stents (3 were confirmed by conventional angiography as true positive and 3 were false positive) and stent occlusion was diagnosed in 4 stents (proved by conventional angiography as 3 true positive and 1 false positive). Twenty stents were correctly diagnosed as patent by MDCT (proved by conventional angiography as true negative). The sensitivity, specificity, positive predictive value, negative predictive value and accuracy of MDCT was 100 %, 83.3%, 60%, 100% and 86.7 % respectively. **Conclusion:** The 128 MDCT is an appropriate non invasive method for assessment of coronary stent patency and it is a good negative test for exclusion of stent occlusion or restenosis. [Mai E.M. Khamis, Ghada A Abdel monem, Enass M Khattab, Hisham Samir Roshdy. **Usefulness of 128 slice Multidetector Computed Tomography in evaluation of Coronary Stent Patency.** *J Am Sci* 2017;13(1):116-122]. ISSN 1545-1003 (print); ISSN 2375-7264 (online). <http://www.jofamericanscience.org>. 16. doi:[10.7537/marsjas130117.16](https://doi.org/10.7537/marsjas130117.16).

**Keywords:** stent, MDCT, occlusion, re stenosis, patent.

### 1. Introduction:

Currently the prevalent method for non-surgical myocardial revascularization is Coronary artery stenting [1,2].

Restraint of neointimal proliferation by the local pharmacological interference (as sirolimus, rapamycin) is a recently developed technique. The clinical experience of drug eluting coronary stents has represent premium results at angiographic follow up at 240 days with 3.2% restenosis with the drug eluting stent as compared to 34.5% with bare-metal stents [3].

In spite of huge improvement in treatment, in-stent restenosis (ISR) still a major issue after coronary stenting [4].

The conventional coronary angiography has deemed as a gold standard for early recognition of stent complications, yet it conveys a risk of morbidity and mortality, hence there is increased demand for using Multidetector Computed Tomography (MDCT) which is a noninvasive alternative in evaluation of coronary in - stent restenosis [2].

4-slice CT was the first commonly utilized non-invasive imaging method in the evaluation of coronary artery stents, but the direct visualization of the in stent lumen was nearly impossible due to limited spatial and temporal resolution, and early researches concentrated on the visual estimation of the distal runoff. With the development of 16-slice CT, the direct visualization of the in stent lumen had become conceivable [5]. Even so, in stents with small diameters (>3mm) and/or stents with thicker struts, the perception of in-stent

stenosis remains an issue that is due to high-contrast artifacts which hinder the precise differentiation between plaques and struts [6,7].

The higher spatial and improved temporal resolution in 64 and 128 section multidetector CT result in better imaging quality and lead to improve stent evaluation [4,8].

Technical improvements with the 128-slice MDCT provide multiple advantages compared to the 64-slice MDCT. The wider coverage of 128-slice MDCT, together with a fast gantry rotation results in shorter acquisition times and therefore relaxes the breath-hold requirements [9].

The objective of this study was to assess diagnostic performance of 128 slice MDCT in the evaluation of coronary artery stent patency.

### 2. Patients and methods

Twenty two patients were included in this study between September 2015 and October 2016. This study was carried out in diagnostic radiology and cardiology departments at Zagazig University Hospital.

The institutional review board of our hospital approved this study and informed consent was obtained from all patients.

Twenty two patients were included in this study, they were 19 males and 3 females and their ages ranged between 43 to 71 years. In these 22 patients, 35 stents were examined. The mean time interval between

stent placement and CTA was (8.36 months) and the range was (5-12 months).

All inclusion criteria were fulfilled.

**Inclusion criteria:**

- Patient with recurrent angina like symptoms after coronary artery stenting.
- Patient with positive follow up stress electrocardiography and or thallium scan for myocardial ischemia after coronary artery stenting.

**Exclusion criteria:**

- Patients with impaired renal function.
- Patients with history of allergy to the IV contrast media.
- Patients with irregular heart rhythm (AF, Frequent premature beats uncontrollable with medications).
- Patients who can't follow breath-hold requirements.

Patients were subjected to the following:

- Full history taking, including personal data & risk factors e.g. DM, smoking.
- History about number, type, length, diameter of the stents and time and site of implantation.

**Preparation of the patient**

All patients were informed to fast 4-6 hours before the examination and stop taking phosphodiesterase inhibitors.

Beta blockers (50 mg oral metoprolol) were administered in patients with heart rate above 65 bpm. (provided that contraindications to B blockers are excluded).

The patient was positioned supine on the scanner table and ECG leads were applied to the chest wall.

Reassurance of the patient was done and all steps of the study were explained in details to each patient. The patients were informed that good breath holding is crucial and practice breath-withholding.

**\*Contrast media injection:**

A bolus of (1ml / kg) of non-ionic contrast (Ultravist 370) was injected through 18-gauge cannula into an upper limb vein (right ante-cubital vein is preferred when available) with a flow rate of 5-6 ml/sec using a programmed dual head power injector pump. A saline chaser bolus was used (50ml) to washout the contrast from the right side of the heart.

**CT Scan protocol and parameters:**

All CT examinations were done using 128 section multidetector CT scanner (Philips Ingenuity core 128 TM).

We used an individual detector collimation of 64 × 0.6 mm and a gantry rotation time of 300 ms, 150 ms temporal resolution. (pitch, 0.2). A tube voltage of 120 kV, tube current of 430 mAs, Scanning time was about 10 seconds (depending on the field of view,

which was chosen as small as possible) in a single breath hold.

Initially a scanogram is obtained in an antero-posterior and lateral views of the chest that is used to position the imaging volume of the coronary arteries that extends from the level of the carina inferiorly to the base of the heart.

The prospective ECG gated scan was used in one single breath-hold.

Bolus-tracking technique was used in all patients. The region of interest (ROI) was set on the ascending aorta carefully avoiding the athermanous calcifications, the trigger threshold set at 100 HU. After a delay of about 10 seconds from the start of injection; series of axial images at the aortic root (at the level of the origin of the left main coronary artery) is acquired. When desired threshold is reached, the scanning is started while the patient is instructed to hold breathing).

**Post processing reconstruction:**

A slice thickness of 0.6mm reconstructions was used with sharp convolution kernel (Brilliance Intellispace 7). The reconstructed axial images at different points of the cardiac cycles are sent to the workstation.

The images were reconstructed during the mid-to-end diastolic phase (65-75% of the R-R interval of the cardiac cycle), if the image quality in this phase was not the optimal, additional reconstructions (at 35–85% of the R-R interval of the cardiac cycle) were done and we choose the most appropriate post processing phase which allow the best visualization of the coronary arteries.

Multiphase reconstruction (MPR) in axial, sagittal and coronal planes as well as curved planar reformation are performed. Also 3 D Volume rendering images were obtained.

**Interpretation of CT images:**

Assessment of image quality

A systematic review of axial images was done to evaluate quality of the study in terms of contrast opacification, and the detection of potential artifacts leading to interferences on the reconstructed images.

We classified the CT images of stented segments into 4 grades: Grade 1, visible stent and stent lumen with no metal artifacts; grade 2, visible stent and stent lumen with slight metal artifacts; grade 3, visible stent but invisible stent lumen with significant metal artifacts; grade 4, invisible stent and stent lumen with severe metal artifacts.

**Stent Lumen Evaluation**

Assessment of stent patency was based on direct visualization of the in-stent lumen. An accurate intraluminal evaluation was best performed by multiphase reformation of the CT data.

Neointimal hyperplasia typically occurred as a localized non-enhancing lesion between the stent and the enhanced vessel.

The stent was diagnosed as patent if there is complete enhancement of the stent lumen with no non enhancing lesion between the stent and the enhanced vessel.

If neointimal hyperplasia exerting less than 50% narrowing of the luminal diameter, it is considered non-significant in-stent restenosis.

If neointimal hyperplasia exerting a luminal diameter narrowing of more than or equal 50%, it is consistent with significant in-stent restenosis.

Stent occlusion means: 100% luminal diameter narrowing (total absent of contrast within the stent lumen) (Colombo *et al.*, 2010).

Conventional coronary angiography was performed within 3-4 days for all patients, using GE innova 2100 interventional X-ray system (Chicago, IL, USA) according to standard unit protocol, coronary angiography was done after MDCT for confirmation of the CT findings.

#### Statistical analysis:

All data were collected and statistically analyzed using SPSS 20.0 for windows (SPSS Inc., Chicago, IL, USA).

Quantitative data were expressed as the mean  $\pm$  SD and qualitative data were expressed as absolute frequencies (number) & relative frequencies (percentage).

Validity of MDCT in the evaluation of stent patency was calculated using diagnostic performance depend on sample 2x2 contingency tables. The sensitivity, specificity, positive predictive value, negative predictive value, accuracy with their respective 95% confidence intervals were calculated.

Independent Student t-test was used to compare two groups of normally distributed data. Percent of categorical variables were compared using Chi-square test or Fisher's exact test when appropriate.

$p$  value  $< 0.05$  was considered statistically significant (S).

### 3. Results

Thirty five stents were examined in 22 patients. Five stents were non evaluable (4 stents with grade 3 and one stent with grade 4 image quality) and excluded from our results, while the remaining 30 stents were evaluable (20 stents with grade 1 and 10 stents with grade 2 image quality) and included in our results. Fifteen patients (68.2 %) had 1 stent, the stented artery was LAD in 10 patients (45.5%), LCX in 2 patients (9.1%) and RCA in 3 patients (13.6%). Six patients had two stents, the stented arteries were in 2 patients (9.1%) LAD and LCX, in 3 patients (13.6%)

LAD and RCA and 1 patient (4.5%) LCX and RCA. Only one patient (4.5%) had 3 stents, the stented arteries were LAD, LCX and RCA.

Thirteen stents were  $< 3$  mm in diameter and 17 stents was  $\geq 3$  mm in diameter. Thirteen stents were bare metal and 17 stents were drug eluting.

In MDCT angiography stent restenosis was diagnosed in 6 stents (3 were confirmed by conventional angiography as true positive and 3 were false positive) and stent occlusion was diagnosed in 4 stents (proved by conventional angiography as 3 true positive and 1 false positive). Twenty stents were correctly diagnosed as patent by MDCT (proved by conventional angiography as true negative) [table1]. The sensitivity of MDCT was (100 %), specificity was (83.3%), positive predictive value was (60%), negative predictive value was (100%) and accuracy was (86.7 %) [Table 2].

Table (1) comparison of MDCT and conventional angiography results.

	MDCT	conventional angiography
<b>Occluded</b>	4	3
<b>Restenosis</b>	6	3
<b>Patent</b>	20	24
<b>Total</b>	30	30

Table (2) Diagnostic performance of MDCT.

	Value %
<b>SN</b>	100 %
<b>SP</b>	83.3 %
<b>PPV</b>	60 %
<b>NPV</b>	100 %
<b>Acc</b>	86.7 %
SN: Sensitivity SP: Specificity PPV: Positive Predictive Value. NPV: Negative Predictive Value. Acc: Accuracy	

There was a statistically significant difference between cases with bare metal stents (4 cases) and cases with drug eluting stents (2 cases) as regard time of occlusion/restenosis ( $p$  value 0.01). The mean time was  $9 \pm 0.77$  and 18 months respectively.

No statistically significant difference was found between cases with stent  $< 3$  mm in diameter and with stent  $\geq 3$  mm diameter as regard stent patency ( $p$  value 0.41). Also, there was no statistically significant difference between the stented artery as regard stent patency ( $p$  value 0.74) and between the number of stents as regard stent patency ( $p$  value 0.87).

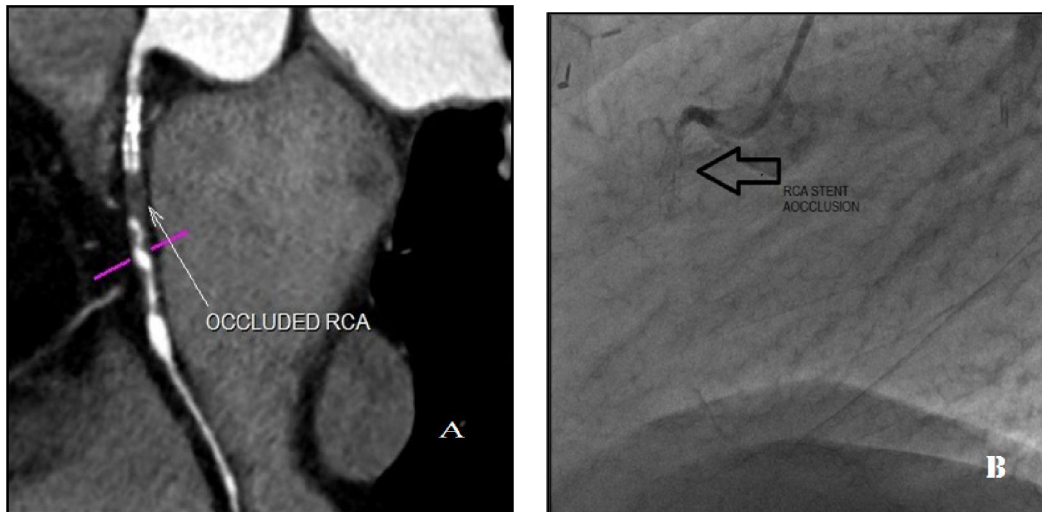

Figure (1): 65 years old male patient, he is diabetic and hypertensive. A bare metal 3x12 mm stent is placed in RCA 7 months ago. (A) MDCT angiography in MPR shows occluded stent in RCA. (B) Catheter angiogram confirmed the occlusion of stent in RCA.

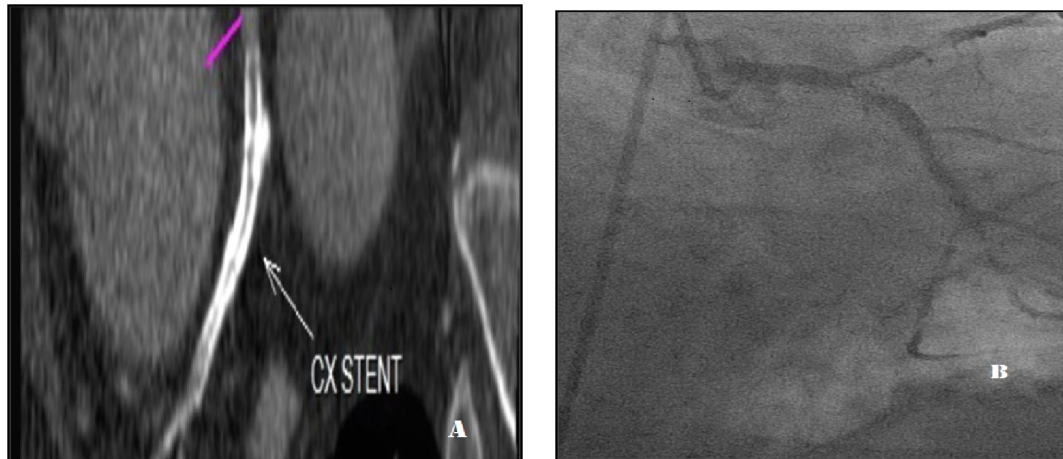
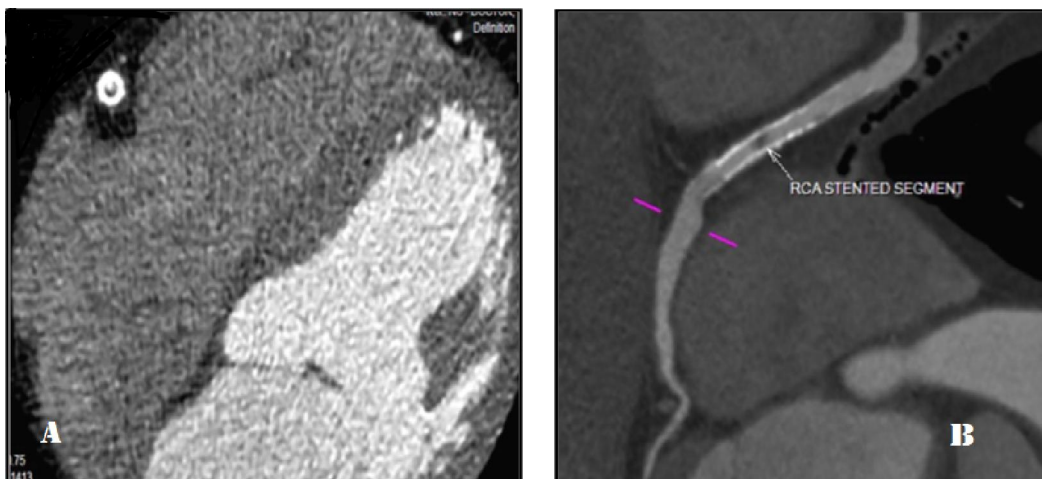

Figure (2): 52 years old male patient, he is hypertensive and smoker. A bare metal 2.5x24 mm stent is placed before 9 months in proximal LCx. (A) MDCT angiography in MPR shows occluded stent in proximal LCx. (B) Catheter angiogram shows that the stent is patent.





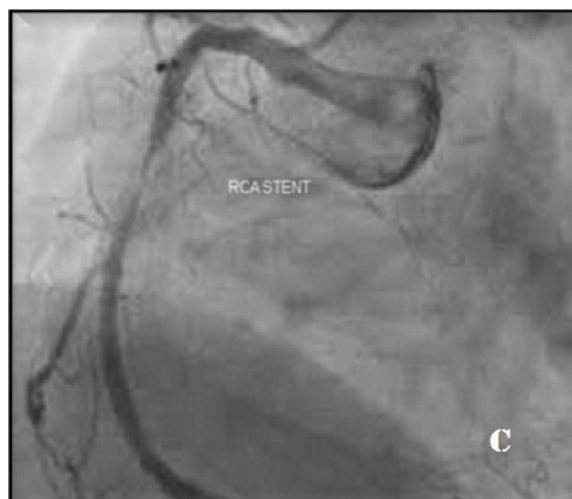

Figure (3): 43 years old female patient, she is diabetic and hyperlipidaemic. A bare metal 3x 15 mm stent is placed in mid RCA before 7 months. (A) MDCT angiography axial image shows crescent shape hypodensity encroaching upon the lumen causing an in stent restenosis, (B) MDCT angiography in MPR image shows the in stent restenosis in stented RCA segment. (C) Catheter angiogram confirming the in-stent restenosis.

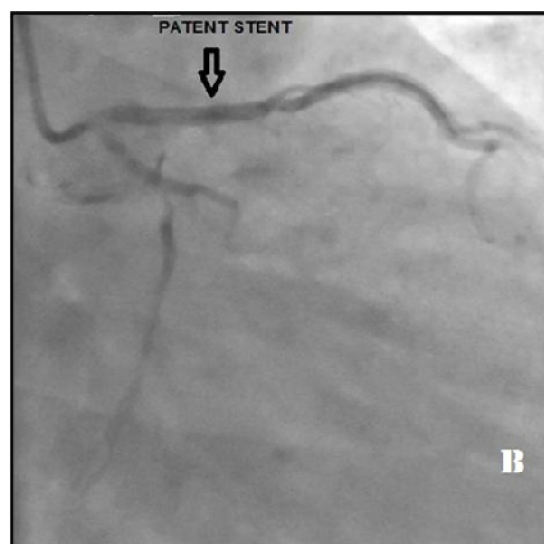
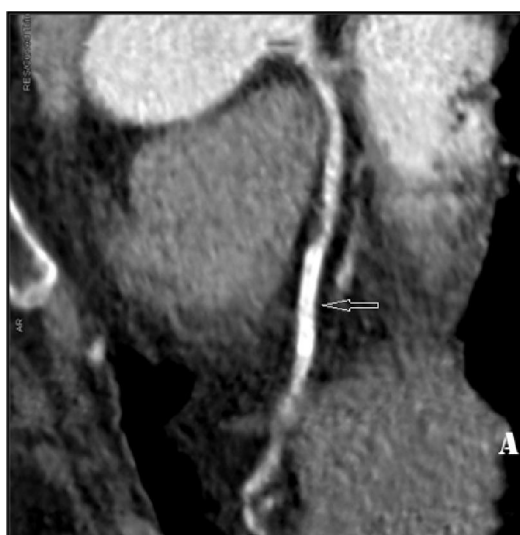

Figure (4): 63 years old female patient. A bare metal 2.5x16 mm stent is placed in LAD before 8 months. (A) MDCT angiography MPR image shows in stent restenosis in LAD (B) Catheter angiogram shows that the stent is patent.

#### 4. Discussion

The evaluation of stent patency represent a big issue in the follow-up patients undergoing stent placement. So it is desirable to avoid the use of expensive and invasive conventional angiography in the assessment of stent patency [10].

The 128 dual source MDCT is one of the new generations and the increase in temporal resolution together with smooth filters and fast acquisition times make it a helpful noninvasive tool [9].

In patients with coronary artery stents, high-attenuation artifact is attributable to beam-hardening and partial volume-averaging effects [4]. Increased

spatial resolution and concordant reductions in voxel size lessen these effects, and partially account for the greater accuracy of 128-slice MDCT [9].

The control of heart rate is still essential even with the utilization of 320 multislice CT, to acquire great quality images, as well as lower radiation dose to the patients. The slower ( $\leq 65$  bpm) heart rate enhances the temporal resolution and results in nearly motion free images. It additionally allows the utilization of prospective ECG-gating [11].

In our study, we attempt to keep the heart rate  $\leq 65$  bpm, by using oral metoprolol in patients with

heart rate < 65 bpm. So we were able to scanned all patients with prospective ECG -gating.

Direct visualization of the in-stent lumen is necessary to assess stent patency, that is because the vessel segment distal to the occluded stent may be opacified by collateral vessels in a retrograde flow direction [12].

We used qualitative visual interpretation to determine in-stent restenosis in our study, a sit is preferable and more precise than quantitative assessment because quantitative estimations of CT numbers of the stent lumen may yield conflicting results because the measured CT number in the stent lumen is affected by the stent material as well as stent diameter and strut thickness. Hence, qualitative assessment seems to be more feasible approach [12].

In a study done by Rist *et al.* [13] twenty-five patients with 46 coronary stents were examined by 64-slice CT and coronary angiography. Stent occlusion or in-stent restenosis was detected on coronary angiography in 8 stents (occlusion in 2 stents & 50% stenosis in 6 stents). The both 2 occluded stents were correctly identified with CT and 2 out of the 6 stents with stenosis were falsely diagnosed as patent with CT. The diameters of the 2 falsely diagnosed patent stents were 2.5 and 3.0 mm. These results demonstrated that non-occlusive in-stent restenoses might be not diagnosed in some cases, particularly in stents with a smaller diameter, even with the utilization of 64- slice CT.

Oncel *et al.* [8], had examined 30 patients with 39 coronary stents using 64-slice CT, they used conventional angiography as the gold standard. At conventional angiography 9 stents were appeared to be completely occluded; all of these occluded stents were accurately diagnosed with CT, 20 stents were patent; 19 out of these 20 patent stents were correctly identified with CT and 10 stents had in-stent restenosis; eight out of these 10 stents were correctly diagnosed with CT. The sensitivity, specificity, positive predictive value and negative predictive value were 89%, 95%, 94% and 90%, respectively.

In our study we evaluated 30 stents in 22 patients with 128 slice CT scanner and conventional angiography. At conventional angiography 3 of the 30 stents were shown to be totally occluded, 3 stents had in-stent restenosis and 24 stents were patent. All of the 3 occluded stents and 3 in stent restenosis were correctly diagnosed with CT, while 20 of 24 patent stents were correctly demonstrated with CT. One of the 24 true patent stents in conventional angiography were misdiagnosed in CT as occluded stent and 3 stents of these 24 patent stents were misdiagnosed in CT as in stent restenosis. The diameters of these misdiagnosed stents were  $\geq 3$  mm in one stent and <3 mm in the other 3 stents. The overall sensitivity,

specificity, PPV, NPV and accuracy of CT were 100%, 83.3%, 60%, 100% and 86.7 % respectively for assessable stents.

Our results was slightly close to the that found by YUE *et al.* [14], they reported 100% sensitivity, 93.94% specificity, 77.78% PPV, 100% NPV and 95% accuracy of 64-MSCT in the detection of significant in stent restenosis in all assessable stents.

The 100% NPV indicates that patient with a negative CT result 100 % truly doesn't has stent occlusion or re stenosis, it means that CT is a good negative test for exclusion of stent occlusion or restenosis.

The diagnosis of stent restenosis depends on stent diameter. In stents with small diameter ( $\leq 3$  mm), sensitivity and specificity of MDCT were 54% and 100% respectively, while for stents with larger diameter ( $> 3$  mm), sensitivity and specificity of MDCT were 86% and 100%, respectively [12].

In our study we didn't calculate the sensitivity and specificity for different stent diameter.

In that study we found that the incidence of stent restenosis/occlusion in bare metal stents (4 stents 13.3%) was higher than that in drug eluting stents (2 stents 6.7%), that was in keeping with several studies [15 -17] which reported that the clinical incidence of restenosis after coronary stent is higher for bare metal stents (20–35%) than for drug-eluting stents (5–10%).

Lee *et al.* [18] stated that the time frame for restenosis after drug eluting stent (DES) may be longer than that after bare-metal stent (BMS) that is based on the fact that antiproliferative drugs can delay the biologic response to injury. They found that the mean time for instent restenosis (ISR) detection was approximately 12 months after DES stent insertion. In the BMS, ISR has been reported to occur within an average of 5.5 months after stent implantation [19].

That was in agreement with our results as we found that the mean time of stent occlusion/restenosis in DES ( 18 months) was longer than that for BMS ( $9 \pm 0.77$  months) with a statistically significant difference ( $p$  value 0.01).

The 128 MDCT is an appropriate non invasive method for assessment of coronary stent patency and it is a good negative test for exclusion of stent occlusion or restenosis.

The present study has certain limitations: first, the number of the examined stents was small, and second is the heterogeneous group of stents as regards diameter, strut thickness and stent type (drug eluting and bare metal stent).

## References

1. Pugliese F, Cademartiri F, Van Mieghem C, *et al.* Multidetector CT for visualization of

- coronary stents. *Radiographics* 2006; 32(3): 887–904.
2. Jung JI. Multidetector CT Imaging of Coronary Artery Stents: Is This Method Ready for Use? *Korean Circ J* 2007; 37:521-529.
3. Moses J W, Leon M.B, Popma J.J. Sirolimus-Eluting Stents versus Standard Stents in Patients with Stenosis in a Native Coronary Artery. *The New England Journal of Medicine* 2003; vol. 349(14):1315-1323.
4. Mahnken AH. CT Imaging of Coronary Stents: Past, Present, and Future. *ISRN Cardiol.* 2012;2012:139823. Epub 2012 Sep 11.
5. Krüger S, Mahnken AH, Sinha AM, Borghans A, Dedden K, Hoffmann R, Hanrath P. Multislice spiral computed tomography for the detection of coronary stent restenosis and patency. *International Journal of Cardiology.* 2003 Jun 30; 89(2): 167-72.
6. Kitagawa T, Fuji T, Tomohiro Y, *et al.* Noninvasive assessment of coronary stents in patients by 16-slice computed tomography. *Int J Cardiol* 2006;109:188–194.
7. Gilard M, Cornily JC, Pennec PY, *et al.* Assessment of coronary artery stents by 16- slice computed tomography. *Heart* 2006; 92(1):58–61.
8. Oncel D, Oncel G and Karaca M. Coronary Stent Patency and In-Stent Restenosis: Determination with 64-Section Multidetector CT Coronary Angiography—Initial Experience. *Radiology:* 2007 (242) 2;403:409.
9. Wolf F, Leschka S, Loewe C, Homolka P, *et al.* Coronary artery stent imaging with 128-slice dual-source CT using high-pitch spiral acquisition in a cardiac phantom: comparison with the sequential and low-pitch spiral mode. *Eur Radiol.* 2010 Sep;20(9):2084-2091.
10. Khan R, Rawal S and Eisenberg MJ. Transitioning from 16-slice to 64-slice multidetector computed tomography for the assessment of coronary artery disease: Are we really making progress. *Can J Cardiol.* 2009 Sep; 25(9):533-42.
11. Pelberg R. Basic principles in Computed Tomography (CT). *Cardiac CT angiography manual* 2015. London: Springer.
12. Song B G: Multidetector CT Imaging of Coronary Artery Stent and Coronary Artery Bypass Graft. *Cardiology and Cardiovascular Medicine» "What Should We Know About Prevented, Diagnostic, and Interventional Therapy in Coronary Artery Disease"*, Chapter 8. Edited by Branislav G. Baskot, ISBN 978-953-51-1043-9, Published: March 20, 2013. DOI: 10.5772/54085.
13. Rist C, Ziegler F V, Nikolaou k, *et al.* Assessment of coronary artery stent patency and restenosis using 64-Slice Computed Tomography. *Acad Radiol* 2006; 13:1465–1473.
14. Y J, Chen J, Dou W, *et al.*: Comparative analysis between 64- and 320-slice spiral computed tomography in the display of coronary artery stents and diagnosis of in-stent restenosis. *Exp Ther Med.* 2015 Nov; 10(5): 1871–1876.
15. Holmes DR Jr, Leon MB, Moses JW, *et al.* Analysis of 1-year clinical outcomes in the SIRIUS trial: a randomized trial of a sirolimus-eluting stent versus a standard stent in patients at high risk for coronary restenosis. *Circulation* 2004;109:634–640.
16. Windecker S, Remondino A, Eberli FR, *et al.* Sirolimus-eluting and paclitaxel-eluting stents for coronary revascularization. *N Engl J Med* 2005;353:653–662.
17. Morice MC, Colombo A, Meier B, *et al.* Reality trial Investigators. Sirolimus- vs. paclitaxel-eluting stents in de novo coronary artery lesions: the reality trial: a randomized controlled trial. *JAMA* 2006;295:895–904.
18. Lee M.S., Pessegueiro A., Zimmer R., *et al.* Clinical presentation of patients with in-stent restenosis in the drug-eluting stent era. *J Invasive Cardiol.* 20. 2008:401-403.PubMed.
19. Nayak A.K., Kawamura A., Nesto R.W. Myocardial infarction as a presentation of clinical in-stent restenosis. *Circ J.* 70. 2006:1026-1029.